

Differentiating Iophendylate residues from other spinal pathologies on imaging

Author: BenchChem Technical Support Team. **Date:** December 2025

Compound of Interest

Compound Name: *Iophendylate*

Cat. No.: *B1672084*

[Get Quote](#)

Technical Support Center: Imaging of Iophendylate Residues

This technical support center provides troubleshooting guides and frequently asked questions (FAQs) for researchers, scientists, and drug development professionals involved in spinal imaging. The following information addresses the differentiation of **iophendylate** (formerly marketed as Pantopaque® or Myodil®) residues from other spinal pathologies.

Frequently Asked Questions (FAQs)

Q1: What is **iophendylate** and why is it a concern in spinal imaging?

A1: **iophendylate** is an oil-based contrast medium that was widely used for myelography from the 1940s until the late 1980s.[1][2] Due to its oily, lipophilic nature, it was often incompletely removed after the procedure and can persist in the subarachnoid space for decades.[1][3] These residues can elicit a chronic inflammatory response, leading to a condition known as adhesive arachnoiditis, which can be painful and debilitating.[3] On imaging, these residues can mimic other spinal pathologies, including tumors, creating diagnostic challenges.

Q2: What are the typical imaging characteristics of **iophendylate** residues on CT scans?

A2: Due to its iodine content, **iophendylate** is hyperdense on computed tomography (CT) scans, meaning it appears bright. The residues often present as multiple, well-defined, high-

attenuation droplets or linear collections within the spinal canal. The high density of **iophendylate** results in high Hounsfield Unit (HU) values, significantly greater than surrounding soft tissues and cerebrospinal fluid (CSF).

Q3: How do **iophendylate** residues appear on Magnetic Resonance Imaging (MRI)?

A3: The MRI appearance of **iophendylate** is characteristic and relates to its oily composition. It typically demonstrates:

- T1-weighted images: High signal intensity (hyperintense), similar to fat.
- T2-weighted images: Variable signal intensity, but often low (hypointense).
- Fat-suppressed T1-weighted images: **iophendylate** remains hyperintense, unlike fat which would be suppressed (appear dark). This is a key feature in differentiating it from fatty lesions like lipomas.

Q4: What is **iophendylate**-induced arachnoiditis and what are its imaging features?

A4: **iophendylate**-induced arachnoiditis is a chronic inflammation of the arachnoid mater, one of the membranes surrounding the spinal cord, caused by the irritant effect of residual contrast material. The pathological process involves a fibrovascular proliferation of the leptomeninges with granuloma formation.

The imaging findings of arachnoiditis can be varied and are best visualized on MRI. Common features include:

- Nerve root clumping: The nerve roots of the cauda equina adhere to each other, forming a single soft tissue mass in the center of the thecal sac.
- "Empty thecal sac" sign: Nerve roots adhere to the periphery of the thecal sac, leaving the central portion appearing empty.
- Soft tissue mass: A collection of inflammatory tissue can obliterate the subarachnoid space.
- Arachnoid septations and CSF loculations: The formation of scar tissue can create compartments within the subarachnoid space, trapping CSF.

- Syring formation: Altered CSF dynamics due to adhesions can lead to the development of a fluid-filled cavity (syrinx) within the spinal cord.

Q5: Which spinal pathologies can mimic **iophendylate** residues on imaging?

A5: The primary differential diagnoses for **iophendylate** residues on MRI, particularly due to their T1 hyperintensity, include:

- Spinal Lipoma: A benign tumor composed of fat cells. Differentiation is crucial and is achieved with fat-suppression sequences, where lipomas will lose signal and **iophendylate** will not.
- Hemorrhage (Methemoglobin): Subacute hemorrhage can appear hyperintense on T1-weighted images. Clinical history and other imaging sequences can help in differentiation.
- Melanoma Metastases: These tumors can have high T1 signal due to the paramagnetic properties of melanin.
- Dermoid or Epidermoid Cysts: Ruptured cysts can release fatty contents that appear as hyperintense droplets on T1-weighted images.

Arachnoiditis induced by **iophendylate** can mimic an intramedullary spinal cord tumor on MRI.

Troubleshooting Guides

Problem: A spinal lesion appears hyperintense on T1-weighted MRI, and it is unclear if it is an **iophendylate** residue or a lipoma.

Solution:

- Review Fat-Suppressed Sequences: This is the most critical step. **iophendylate** will remain hyperintense on T1-weighted images with fat suppression, while a lipoma will show a marked decrease in signal intensity.
- Check Patient History: A history of myelography, particularly before the 1990s, is highly suggestive of **iophendylate** residues.

- Correlate with CT: If available, a non-contrast CT scan will show the characteristic hyperdensity of **iophendylate**.

Problem: Imaging findings are suggestive of arachnoiditis, but the cause is unknown.

Solution:

- Careful History Taking: Inquire about previous spinal procedures, including myelography, spinal surgery, spinal anesthesia, trauma, or infections, as these are all potential causes of arachnoiditis.
- Look for **iophendylate** Droplets: Scrutinize all imaging sequences, particularly T1-weighted MRI and CT, for the tell-tale droplets of **iophendylate**, which would confirm the etiology.
- Consider Other Causes: If no history of **iophendylate** exposure is present, other causes such as infection (e.g., tuberculosis), inflammatory conditions, or prior subarachnoid hemorrhage should be investigated.

Data Presentation

Table 1: Imaging Characteristics of **iophendylate** Residues vs. Differential Diagnoses

Pathology	CT Appearance (HU)	T1-Weighted MRI	T2-Weighted MRI	T1-Weighted MRI with Fat Suppression
Iophendylate Residue	Hyperdense (High HU)	Hyperintense	Hypointense	Hyperintense
Spinal Lipoma	Hypodense (-50 to -100 HU)	Hyperintense	Isointense to Hyperintense	Hypointense (Signal loss)
Subacute Hemorrhage	Hyperdense (50-100 HU)	Hyperintense	Hyperintense	Hyperintense
Melanoma Metastasis	Variable	Hyperintense	Variable	Hyperintense
Arachnoiditis	Normal or soft tissue density	Isointense to CSF	Variable, can be hyperintense	No specific change

Table 2: Typical MRI Signal Intensities of Spinal Tissues

Tissue	T1-Weighted Signal	T2-Weighted Signal
Cerebrospinal Fluid (CSF)	Low	High
Spinal Cord	Intermediate	Intermediate
Fat (in bone marrow)	High	Intermediate to High
Muscle	Intermediate	Low
Intervertebral Disc	Intermediate	High (nucleus), Low (annulus)
Cortical Bone	Low	Low

Experimental Protocols

Standard MRI Protocol for Suspected Spinal Pathology

This protocol is designed to provide a comprehensive evaluation of the spinal cord, nerve roots, and surrounding structures.

- Patient Positioning: Supine, with the spine centered in the coil.
- Sequences:
 - Sagittal T1-weighted spin-echo: Provides excellent anatomical detail of the vertebral bodies and spinal cord.
 - Sagittal T2-weighted fast spin-echo: Sensitive for detecting edema and other fluid-related abnormalities within the spinal cord and discs.
 - Sagittal STIR (Short Tau Inversion Recovery): A fat-suppression technique that is very sensitive to fluid and edema in the bone marrow and soft tissues.
 - Axial T1-weighted spin-echo: Provides detailed anatomy of the spinal canal, intervertebral foramina, and nerve roots at specific levels.
 - Axial T2-weighted fast spin-echo: Complements the axial T1, providing better visualization of the thecal sac and nerve roots.
 - Post-contrast T1-weighted spin-echo with fat suppression (if indicated): Performed after intravenous administration of a gadolinium-based contrast agent to evaluate for enhancement in tumors, infections, or areas of inflammation. This is crucial for differentiating **iophendylate** from enhancing pathologies.

Standard CT Myelography Protocol

CT myelography is typically reserved for cases where MRI is contraindicated.

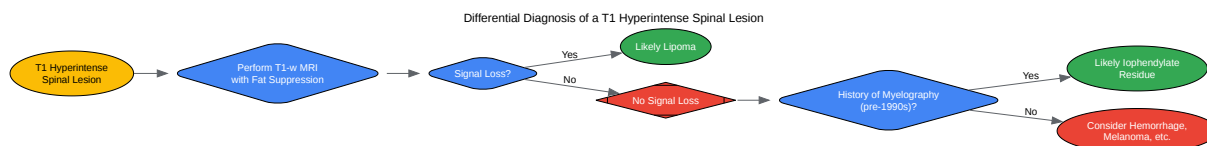
- Contrast Injection: A non-ionic, water-soluble iodinated contrast agent is injected into the thecal sac via a lumbar puncture under fluoroscopic guidance.
- Patient Positioning: The patient is positioned to allow the contrast to flow to the region of interest (e.g., Trendelenburg for cervical spine).
- CT Acquisition: Helical CT images are acquired through the area of interest.
- Reconstructions: Multiplanar reformations (sagittal and coronal) are generated from the axial dataset to provide a comprehensive view of the spinal canal and nerve roots.

Mandatory Visualization

Chemical Structure of Iophendylate

[Click to download full resolution via product page](#)

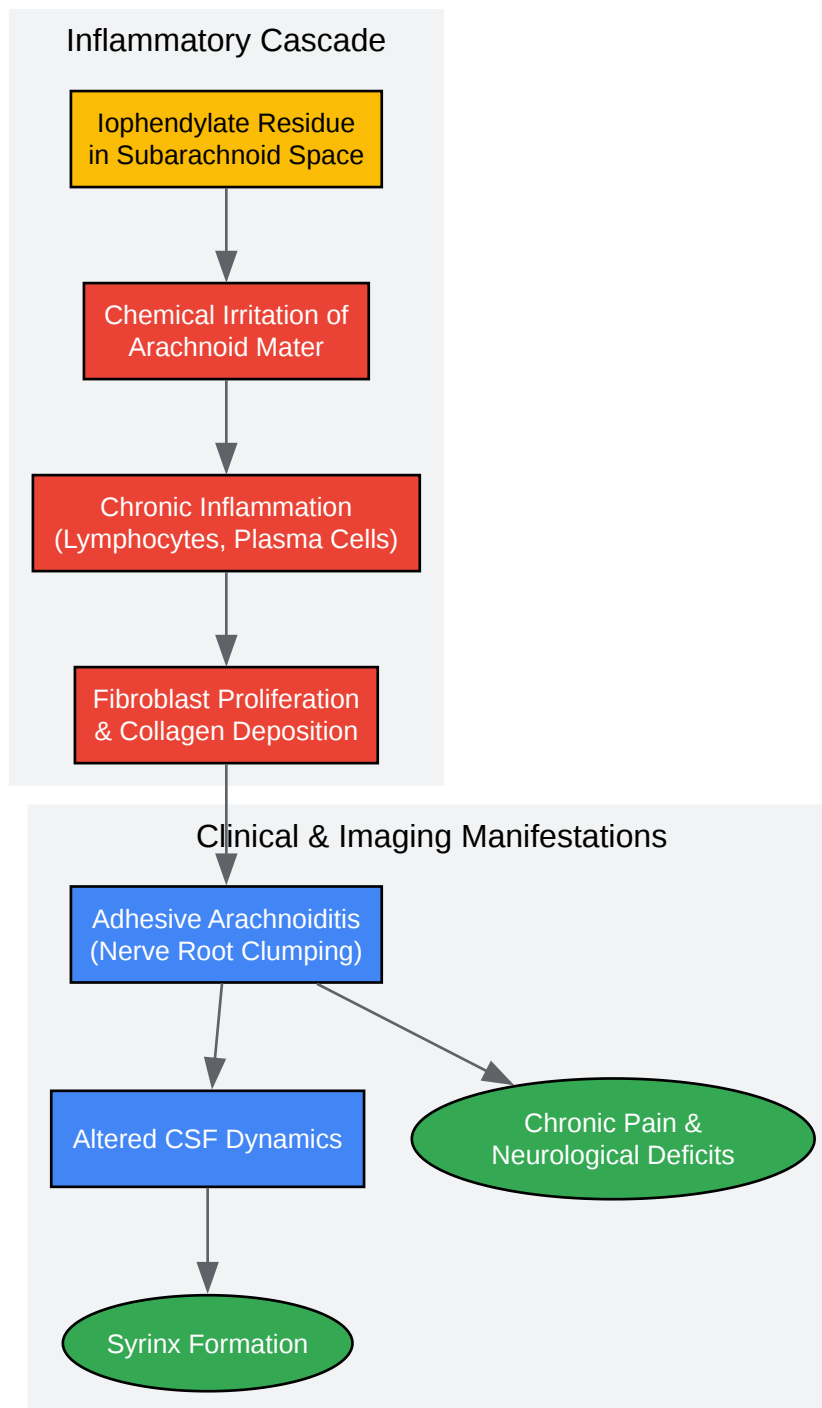
Caption: Chemical structure of **Iophendylate**.



[Click to download full resolution via product page](#)

Caption: Workflow for differentiating T1 hyperintense spinal lesions.

Pathogenesis of Iophendylate-Induced Arachnoiditis

[Click to download full resolution via product page](#)Caption: Pathogenesis of **iophendylate**-induced arachnoiditis.

Need Custom Synthesis?

BenchChem offers custom synthesis for rare earth carbides and specific isotopic labeling.

Email: info@benchchem.com or [Request Quote Online](#).

References

- 1. radiopaedia.org [radiopaedia.org]
- 2. Thoracic spinal iophendylate-induced arachnoiditis mimicking an intramedullary spinal cord neoplasm. Case report - PubMed [pubmed.ncbi.nlm.nih.gov]
- 3. Iophendylate-induced basal arachnoiditis - PubMed [pubmed.ncbi.nlm.nih.gov]
- To cite this document: BenchChem. [Differentiating Iophendylate residues from other spinal pathologies on imaging]. BenchChem, [2025]. [Online PDF]. Available at: [https://www.benchchem.com/product/b1672084#differentiating-iophendylate-residues-from-other-spinal-pathologies-on-imaging]

Disclaimer & Data Validity:

The information provided in this document is for Research Use Only (RUO) and is strictly not intended for diagnostic or therapeutic procedures. While BenchChem strives to provide accurate protocols, we make no warranties, express or implied, regarding the fitness of this product for every specific experimental setup.

Technical Support: The protocols provided are for reference purposes. Unsure if this reagent suits your experiment? [[Contact our Ph.D. Support Team for a compatibility check](#)]

Need Industrial/Bulk Grade? [Request Custom Synthesis Quote](#)

BenchChem

Our mission is to be the trusted global source of essential and advanced chemicals, empowering scientists and researchers to drive progress in science and industry.

Contact

Address: 3281 E Guasti Rd

Ontario, CA 91761, United States

Phone: (601) 213-4426

Email: info@benchchem.com