

Differentiating BK virus nephropathy and acute cellular rejection with staining

Author: BenchChem Technical Support Team. **Date:** December 2025

Compound of Interest

Compound Name: Lithol Rubine BK

Cat. No.: B12516396

[Get Quote](#)

A definitive diagnosis of BK virus nephropathy (BKVN) and its differentiation from acute cellular rejection (ACR) is a critical challenge in the management of renal transplant recipients. Both conditions can present with similar clinical signs of allograft dysfunction and histological features of tubulointerstitial inflammation, making an accurate diagnosis essential for appropriate therapeutic intervention.[1][2] This guide provides a comprehensive comparison of the staining techniques used to distinguish BKVN from ACR, supported by experimental data and detailed protocols for researchers, scientists, and drug development professionals.

Histological and Immunohistochemical Staining

Hematoxylin and Eosin (H&E) Staining

H&E staining is the foundational method for assessing renal biopsy specimens. While not definitive on its own for diagnosing BKVN, it reveals characteristic cytopathic changes that are highly suggestive of the infection.

- **BK Virus Nephropathy (BKVN):** The hallmark of BKVN on H&E staining is the presence of viral cytopathic effects in the tubular epithelial cells.[1] This includes nuclear enlargement and intranuclear "ground-glass" or vesicular inclusions.[3][4] These infected cells can detach from the tubular basement membrane and form intratubular casts.[5] The inflammatory infiltrate in BKVN is typically composed of lymphocytes, plasma cells, and neutrophils.
- **Acute Cellular Rejection (ACR):** ACR is characterized by tubulointerstitial inflammation, including tubulitis (infiltration of tubules by lymphocytes) and interstitial edema.[6] In contrast

to BKVN, viral cytopathic changes are absent. Severe ACR may also show endarteritis or fibrinoid necrosis of arteries, which are not features of BKVN.[7]

Simian Virus 40 Large T-Antigen (SV40-T)

Immunohistochemistry

Immunohistochemistry (IHC) for the SV40 large T-antigen is the gold standard for the definitive diagnosis of BKVN.[3][8] The antibody used is cross-reactive with the BK virus T-antigen.

- BK Virus Nephropathy (BKVN): A positive SV40-T stain shows strong nuclear positivity in the renal tubular epithelial cells, confirming the presence of the virus.[1][4] The staining can be focal, so a negative result in a small biopsy sample does not entirely rule out BKVN, especially in early stages.[9]
- Acute Cellular Rejection (ACR): Biopsies with ACR are negative for SV40-T staining.[1]

C4d Staining

C4d is a component of the complement system, and its deposition in peritubular capillaries is a key marker for antibody-mediated rejection (AMR).[10] While not a direct differentiator of BKVN and ACR, it is crucial for identifying concurrent AMR.

- BK Virus Nephropathy (BKVN): Peritubular capillary C4d staining is generally not a feature of BKVN.[10][11] However, some studies have reported diffuse C4d staining in the tubular basement membranes in a subset of BKVN cases, which may correlate with a more severe viral cytopathic effect.[10][11]
- Acute Cellular Rejection (ACR): C4d staining in peritubular capillaries is typically negative in pure ACR. Its presence suggests a component of AMR.[7]

Immunophenotyping of Inflammatory Infiltrates

Characterizing the immune cell populations within the inflammatory infiltrate can provide additional clues to differentiate BKVN from ACR. However, there can be significant overlap in the findings.

Staining Marker	BK Virus Nephropathy (BKVN)	Acute Cellular Rejection (ACR)	Reference(s)
CD3	T-lymphocyte infiltrate present	T-lymphocyte infiltrate present	[1][12]
CD4	Fewer infiltrating cells compared to ACR	Higher number of infiltrating cells	[1]
CD8	Fewer infiltrating cells compared to ACR	Higher number of infiltrating cells	[1]
CD20	Increased number of B-lymphocytes, sometimes in clusters	Fewer B-lymphocytes compared to BKVN	[1][13]
Perforin	Fewer cytotoxic T-cells	Rich in perforin-positive cells	[13][14]
Granzyme B	No significant difference compared to ACR	No significant difference compared to BKVN	[13]
Foxp3	Wider range of staining, may have high levels	Lower levels of staining	[12]

Experimental Protocols

Immunohistochemistry for SV40-T Antigen

- **Deparaffinization and Rehydration:** Formalin-fixed, paraffin-embedded renal biopsy sections (4 µm) are deparaffinized in xylene and rehydrated through a graded series of ethanol (100%, 95%, 70%) to water.
- **Antigen Retrieval:** Heat-induced epitope retrieval is performed by immersing the slides in a citrate buffer (pH 6.0) and heating in a microwave or pressure cooker.

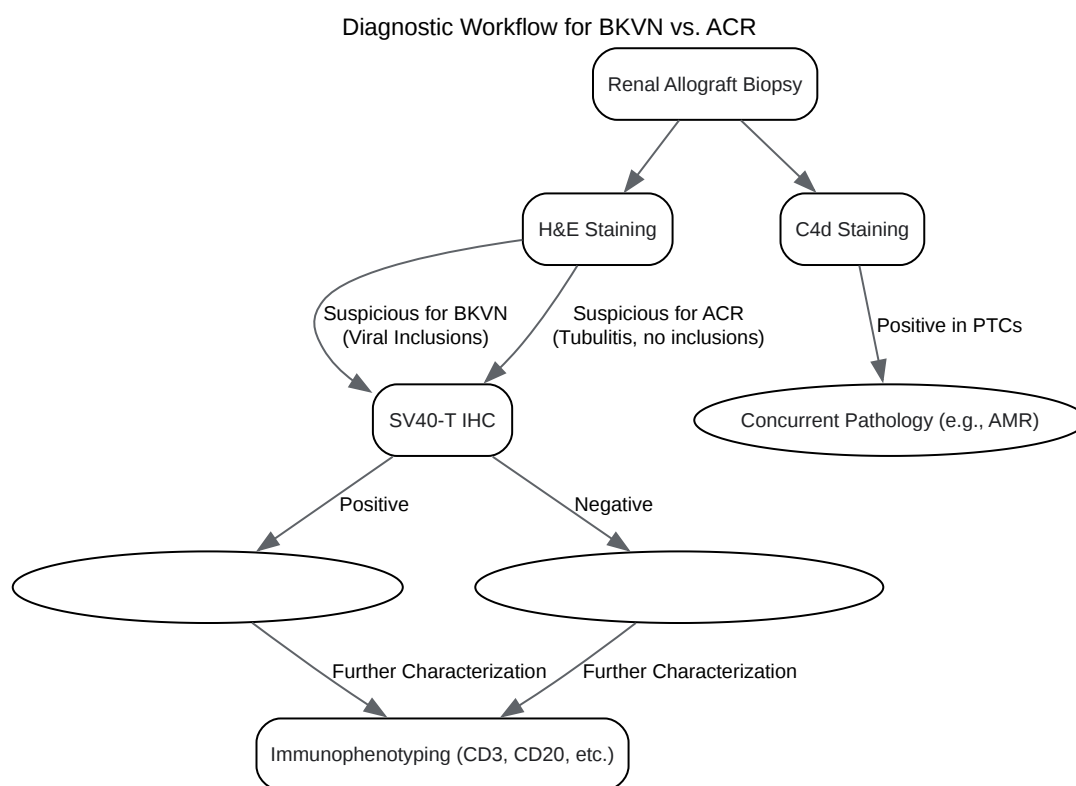
- **Blocking:** Endogenous peroxidase activity is blocked with a 3% hydrogen peroxide solution. Non-specific antibody binding is blocked using a protein block solution.
- **Primary Antibody Incubation:** The sections are incubated with a primary antibody against SV40 large T-antigen (e.g., clone pAb416) at an appropriate dilution overnight at 4°C.
- **Secondary Antibody and Detection:** A horseradish peroxidase (HRP)-conjugated secondary antibody is applied, followed by a diaminobenzidine (DAB) substrate-chromogen system, which produces a brown precipitate at the site of the antigen.
- **Counterstaining, Dehydration, and Mounting:** The sections are counterstained with hematoxylin, dehydrated through graded ethanol and xylene, and mounted with a permanent mounting medium.

C4d Staining (Immunofluorescence)

- **Section Preparation:** Frozen renal biopsy sections (4 µm) are air-dried and fixed in acetone.
- **Blocking:** Non-specific binding is blocked with a solution containing bovine serum albumin.
- **Primary Antibody Incubation:** The sections are incubated with a monoclonal antibody against C4d (e.g., clone 10-11) for 1 hour at room temperature.
- **Secondary Antibody Incubation:** After washing, a fluorescein isothiocyanate (FITC)-conjugated secondary antibody is applied for 30 minutes in the dark.
- **Mounting and Visualization:** The slides are mounted with an anti-fading mounting medium and visualized using a fluorescence microscope. Positive staining appears as a bright linear pattern along the peritubular capillaries.

Visualizing the Diagnostic Workflow

The following diagrams illustrate the key steps and logical relationships in the differentiation of BKVN and ACR.



[Click to download full resolution via product page](#)

Caption: A flowchart illustrating the diagnostic pathway for differentiating BKVN and ACR.

Key Histological and IHC Distinctions

BK Virus Nephropathy
H&E: Viral Inclusions SV40-T: Positive C4d (PTC): Negative Infiltrate: Plasma cells, Neutrophils

Acute Cellular Rejection
H&E: Tubulitis, No Inclusions SV40-T: Negative C4d (PTC): Negative Infiltrate: Lymphocytes

[Click to download full resolution via product page](#)

Caption: A diagram summarizing the key staining differences between BKNV and ACR.

In conclusion, a multi-faceted approach utilizing H&E staining, definitive SV40-T immunohistochemistry, C4d staining to rule out concurrent antibody-mediated rejection, and immunophenotyping of the inflammatory infiltrate is essential for the accurate differentiation of BK virus nephropathy and acute cellular rejection. This comprehensive evaluation ensures appropriate patient management and improved allograft outcomes.

Need Custom Synthesis?

BenchChem offers custom synthesis for rare earth carbides and specific isotopic labeling.

Email: info@benchchem.com or [Request Quote Online](#).

References

- 1. Immunophenotyping in BK Virus Allograft Nephropathy Distinct from Acute Rejection - PMC [pmc.ncbi.nlm.nih.gov]

- 2. Immunohistochemical features of BK virus nephropathy in renal transplant recipients - PubMed [pubmed.ncbi.nlm.nih.gov]
- 3. academic.oup.com [academic.oup.com]
- 4. Polyomavirus nephropathy: diagnosis, histologic features, and differentiation from acute rejection [ctrjournal.org]
- 5. karger.com [karger.com]
- 6. Polyomavirus nephropathy: diagnosis, histologic features, and differentiation from acute rejection - PMC [pmc.ncbi.nlm.nih.gov]
- 7. BK Virus Nephropathy in Kidney Transplantation: A State-of-the-Art Review - PMC [pmc.ncbi.nlm.nih.gov]
- 8. Kidney Biopsy of the Month: BK virus nephropathy - Renal Fellow Network [renalfellow.org]
- 9. Routine immunohistochemistry study for polyomavirus BK nephropathy in transplanted kidney biopsies, is it recommended? - PMC [pmc.ncbi.nlm.nih.gov]
- 10. The significance of renal C4d staining in patients with BK viremia, viremia, and nephropathy - PubMed [pubmed.ncbi.nlm.nih.gov]
- 11. Final Diagnosis -- Case 582 [path.upmc.edu]
- 12. Foxp3 staining in BK virus allograft nephropathy and comparison with acute cellular rejection - PubMed [pubmed.ncbi.nlm.nih.gov]
- 13. Immunophenotyping of interstitial infiltrate does not distinguish between BK virus nephropathy and acute cellular rejection - PubMed [pubmed.ncbi.nlm.nih.gov]
- 14. researchgate.net [researchgate.net]
- To cite this document: BenchChem. [Differentiating BK virus nephropathy and acute cellular rejection with staining]. BenchChem, [2025]. [Online PDF]. Available at: [https://www.benchchem.com/product/b12516396#differentiating-bk-virus-nephropathy-and-acute-cellular-rejection-with-staining]

Disclaimer & Data Validity:

The information provided in this document is for Research Use Only (RUO) and is strictly not intended for diagnostic or therapeutic procedures. While BenchChem strives to provide accurate protocols, we make no warranties, express or implied, regarding the fitness of this product for every specific experimental setup.

Technical Support: The protocols provided are for reference purposes. Unsure if this reagent suits your experiment? [[Contact our Ph.D. Support Team for a compatibility check](#)]

Need Industrial/Bulk Grade? [Request Custom Synthesis Quote](#)

BenchChem

Our mission is to be the trusted global source of essential and advanced chemicals, empowering scientists and researchers to drive progress in science and industry.

Contact

Address: 3281 E Guasti Rd
Ontario, CA 91761, United States
Phone: (601) 213-4426
Email: info@benchchem.com