

Detecting Small Liver Metastases: A Comparative Guide to DHOG and Alternative Imaging Modalities

Author: BenchChem Technical Support Team. **Date:** December 2025

Compound of Interest

Compound Name: DHOG

Cat. No.: B041213

[Get Quote](#)

The accurate detection of small liver metastases is a critical factor in the prognosis and therapeutic management of cancer patients. Dynamic Helical CT with Arterial Portography (**DHOG**), also known as CT during arterial portography (CTAP), has historically been a highly sensitive method for this purpose. This guide provides an objective comparison of **DHOG**'s performance against other imaging techniques, supported by available data, to assist researchers, scientists, and drug development professionals in understanding the current landscape of hepatic imaging.

Comparative Efficacy of Imaging Modalities

The choice of imaging modality for the detection of small liver metastases depends on a trade-off between sensitivity, specificity, invasiveness, and availability. While **DHOG** is renowned for its high sensitivity, particularly for lesions smaller than 10 mm, its specificity can be limited by perfusion defects that may mimic metastases. Newer, non-invasive techniques such as Magnetic Resonance Imaging (MRI) with liver-specific contrast agents and Positron Emission Tomography/MRI (PET/MRI) are now often favored for their high diagnostic accuracy.

Quantitative Performance Data

The following table summarizes the reported performance of various imaging modalities in detecting liver metastases, with a focus on smaller lesions where specified.

Imaging Modality	Overall Sensitivity	Sensitivity for Small Lesions (<10mm)	Overall Specificity	Key Advantages	Key Disadvantages
DHOG (CTAP)	81-94%	88%	69-82%	High sensitivity for small lesions.	Invasive, low specificity, potential for artifacts.
Helical CT	76%	Not specified	90%	Widely available, non-invasive.	Lower sensitivity than DHOG for small lesions.
MRI (Gadolinium-enhanced)	70-80.6%	Higher than CT for lesions <10mm.	88-94%	High soft-tissue contrast, non-ionizing radiation.	Variable sensitivity depending on contrast agent and sequence.
MRI (Ferumoxides-enhanced)	~86%	Significantly more sensitive than CT for lesions <10mm.	Not specified	High sensitivity for small lesions.	Not widely available.
MRAP (MR during Arterial Portography)	97%	95%	97%	Very high sensitivity and specificity.	Invasive.
PET/MRI	92.2%	Superior detection of PET-negative metastases.	Not specified	Combines metabolic and anatomical information.	High cost, limited availability.

Experimental Protocols

Detailed methodologies are crucial for the reproducibility and interpretation of imaging studies. Below are generalized protocols for the key imaging techniques discussed.

DHOG (CTAP) Protocol

- **Patient Preparation:** Patients are typically required to fast for 4-6 hours prior to the procedure. Informed consent is obtained due to the invasive nature of the technique.
- **Catheterization:** Using the Seldinger technique, a catheter is introduced into the femoral artery and advanced under fluoroscopic guidance into the superior mesenteric artery or splenic artery.
- **Contrast Administration:** A bolus of iodinated contrast material is injected through the catheter. The injection rate and volume are optimized to achieve dense opacification of the portal venous system.
- **Helical CT Imaging:** A helical CT scan of the liver is acquired during the portal venous phase of enhancement. This timing is critical to maximize the contrast between the enhanced liver parenchyma and typically hypovascular metastases.
- **Image Reconstruction and Analysis:** Thin-slice images are reconstructed to allow for multiplanar and 3D analysis, which aids in the precise localization of lesions relative to hepatic vascular structures.

Contrast-Enhanced MRI Protocol with Liver-Specific Agent

- **Patient Preparation:** Patients fast for 4-6 hours. A pre-procedural check for contraindications to MRI and contrast agents (e.g., metallic implants, renal insufficiency) is performed.
- **Baseline Imaging:** Unenhanced T1-weighted and T2-weighted sequences are acquired.
- **Contrast Administration:** A liver-specific contrast agent (e.g., gadoxetate disodium) is administered intravenously as a bolus.

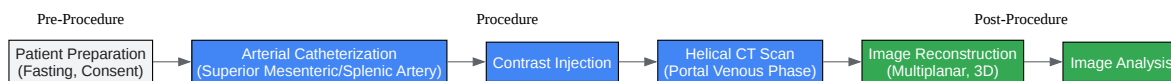
- **Dynamic Imaging:** Multi-phasic T1-weighted images are acquired during the arterial, portal venous, and transitional phases.
- **Hepatobiliary Phase Imaging:** Delayed images are acquired at approximately 20 minutes post-injection. In this phase, the contrast agent is taken up by healthy hepatocytes, leading to high signal intensity in normal liver parenchyma and making metastases, which do not contain hepatocytes, appear as hypointense lesions.
- **Image Analysis:** The combination of dynamic and hepatobiliary phase images allows for the detection and characterization of liver lesions.

PET/MRI Protocol

- **Patient Preparation:** Patients fast for at least 6 hours to ensure optimal metabolic conditions for FDG uptake. Blood glucose levels are checked prior to tracer injection. Patients are also screened for MRI contraindications.
- **Radiotracer Injection:** 18F-Fluorodeoxyglucose (FDG) is injected intravenously.
- **Uptake Period:** The patient rests for approximately 60 minutes to allow for the distribution and uptake of the FDG.
- **Image Acquisition:** The patient is positioned in the PET/MRI scanner. A whole-body scan is typically performed, followed by a dedicated, high-resolution scan of the liver. The MRI component includes T1-weighted, T2-weighted, and diffusion-weighted imaging (DWI) sequences acquired simultaneously with the PET data.
- **Image Fusion and Analysis:** The PET data (providing metabolic information) and MRI data (providing detailed anatomical information) are co-registered and fused for interpretation.

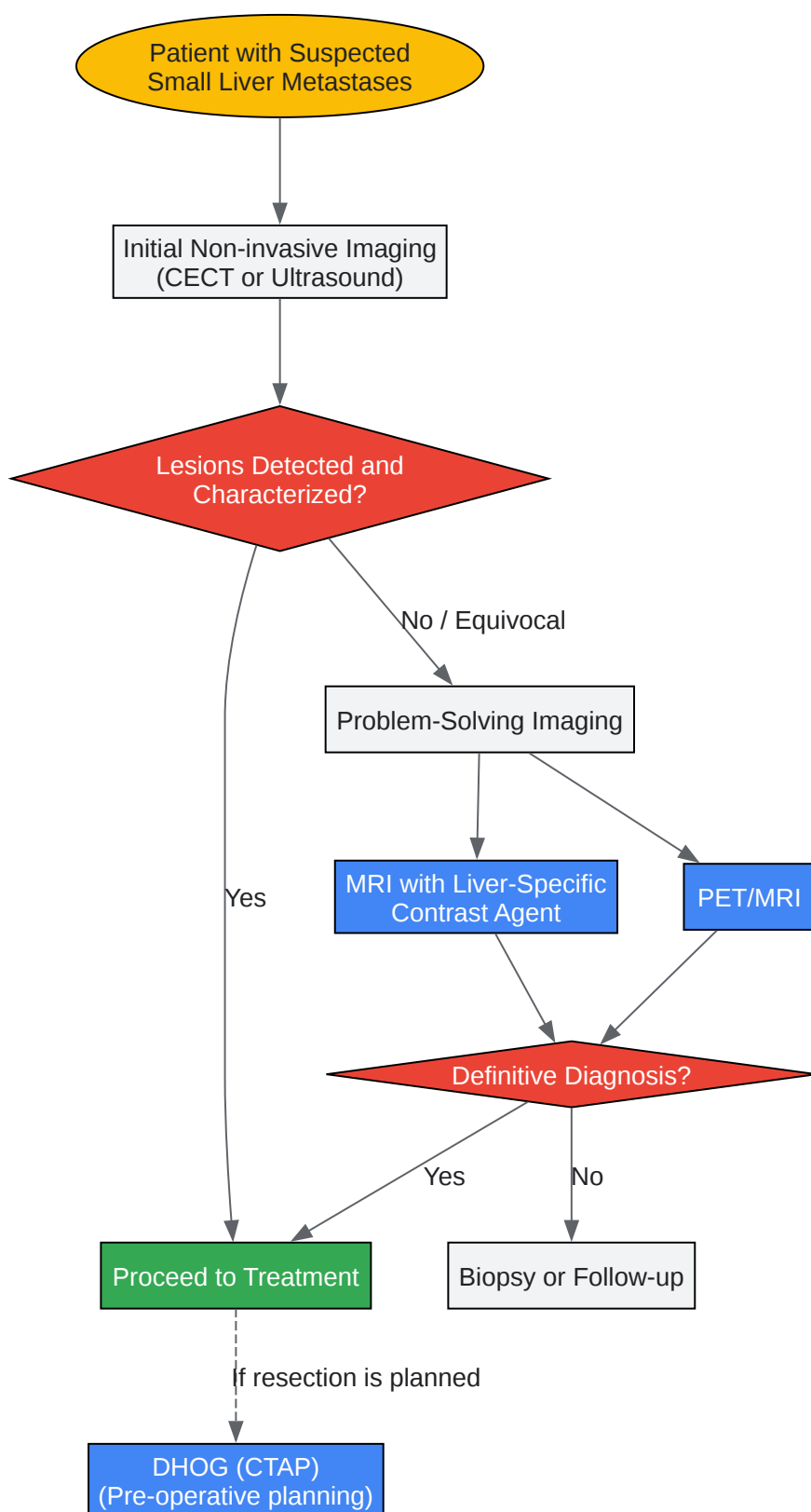
Visualizing the Diagnostic Workflow

The following diagrams illustrate the procedural flow of **DHOG/CTAP** and a typical clinical decision-making workflow for the diagnosis of small liver metastases.



[Click to download full resolution via product page](#)

DHOG (CTAP) Experimental Workflow.



[Click to download full resolution via product page](#)

Diagnostic Workflow for Small Liver Metastases.

- To cite this document: BenchChem. [Detecting Small Liver Metastases: A Comparative Guide to DHOG and Alternative Imaging Modalities]. BenchChem, [2025]. [Online PDF]. Available at: [<https://www.benchchem.com/product/b041213#efficacy-of-dhog-in-detecting-small-liver-metastases>]

Disclaimer & Data Validity:

The information provided in this document is for Research Use Only (RUO) and is strictly not intended for diagnostic or therapeutic procedures. While BenchChem strives to provide accurate protocols, we make no warranties, express or implied, regarding the fitness of this product for every specific experimental setup.

Technical Support: The protocols provided are for reference purposes. Unsure if this reagent suits your experiment? [[Contact our Ph.D. Support Team for a compatibility check](#)]

Need Industrial/Bulk Grade? [Request Custom Synthesis Quote](#)

BenchChem

Our mission is to be the trusted global source of essential and advanced chemicals, empowering scientists and researchers to drive progress in science and industry.

Contact

Address: 3281 E Guasti Rd
Ontario, CA 91761, United States
Phone: (601) 213-4426
Email: info@benchchem.com