

# Detecting Coronary Artery Disease: A Comparative Guide to Sestamibi SPECT

**Author:** BenchChem Technical Support Team. **Date:** December 2025

## Compound of Interest

Compound Name: *TECHNETIUM SESTAMIBI*

Cat. No.: *B1142544*

[Get Quote](#)

Single-Photon Emission Computed Tomography (SPECT) with Technetium-99m Sestamibi is a widely established non-invasive imaging modality for the diagnosis and risk stratification of coronary artery disease (CAD). This guide provides a comprehensive comparison of Sestamibi SPECT's performance against other imaging techniques, supported by experimental data, to assist researchers, scientists, and drug development professionals in their evaluation of cardiac imaging methods.

## Performance of Sestamibi SPECT in CAD Detection

Sestamibi SPECT demonstrates good overall diagnostic accuracy for the detection of CAD. Its sensitivity and specificity can vary depending on the patient population, the severity of the disease, and the specific imaging protocol employed.

Study/Modality	Patient Population	Stress Method	Sensitivity	Specificity	Accuracy	Reference
Sestamibi SPECT	139 patients with and without prior MI	Treadmill Exercise	91.0%	64.7%	-	[1]
132 patients with suspected CAD	Exercise	88.0%	95.0% (normalcy rate)	-	[2]	
75 patients >80 years old	Exercise or Pharmacologic	87% (≥50% stenosis)	83% (≥50% stenosis)	-		
95% (≥70% stenosis)	75% (≥70% stenosis)	[3]				
130 women with suspected CAD	Adenosine	91% (severe/extensive CAD)	70% (severe/extensive CAD)	-	[4]	
Sestamibi SPECT vs. Planar Imaging	78 patients with chronic ischemic heart disease	Dipyridamole/Low-level Exercise	82%	82%	-	[5]
Planar Imaging	78%	73%	-	[5]		

Sestamibi SPECT vs. Thallium- 201 SPECT (in women)	115 women	Treadmill or Dipyridamo le	80.4% (≥70% stenosis)	82.4% (≥70% stenosis)	-	[2]
Thallium- 201 SPECT	84.3% (≥70% stenosis)	58.8% (≥70% stenosis)	-	[2]		
Sestamibi SPECT vs. CT Angiograph y (CTA)	40 patients with suspected significant CAD	Pharmacol ogic	62.1%	81.8%	67.5%	[4]
CT Angiograph y	92.6%	84.6%	90.0%	[4]		
391 symptomati c patients	-	62.0%	-	69.0% (AUC)	[6]	
CT Angiograph y	92.0%	-	91.0% (AUC)	[6]		
Sestamibi SPECT vs. PET	Meta- analysis	-	83%	77%	-	[7]
PET	85%	86%	-	[7]		
Systematic Review	-	82%	76%	83%	[3]	
PET	91%	89%	89%	[3]		
208 symptomati	-	57%	94%	77%	[8][9][10]	

c patients  
(PACIFIC  
Trial)

PET	87%	84%	85%	<a href="#">[8]</a> <a href="#">[9]</a> <a href="#">[10]</a>
-----	-----	-----	-----	--

## Experimental Protocols

The diagnostic accuracy of Sestamibi SPECT is intrinsically linked to the specific protocol used. Key variations in methodology include the choice of stressor, the imaging timeline, and the use of adjunctive techniques like electrocardiogram (ECG) gating.

## Stress Induction

The goal of stress testing is to induce a mismatch in myocardial blood flow between coronary territories supplied by healthy and stenotic arteries. This is achieved through either physical exercise or pharmacological agents.

- **Exercise Stress:** The patient walks on a treadmill or cycles on a stationary bicycle with progressively increasing intensity. This is the preferred method as it provides physiological stress and additional prognostic information from the ECG and hemodynamic responses.
- **Pharmacological Stress:** For patients unable to exercise, vasodilators like adenosine or dipyridamole, or inotropic agents like dobutamine, are administered intravenously to mimic the effects of exercise on coronary blood flow.

## Imaging Protocols

Several imaging protocols for Sestamibi SPECT have been developed, each with its own advantages and disadvantages.[\[5\]](#)

- **One-Day Rest/Stress Protocol:** This is a common and convenient protocol where both rest and stress imaging are performed on the same day. The patient first undergoes a rest scan, followed by the stress test and a second scan.
- **Two-Day Protocol:** Rest and stress imaging are performed on separate days. This protocol can reduce the potential for residual radioactivity from the first injection to interfere with the second scan, potentially improving image quality.

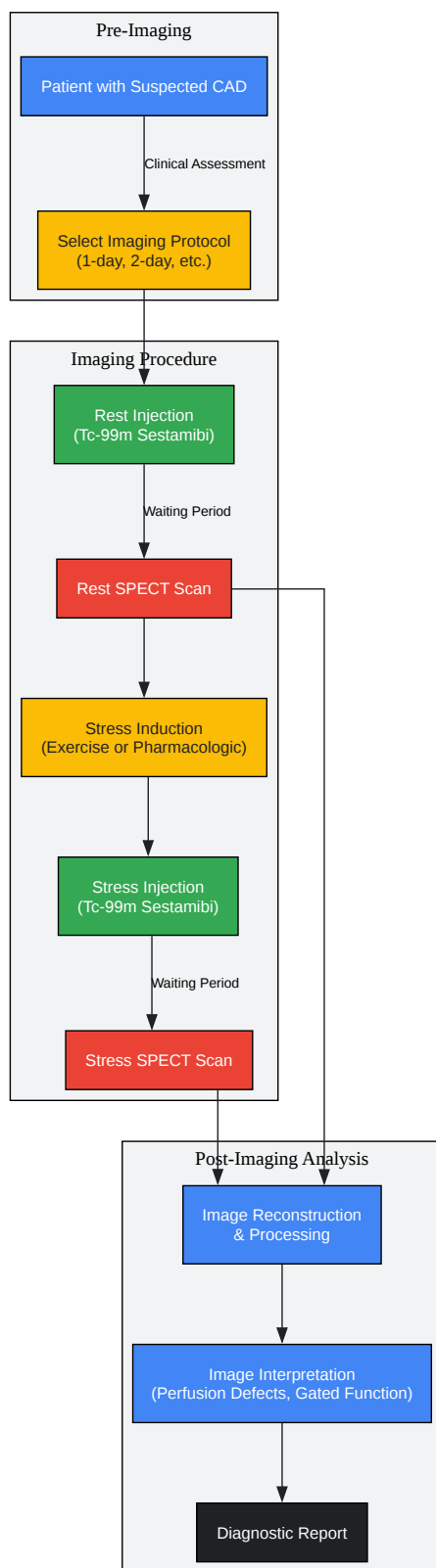
- **Dual-Isotope Protocol:** This approach often involves a rest scan with Thallium-201 followed by a stress scan with Sestamibi. This allows for near-simultaneous acquisition of rest and stress data.

## Gated SPECT

ECG gating involves acquiring SPECT data in synchronization with the patient's ECG. This technique allows for the assessment of myocardial wall motion, thickening, and overall left ventricular function, providing valuable information that can help differentiate true perfusion defects from artifacts and assess the functional consequences of ischemia.

## Sestamibi SPECT Workflow for CAD Detection

The following diagram illustrates the typical workflow for a patient undergoing Sestamibi SPECT for the evaluation of suspected coronary artery disease.



[Click to download full resolution via product page](#)

Workflow of Sestamibi SPECT for CAD Diagnosis.

## Comparison with Other Modalities

While Sestamibi SPECT is a robust tool, other imaging modalities offer different strengths in the assessment of CAD.

### Sestamibi SPECT vs. PET

Positron Emission Tomography (PET) is another nuclear imaging technique that generally offers higher spatial resolution and the ability to quantify myocardial blood flow. Multiple studies and meta-analyses have shown that PET has a higher diagnostic accuracy for CAD compared to SPECT.<sup>[3][7][11]</sup> The PACIFIC trial, a head-to-head comparison, found PET to have a significantly higher diagnostic accuracy (85%) than SPECT (77%).<sup>[8][9][10]</sup> However, SPECT remains more widely available and less expensive.

### Sestamibi SPECT vs. CT Angiography

Coronary CT Angiography (CTA) provides detailed anatomical information about the coronary arteries, allowing for the direct visualization of atherosclerotic plaques and stenoses. In contrast, Sestamibi SPECT assesses the functional consequence of these stenoses by measuring myocardial perfusion. Studies have shown that CTA has a higher sensitivity for detecting anatomically significant CAD, while SPECT can have higher specificity for identifying stenoses that cause ischemia.<sup>[4][6]</sup> Therefore, CTA is excellent at ruling out CAD, while SPECT is valuable for determining the physiological significance of known or suspected lesions.

## Conclusion

Sestamibi SPECT is a validated and valuable tool for the non-invasive detection of coronary artery disease. It provides crucial information on myocardial perfusion and function, guiding clinical decision-making. While newer modalities like PET may offer higher diagnostic accuracy and CTA provides superior anatomical detail, Sestamibi SPECT remains a cornerstone of cardiac imaging due to its wide availability, established prognostic value, and ability to assess the physiological impact of coronary stenoses. The choice of imaging modality should be guided by the specific clinical question, local expertise, and available resources.

#### *Need Custom Synthesis?*

*BenchChem offers custom synthesis for rare earth carbides and specific isotopic labeling.*

*Email: [info@benchchem.com](mailto:info@benchchem.com) or [Request Quote Online](#).*

## References

- 1. Myocardial perfusion imaging with technetium-99m sestamibi SPECT in the evaluation of coronary artery disease (Journal Article) | OSTI.GOV [osti.gov]
- 2. Exercise-rest same-day SPECT sestamibi imaging to detect coronary artery disease - PubMed [pubmed.ncbi.nlm.nih.gov]
- 3. Diagnostic value of SPECT, PET and PET/CT in the diagnosis of coronary artery disease: A systematic review - PMC [pmc.ncbi.nlm.nih.gov]
- 4. jnm.snmjournals.org [jnm.snmjournals.org]
- 5. researchgate.net [researchgate.net]
- 6. ACCURACY OF CT ANGIOGRAPHY AND SPECT MYOCARDIAL PERFUSION IMAGING FOR THE DIAGNOSIS OF CORONARY ARTERY DISEASE - PMC [pmc.ncbi.nlm.nih.gov]
- 7. Diagnostic Performance of CMR, SPECT, and PET Imaging for the Identification of Coronary Artery Disease: A Meta-Analysis - PMC [pmc.ncbi.nlm.nih.gov]
- 8. PET More Accurate for Diagnosing CAD Than SPECT and CT Angiography: PACIFIC Study | tctmd.com [tctmd.com]
- 9. PACIFIC: First Head-to-Head Comparison of PET, SPECT, CCTA in Diagnosing CAD - American College of Cardiology [acc.org]
- 10. Comparison of Coronary CT Angiography, SPECT, PET, and Hybrid Imaging for Diagnosis of Ischemic Heart Disease Determined by Fractional Flow Reserve - PMC [pmc.ncbi.nlm.nih.gov]
- 11. Comparison of the Diagnostic Accuracy of PET and SPECT for Coronary Artery Disease | Semantic Scholar [semanticscholar.org]
- To cite this document: BenchChem. [Detecting Coronary Artery Disease: A Comparative Guide to Sestamibi SPECT]. BenchChem, [2025]. [Online PDF]. Available at: [https://www.benchchem.com/product/b1142544#validation-of-sestamibi-spect-for-coronary-artery-disease-detection]

---

### Disclaimer & Data Validity:

The information provided in this document is for Research Use Only (RUO) and is strictly not intended for diagnostic or therapeutic procedures. While BenchChem strives to provide accurate protocols, we make no warranties, express or implied, regarding the fitness of this product for every specific experimental setup.



**Technical Support:** The protocols provided are for reference purposes. Unsure if this reagent suits your experiment? [[Contact our Ph.D. Support Team for a compatibility check](#)]

**Need Industrial/Bulk Grade?** [Request Custom Synthesis Quote](#)

## BenchChem

Our mission is to be the trusted global source of essential and advanced chemicals, empowering scientists and researchers to drive progress in science and industry.

### Contact

Address: 3281 E Guasti Rd  
Ontario, CA 91761, United States  
Phone: (601) 213-4426  
Email: [info@benchchem.com](mailto:info@benchchem.com)