

Deep Anterior Lamellar Keratoplasty (DALK) for Keratoconus: A Technical Guide

Author: BenchChem Technical Support Team. **Date:** December 2025

Compound of Interest

Compound Name: dALK-3

Cat. No.: B15575147

[Get Quote](#)

For Researchers, Scientists, and Drug Development Professionals

Abstract

Deep Anterior Lamellar Keratoplasty (DALK) has emerged as a preferred surgical intervention for advanced keratoconus, offering significant advantages over traditional penetrating keratoplasty (PK).[1][2] By selectively replacing the diseased corneal stroma while preserving the patient's own healthy endothelium and Descemet's membrane (DM), DALK mitigates the risk of endothelial graft rejection, a major cause of graft failure in PK.[1][2][3] This technical guide provides a comprehensive overview of the DALK procedure for keratoconus, focusing on the predominant surgical techniques, quantitative clinical outcomes, and detailed experimental protocols. The content is intended to serve as a resource for researchers, scientists, and professionals involved in the development of novel therapeutic strategies for corneal diseases.

Introduction

Keratoconus is a progressive, non-inflammatory ectatic disorder of the cornea characterized by thinning and protrusion, leading to irregular astigmatism and impaired vision.[1] In advanced stages, when conservative treatments such as glasses or contact lenses fail to provide adequate visual function, surgical intervention becomes necessary.[1] For decades, penetrating keratoplasty (PK) was the standard of care. However, the advent of lamellar keratoplasty techniques, particularly DALK, has revolutionized the surgical management of keratoconus.[1][2]

The primary advantage of DALK lies in its preservation of the host's endothelium, thereby eliminating the risk of endothelial rejection and reducing the incidence of postoperative complications such as ocular hypertension.[1][4][5][6] While the procedure is technically more challenging with a steeper learning curve compared to PK, advancements in surgical techniques, most notably the "big-bubble" method, have improved success rates and clinical outcomes.[1]

Surgical Techniques

The goal of DALK is the complete removal of the corneal stroma down to Descemet's membrane. Two primary techniques are employed to achieve this: the big-bubble technique and manual dissection.

Big-Bubble Technique

The big-bubble technique, first described by Anwar, is the most popular method for achieving a Descemetic DALK (D-DALK), where the stroma is completely excised, baring the DM.[7][8] This technique relies on the forceful injection of air into the deep stroma to create a cleavage plane between the stroma and Descemet's membrane.[7][8]

Experimental Protocol: Big-Bubble DALK

- **Donor Tissue Preparation:** A full-thickness donor cornea is trephined to the desired diameter (typically 7.0 to 9.0 mm).[9] The donor endothelium and Descemet's membrane are then stripped and removed.
- **Host Cornea Trephination:** The host cornea is partially trephined to approximately 80-90% of its stromal depth.[2][10] The diameter is determined by the extent of the ectasia.
- **Cannula Insertion:** A 27-gauge needle or a specialized cannula (e.g., Fogla cannula) is inserted into the deep stroma at the base of the trephination and advanced towards the center of the cornea.[7][10]
- **Air Injection:** Air is forcefully injected into the deep stroma to create a "big bubble" that separates Descemet's membrane from the overlying stroma.[7][9][11] The formation of a large, silvery circle indicates a successful bubble formation that has reached beyond the trephination margins.[11] Two main types of big bubbles can be formed:

- Type 1 Bubble: Air separates the pre-Descemet layer (Dua's layer) from the deep stroma. This is the more common and preferred type as it provides additional strength to the recipient bed.[8]
- Type 2 Bubble: Air separates Descemet's membrane from the pre-Descemet layer.[8]
- Anterior Stromal Excision: The anterior stroma overlying the big bubble is excised.[7][11] A paracentesis may be performed to lower intraocular pressure.[9]
- Recipient Bed Preparation: The remaining stromal tissue is carefully removed in quadrants using scissors, taking care not to rupture Descemet's membrane.[11]
- Graft Placement and Suturing: The prepared donor corneal graft is placed on the recipient bed and sutured into place using interrupted or running sutures (e.g., 10-0 nylon).[7][10]

Manual Dissection Technique

Manual dissection is an alternative technique that can be used as a primary approach or as a rescue technique when the big-bubble formation is unsuccessful.[12] This method involves a layer-by-layer removal of the stroma.

Experimental Protocol: Manual Dissection DALK

- Initial Trephination and Stromal Debulking: Similar to the big-bubble technique, a partial-thickness trephination is performed. A significant portion of the anterior stroma is then manually excised.
- Layer-by-Layer Dissection: Using a blade and spatula, the remaining stroma is meticulously dissected in layers.[13] A peripheral pocket may be created to facilitate the peeling of stromal tissue.[13]
- Groove and Peel Technique: A variation of manual dissection involves creating a deep circumferential groove at the pre-Descemet level and then dissecting towards the center to peel off the remaining stroma.[12][14]
- Graft Placement and Suturing: Once the desired depth is reached, the donor graft is sutured in the same manner as in the big-bubble technique.

Quantitative Clinical Outcomes

The success of the DALK procedure is evaluated based on several quantitative measures, including visual acuity, endothelial cell density, corneal thickness, and the incidence of complications. The following tables summarize data from various studies comparing DALK with PK and analyzing outcomes of different DALK techniques.

Table 1: Visual and Refractive Outcomes

Outcome Measure	DALK	PK	Follow-up	Source(s)
Best Corrected Visual Acuity (BCVA) (logMAR)				
0.46 ± 0.20	-	1 year	[15]	
0.44 ± 0.54	-	1 year	[16]	
0.26	0.18	-	[17]	
0.54 ± 0.17	0.52 ± 0.14	1 year	[18]	
20/25 (0.09 ± 0.1 logMAR)	-	~6.4 years	[19]	
20/32	20/32	30 months	[4][5][20]	
Spherical Equivalent (SE) (Diopters)				
-5.65 ± 0.84	-	1 year	[15]	
-2.6 ± 3.5	-	~6.4 years	[19]	
Topographic Astigmatism (Diopters)				
2.78 ± 1.35	-	1 year	[15]	
2.9 ± 1.3	-	~6.4 years	[19]	
3.69 ± 2.80	3.66 ± 2.65	-	[3]	
Maximum Keratometry (Kmax) (Diopters)				

Pre-op	62.1 ± 4.60	-	[15]	
Post-op (1 year)	49.1 ± 3.10	-	[15]	
Pre-op	60.7 ± 6.1	-	[19]	
Post-op	44.4 ± 2.2	-	~6.4 years	[19]

Table 2: Endothelial Cell Density (ECD) and Central Corneal Thickness (CCT)

Outcome Measure	DALK	PK	Follow-up	Source(s)
Endothelial Cell Density (ECD) (cells/mm ²)				
Pre-op	2494 ± 382	2494 ± 382	[4][5][20]	[19]
Post-op (10 years)	1521 ± 659	-	[4][5][20]	
Pre-op	2198 ± 373	-	[19]	
Post-op	2070.5 ± 367.5	-	~6.4 years	
Endothelial Cell Loss (ECL) (%)				
21.62%	47.82%	4 years	[21]	[18]
3.78 ± 2.1%	20.56 ± 10.11%	6 months	[18]	
~50% lower than PK	-	10 & 20 years	[4]	
Central Corneal Thickness (CCT) (μm)				
Pre-op	334 ± 50	-	[22]	[18]
Post-op (1 month)	532 ± 62	-	[22]	
Post-op (1 month after suture removal)	517 ± 58	-	[22]	
Post-op (1 year)	451.6 ± 83.5	525.5 ± 37.1	[18]	

Table 3: Complications and Graft Survival

Complication/Outcome	DALK	PK	Source(s)
Graft Rejection	19.7%	33.5%	[17][23]
11.3% (stromal/epithelial)	-	[19]	
Suture-Related Complications	72%	48.6%	[17][23]
Conversion to PK	15%	-	[15]
Postoperative Ocular Hypertension	Lower incidence	Higher incidence	[4][5][6][20]
Graft Survival (10 years)	97.0%	96.4%	[4][6]
Graft Survival (20 years)	97.0%	94.9%	[4][6]

Higher-Order Aberrations

Higher-order aberrations (HOAs) are complex refractive errors that can affect the quality of vision. Studies have shown that the optical quality of the anterior corneal surface is significantly better after DALK compared to PK.[24][25] Total HOAs from the anterior corneal surface are significantly lower in DALK eyes.[24][25] However, the total HOAs from the posterior corneal surface are comparable between postoperative groups.[24][25] Postoperative corneal HOAs, particularly from the anterior surface, are significantly correlated with worse visual acuity after DALK.[16]

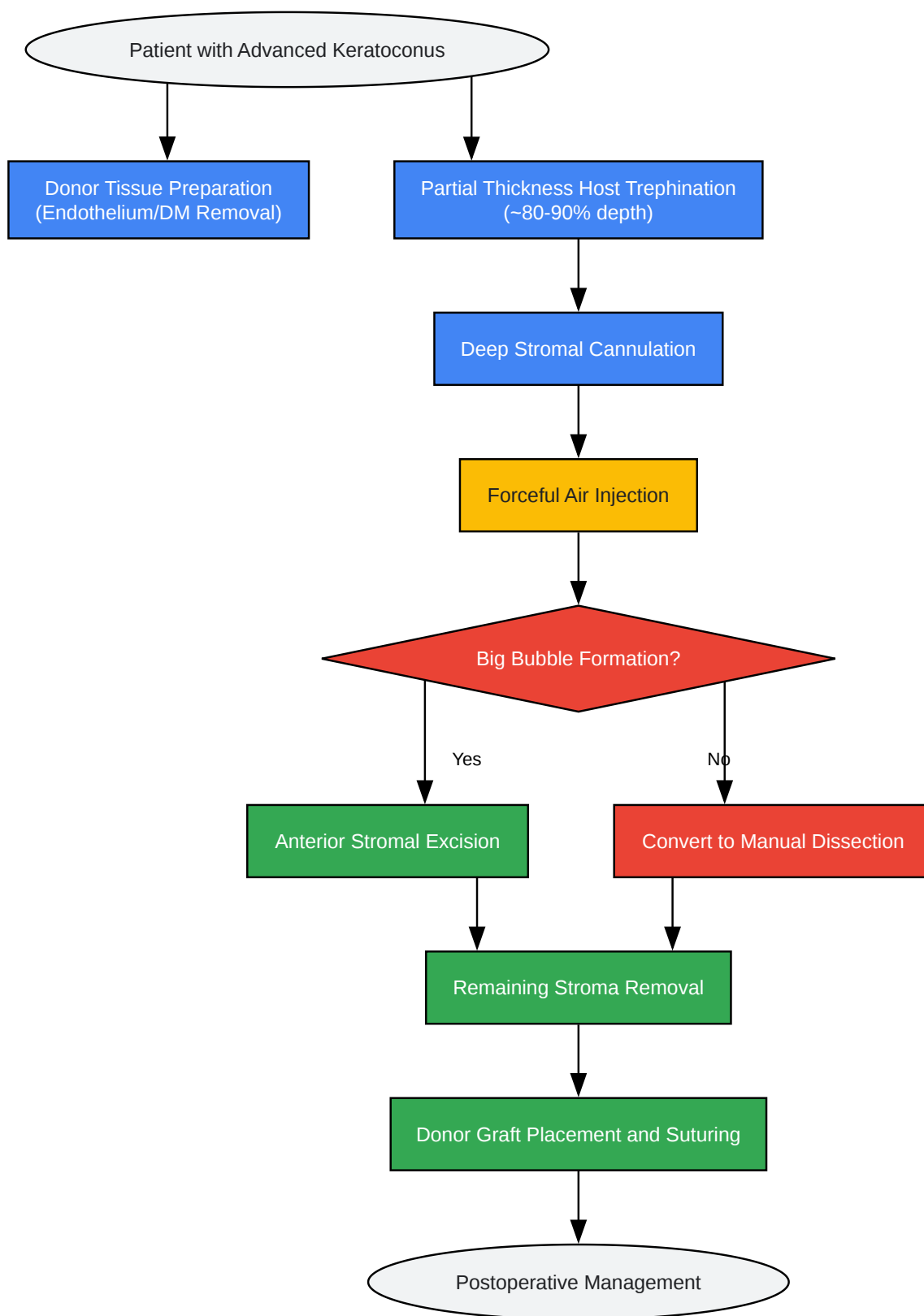
Signaling Pathways and Future Directions

While the surgical techniques for DALK are well-established, research into the underlying biological processes of corneal wound healing and nerve regeneration following the procedure is ongoing. Understanding the signaling pathways involved in keratocyte activation, stromal remodeling, and re-innervation could lead to the development of novel therapeutic agents to improve visual outcomes and reduce complications. For instance, modulating inflammatory

pathways could potentially reduce interface haze, a known complication of lamellar keratoplasty. Further investigation into the role of growth factors and neurotrophic factors in promoting corneal nerve regeneration could lead to improved corneal sensitivity and a reduction in dry eye symptoms post-surgery.

Visualizations

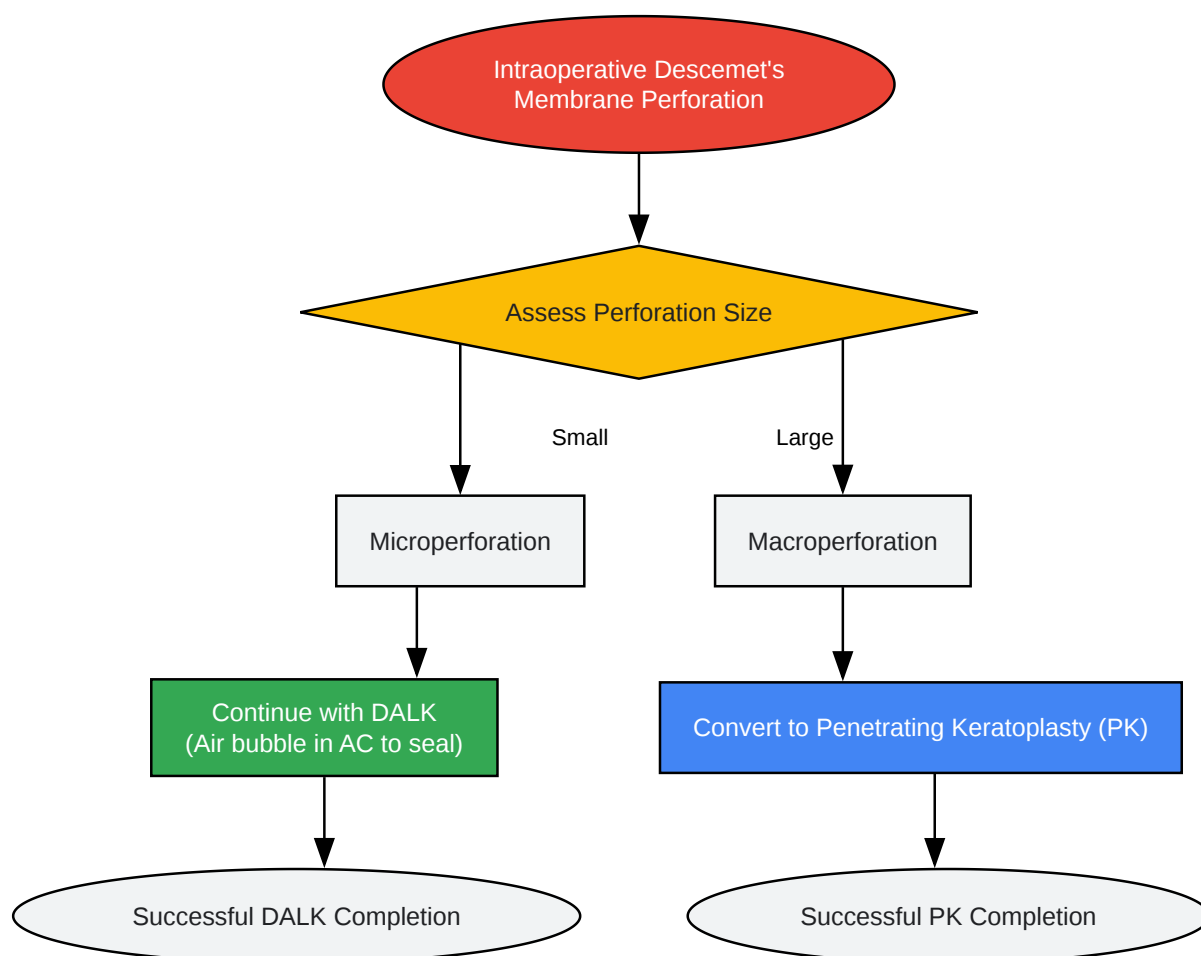
DALK Big-Bubble Technique Workflow



[Click to download full resolution via product page](#)

Caption: Workflow of the DALK Big-Bubble Technique.

Intraoperative Complication Management: Descemet's Membrane Perforation



[Click to download full resolution via product page](#)

Need Custom Synthesis?

BenchChem offers custom synthesis for rare earth carbides and specific isotopic labeling.

Email: info@benchchem.com or [Request Quote Online](#).

References

- 1. Deep anterior lamellar keratoplasty for keratoconus: Elements for success - PMC [pmc.ncbi.nlm.nih.gov]

- 2. tandfonline.com [tandfonline.com]
- 3. heraldopenaccess.us [heraldopenaccess.us]
- 4. reviewofoptometry.com [reviewofoptometry.com]
- 5. bjo.bmj.com [bjo.bmj.com]
- 6. reviewofoptometry.com [reviewofoptometry.com]
- 7. researchgate.net [researchgate.net]
- 8. The Big Bubble Technique | Ento Key [entokey.com]
- 9. DALK: Performing Big-Bubble Keratoplasty | Corneal Physician [pv-cp-staging.hbrsd.com]
- 10. Deep Anterior Lamellar Keratoplasty (DALK) [webeye.ophth.uiowa.edu]
- 11. aao.org [aao.org]
- 12. eversightvision.org [eversightvision.org]
- 13. youtube.com [youtube.com]
- 14. aao.org [aao.org]
- 15. One-year Visual and Refractive Outcomes of Deep Anterior Lamellar Keratoplasty (DALK) in Patients with Advanced Keratoconus - PubMed [pubmed.ncbi.nlm.nih.gov]
- 16. iovs.arvojournals.org [iovs.arvojournals.org]
- 17. aao.org [aao.org]
- 18. mdpi.com [mdpi.com]
- 19. Long-term clinical outcomes of deep anterior lamellar keratoplasty in patients with keratoconus - PubMed [pubmed.ncbi.nlm.nih.gov]
- 20. Long-term outcomes of deep anterior lamellar versus penetrating keratoplasty for keratoconus - PubMed [pubmed.ncbi.nlm.nih.gov]
- 21. Corneal endothelium after deep anterior lamellar keratoplasty and penetrating keratoplasty for keratoconus: A four-year comparative study - PMC [pmc.ncbi.nlm.nih.gov]
- 22. Stabilization Period for Central Corneal Thickness, Anterior Chamber Depth, and Iridocorneal Angle Parameters After Deep Anterior Lamellar Keratoplasty in Keratoconus Patients - PMC [pmc.ncbi.nlm.nih.gov]
- 23. reviewofoptometry.com [reviewofoptometry.com]
- 24. Higher order aberrations after keratoplasty for keratoconus - PubMed [pubmed.ncbi.nlm.nih.gov]
- 25. researchgate.net [researchgate.net]

- To cite this document: BenchChem. [Deep Anterior Lamellar Keratoplasty (DALK) for Keratoconus: A Technical Guide]. BenchChem, [2025]. [Online PDF]. Available at: [https://www.benchchem.com/product/b15575147#dalk-procedure-for-keratoconus]

Disclaimer & Data Validity:

The information provided in this document is for Research Use Only (RUO) and is strictly not intended for diagnostic or therapeutic procedures. While BenchChem strives to provide accurate protocols, we make no warranties, express or implied, regarding the fitness of this product for every specific experimental setup.

Technical Support: The protocols provided are for reference purposes. Unsure if this reagent suits your experiment? [[Contact our Ph.D. Support Team for a compatibility check](#)]

Need Industrial/Bulk Grade? [Request Custom Synthesis Quote](#)

BenchChem

Our mission is to be the trusted global source of essential and advanced chemicals, empowering scientists and researchers to drive progress in science and industry.

Contact

Address: 3281 E Guasti Rd
Ontario, CA 91761, United States
Phone: (601) 213-4426
Email: info@benchchem.com