

# Dealing with high bowel activity in abdominal Pentetreotide imaging

**Author:** BenchChem Technical Support Team. **Date:** December 2025

## Compound of Interest

Compound Name: Pentetreotide

Cat. No.: B1679299

[Get Quote](#)

## Technical Support Center: Abdominal Pentetreotide Imaging

This guide provides troubleshooting and frequently asked questions (FAQs) for researchers, scientists, and drug development professionals dealing with high bowel activity during abdominal **Pentetreotide** ( $^{111}\text{In}$ -**pentetreotide**, Octreoscan) imaging for neuroendocrine tumor (NET) evaluation.

## Frequently Asked Questions (FAQs)

Q1: Why is high bowel activity a significant issue in abdominal **Pentetreotide** imaging?

High physiological uptake of  $^{111}\text{In}$ -**pentetreotide** in the bowel is a common challenge that can complicate image interpretation.[1] This activity can obscure or be mistaken for pathological uptake in neuroendocrine tumors, particularly in the abdomen and pelvis.[2] Differentiating true tumor lesions from mobile, transient bowel activity is critical for accurate diagnosis, staging, and assessment of treatment response.[3][4]

Q2: What is the underlying cause of bowel activity in **Pentetreotide** scans?

While  $^{111}\text{In}$ -**pentetreotide** is primarily cleared by the kidneys, a smaller portion (around 2%) undergoes hepatobiliary excretion into the bowel.[3] This physiological process leads to the accumulation of the radiotracer in the intestines. Bowel activity is typically minimal or absent on

images taken 4 hours post-injection but often becomes visible at 24 hours and may persist or change location on 48-hour images.

Q3: What are the primary strategies to minimize interference from bowel activity?

The main strategies focus on patient preparation and optimized imaging protocols. These include:

- **Dietary Modification:** Implementing a clear liquid or low-residue diet before and during the imaging period.
- **Bowel Cleansing:** Using laxatives to promote the clearance of the radiotracer from the intestines.
- **Hydration:** Ensuring the patient is well-hydrated to facilitate renal clearance of the tracer.
- **Delayed Imaging:** Acquiring images at multiple time points (e.g., 24 and 48 hours) to track the movement of activity, which helps distinguish it from static tumor uptake.

Q4: When are laxatives recommended, and what are the contraindications?

The use of laxatives should be considered on an individual basis, especially when the abdomen is the primary area of interest. Mild oral laxatives may be administered the evening before and/or after the injection to help clear intestinal activity. However, laxatives are contraindicated in patients with active diarrhea or in those with suspected insulinoma due to the risk of inducing hypoglycemia.

Q5: How do different imaging time points (4, 24, and 48 hours) help manage this issue?

Each imaging time point offers distinct advantages:

- **4-Hour Imaging:** Provides a baseline before significant bowel activity appears, though the tumor-to-background ratio is lower, potentially causing some lesions to be missed.
- **24-Hour Imaging:** This is the optimal time for tumor localization due to a higher tumor-to-background ratio. However, bowel activity is often present at this time.

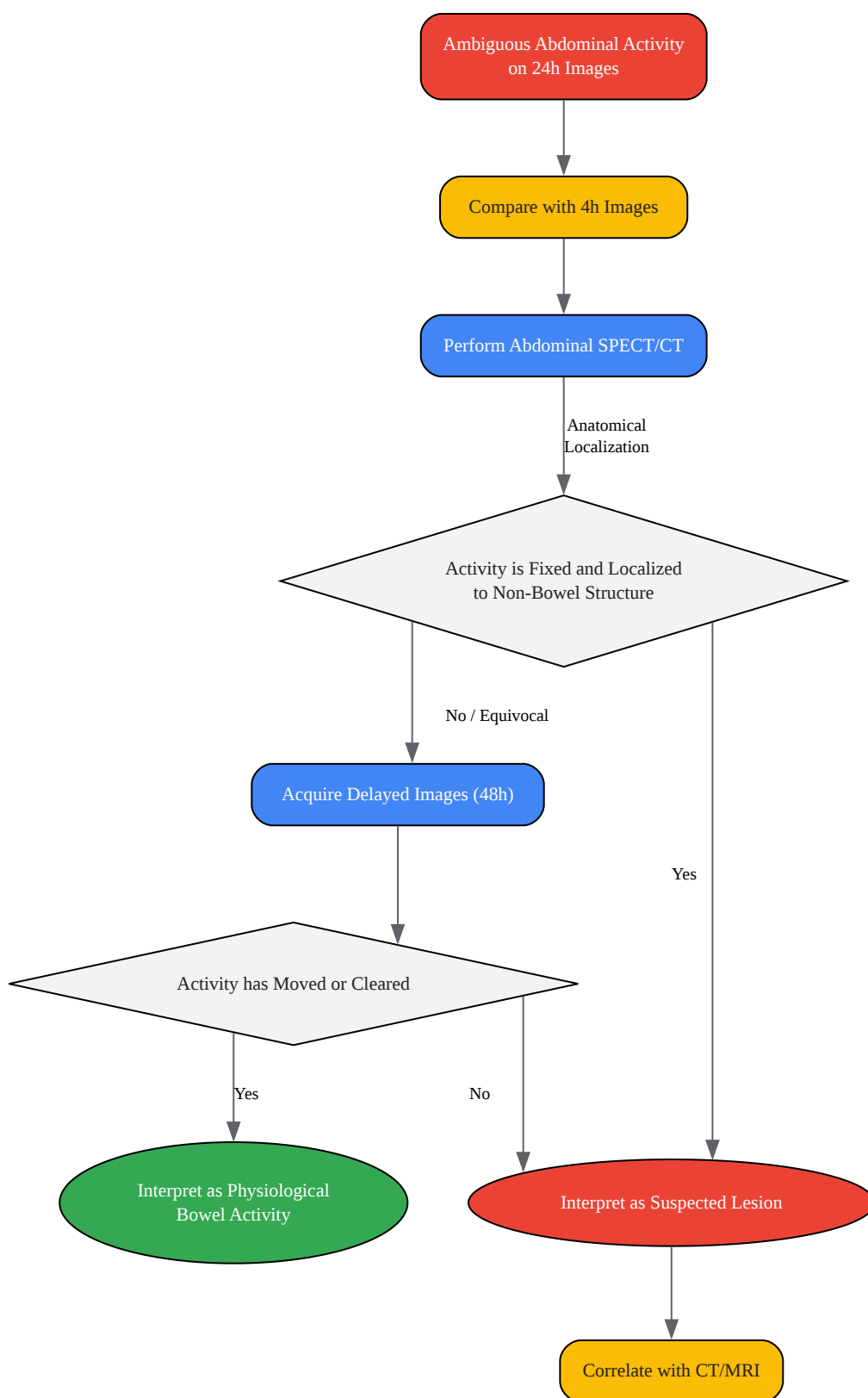
- 48-Hour Imaging: This delayed time point is valuable when 24-hour images show significant bowel activity. Physiological bowel content will likely have moved or cleared, helping to differentiate it from fixed pathological uptake.

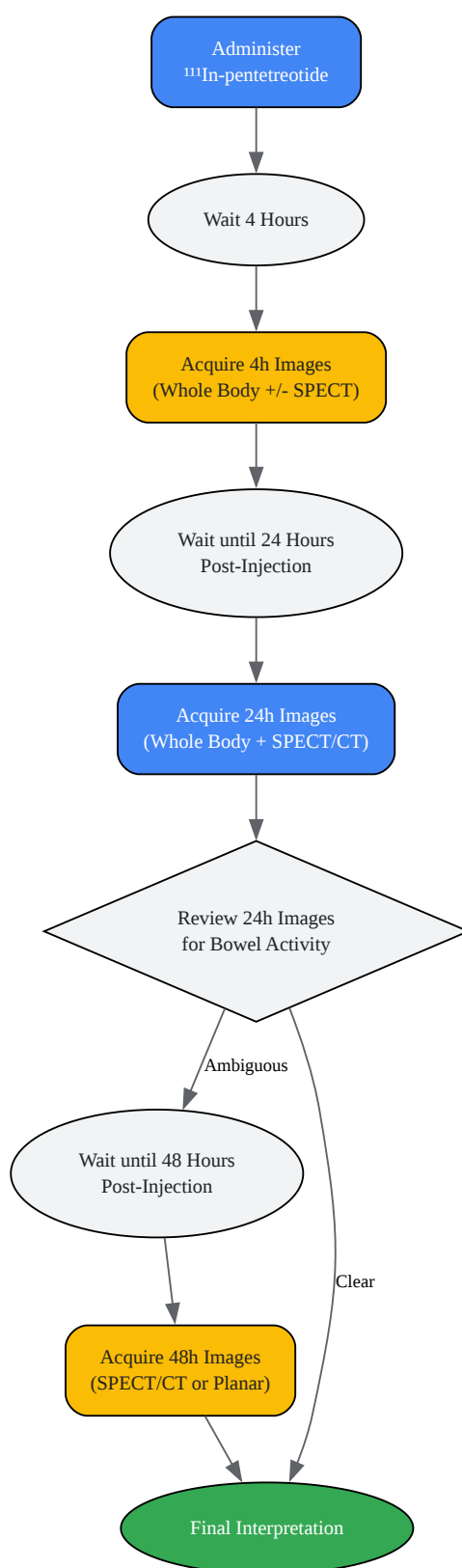
Q6: What is the role of SPECT/CT in this context?

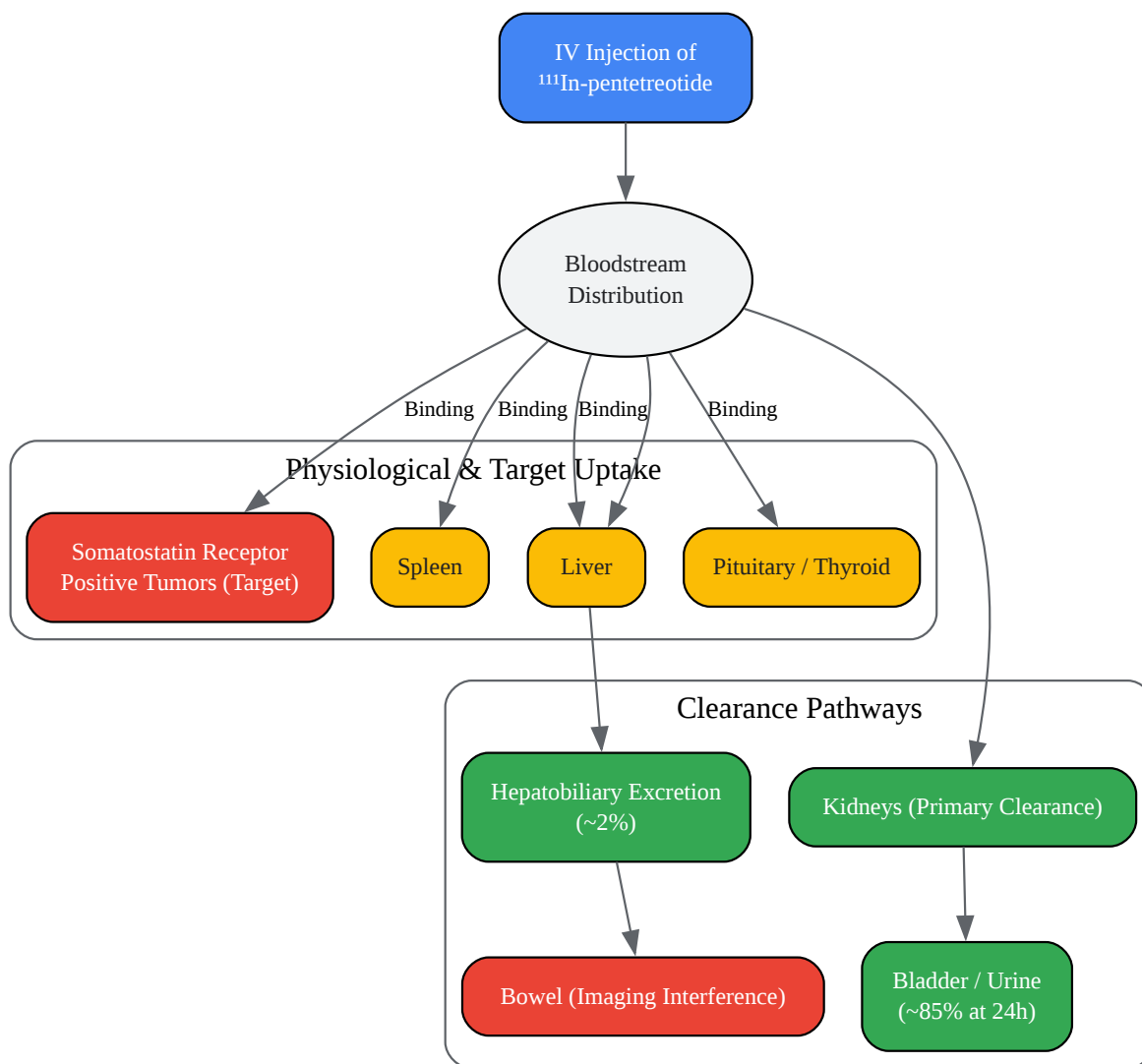
Single Photon Emission Computed Tomography combined with Computed Tomography (SPECT/CT) is a critical tool for addressing ambiguous abdominal activity. By fusing the functional data from the SPECT scan with the anatomical detail from the CT, SPECT/CT allows for precise localization of  $^{111}\text{In}$ -**pentetreotide** uptake, definitively distinguishing between activity within the bowel lumen and uptake in a mesenteric lymph node or other soft tissue structure.

## Troubleshooting Guide: Ambiguous Abdominal Activity

This guide provides a logical workflow for resolving cases where high bowel activity may be obscuring or mimicking disease on 24-hour **Pentetreotide** images.







[Click to download full resolution via product page](#)

### Need Custom Synthesis?

BenchChem offers custom synthesis for rare earth carbides and specific isotopic labeling.

Email: [info@benchchem.com](mailto:info@benchchem.com) or [Request Quote Online](#).

## References

- 1. normanregional.com [normanregional.com]
- 2. 111 In-pentetreotide SPECT CT Value in Follow-up of Patients with Neuro-Endocrine Tumors - PMC [pmc.ncbi.nlm.nih.gov]
- 3. jnm.snmjournals.org [jnm.snmjournals.org]
- 4. karger.com [karger.com]
- To cite this document: BenchChem. [Dealing with high bowel activity in abdominal Pentetreotide imaging]. BenchChem, [2025]. [Online PDF]. Available at: [https://www.benchchem.com/product/b1679299#dealing-with-high-bowel-activity-in-abdominal-pentetreotide-imaging]

---

### Disclaimer & Data Validity:

The information provided in this document is for Research Use Only (RUO) and is strictly not intended for diagnostic or therapeutic procedures. While BenchChem strives to provide accurate protocols, we make no warranties, express or implied, regarding the fitness of this product for every specific experimental setup.

**Technical Support:** The protocols provided are for reference purposes. Unsure if this reagent suits your experiment? [[Contact our Ph.D. Support Team for a compatibility check](#)]

**Need Industrial/Bulk Grade?** [Request Custom Synthesis Quote](#)

## BenchChem

Our mission is to be the trusted global source of essential and advanced chemicals, empowering scientists and researchers to drive progress in science and industry.

### Contact

Address: 3281 E Guasti Rd

Ontario, CA 91761, United States

Phone: (601) 213-4426

Email: [info@benchchem.com](mailto:info@benchchem.com)