

Cross-Validation of Iotalamic Acid CT Imaging with Histological Findings: A Comparative Guide

Author: BenchChem Technical Support Team. **Date:** December 2025

Compound of Interest

Compound Name: *Iotalamic acid*

Cat. No.: *B1662528*

[Get Quote](#)

For Researchers, Scientists, and Drug Development Professionals

This guide provides a comprehensive comparison of **iotalamic acid**-enhanced computed tomography (CT) imaging with corresponding histological findings for the assessment of renal structures and pathologies. While direct cross-validation studies specifically for **iotalamic acid** are limited in published literature, this document synthesizes data from studies using similar iodinated contrast agents and relevant research on quantitative CT validation. This guide offers detailed experimental protocols, comparative data, and visualizations to aid researchers in designing and interpreting studies involving renal imaging and histology.

I. Introduction to Iotalamic Acid and Renal Imaging

Iotalamic acid is an iodinated contrast agent commonly used in CT imaging to enhance the visualization of vascular structures and organs, including the kidneys.[1] Following intravenous injection, **iotalamic acid** is rapidly distributed throughout the circulatory system and is excreted unchanged by glomerular filtration.[2][3] This property makes it useful not only for anatomical imaging but also for the functional assessment of the kidneys, particularly for measuring the glomerular filtration rate (GFR).[1] The correlation of imaging findings with the gold standard of histological analysis is crucial for validating the accuracy and utility of CT as a diagnostic and monitoring tool in nephrology research.

II. Histological Effects of Iodinated Contrast Media on the Kidney

Direct histological validation of **iotalamic acid** CT is scarce. However, studies on other iodinated contrast agents, such as iohexol and iopromide, in animal models provide insights into the expected histopathological changes. These changes are often studied in the context of contrast-induced acute kidney injury (CI-AKI).

Key Histological Findings:

- **Tubular Epithelial Cell (TEC) Vacuolization:** This is a common finding following the administration of iodinated contrast media.[\[4\]](#)[\[5\]](#)[\[6\]](#) These vacuoles are often interpreted as a sign of drug toxicity and are believed to result from the pinocytosis of the contrast agent and subsequent lysosomal fusion.[\[4\]](#)[\[6\]](#) However, the degree of vacuolization does not always correlate with the severity of renal dysfunction.[\[7\]](#)[\[8\]](#)
- **Tubular Necrosis:** In more severe cases of CI-AKI, particularly when an additional insult like ischemia is present, overt tubular necrosis can be observed.[\[4\]](#)[\[5\]](#)[\[8\]](#)[\[9\]](#)[\[10\]](#)
- **Loss of Brush Border:** Damage to the proximal tubular cells can lead to the loss of the brush border, which is visible on histological examination.[\[4\]](#)
- **Proteinaceous Casts:** The presence of casts within the renal tubules can also be an indicator of kidney injury.[\[4\]](#)
- **Changes in iNOS Expression:** Studies have shown that iodinated contrast agents can alter the expression of inducible nitric oxide synthase (iNOS) in the glomeruli and other renal structures.[\[4\]](#)

The table below summarizes histological findings from a study on the effects of the iodinated contrast agent iopromide on rat kidneys.

Histological Parameter	Control Group Score	24h Post-Iopromide Score	48h Post-Iopromide Score	72h Post-Iopromide Score
Loss of Brush Border	0.00 ± 0.00	1.00 ± 0.82	0.83 ± 0.75	0.83 ± 0.75
Tubular Necrosis	0.00 ± 0.00	0.83 ± 0.75	0.83 ± 0.75	0.67 ± 0.52
Proteinaceous Casts	0.00 ± 0.00	1.33 ± 0.82	1.00 ± 0.63	0.50 ± 0.55

Data adapted from a study on iopromide in a rat model. Scores represent the severity of the histological finding.[\[4\]](#)

III. Quantitative CT Imaging and Histological Correlation

While direct correlations for **iotalamic acid** are not readily available, research with other contrast agents has demonstrated the potential of quantitative CT metrics to correlate with histological features of renal disease.

Key Quantitative CT Parameters:

- **Hounsfield Units (HU):** The attenuation of X-rays, measured in HU, can be used to differentiate between different tissue types and assess contrast enhancement. Studies have shown that HU measurements in different phases of contrast enhancement can help differentiate between subtypes of renal cell carcinoma (RCC), which have distinct histological features.[\[2\]](#)[\[11\]](#)[\[12\]](#)[\[13\]](#)
- **CT Perfusion:** Perfusion CT can provide quantitative data on blood flow, blood volume, and permeability. These parameters have been shown to correlate with microvascular density in renal tumors, a key histological feature.[\[14\]](#)
- **Extracellular Volume (ECV) Fraction:** Calculated from pre- and post-contrast CT images, the ECV can reflect changes in the interstitial space of the kidney. In renal tumors, ECV has been shown to correlate with the pathological grade.[\[1\]](#)[\[15\]](#)[\[16\]](#) In the context of chronic

kidney disease, CT-derived metrics have been correlated with the degree of renal fibrosis observed in histological samples.[\[3\]](#)[\[17\]](#)

The following table presents a hypothetical correlation between quantitative CT parameters and histological findings, based on published research methodologies.

Quantitative CT Parameter	Potential Histological Correlate	Expected Correlation
Corticomedullary Phase Enhancement (HU)	Vascularity of Renal Cortex	Positive
Nephrographic Phase Enhancement (HU)	Tubular Function and Integrity	Variable
CT Perfusion (Blood Flow)	Microvascular Density	Positive
Extracellular Volume (ECV)	Interstitial Fibrosis/Edema	Positive

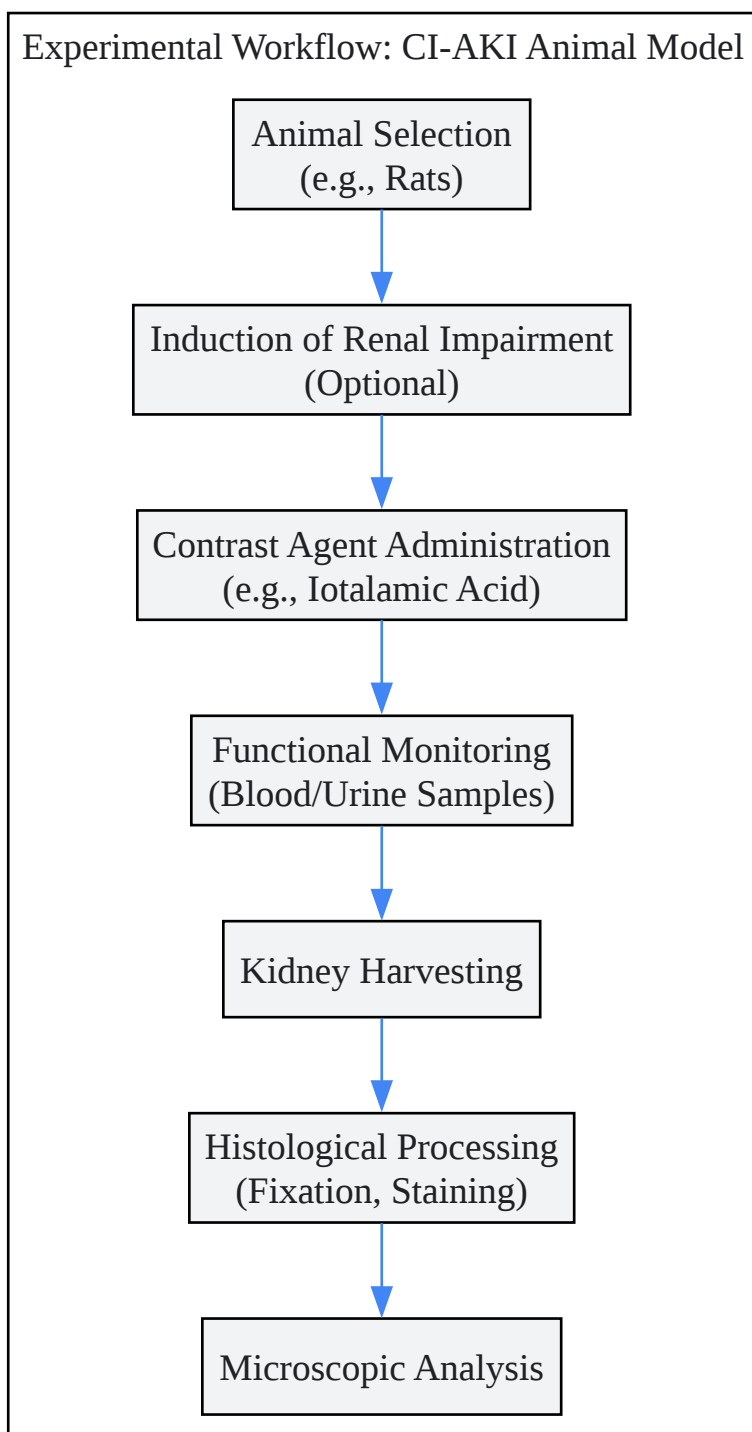
IV. Experimental Protocols

A. Animal Model for Contrast-Induced Acute Kidney Injury (CI-AKI)

Rodent models are commonly used to study the histopathological effects of contrast media. A typical protocol involves the following steps:

- **Animal Selection:** Sprague-Dawley or Wistar rats are frequently used.
- **Induction of Renal Impairment (Optional but common):** To increase susceptibility to CI-AKI, a pre-existing renal condition is often induced. This can be achieved through methods such as 5/6 nephrectomy or administration of drugs like indomethacin and L-NAME.[\[9\]](#)
- **Contrast Medium Administration:** The iodinated contrast agent (e.g., **iotalamic acid**, iohexol, iopromide) is administered intravenously. Doses are often higher than those used in clinical practice to reliably induce injury.

- **Monitoring:** Blood and urine samples are collected at various time points (e.g., 24, 48, 72 hours) to measure markers of renal function such as serum creatinine and blood urea nitrogen (BUN).[\[4\]](#)
- **Tissue Harvesting and Histological Analysis:** At the end of the study period, the animals are euthanized, and the kidneys are harvested. The tissue is then fixed in formalin, embedded in paraffin, sectioned, and stained with standard histological stains like Hematoxylin and Eosin (H&E) and Periodic acid-Schiff (PAS).[\[4\]](#)[\[5\]](#)



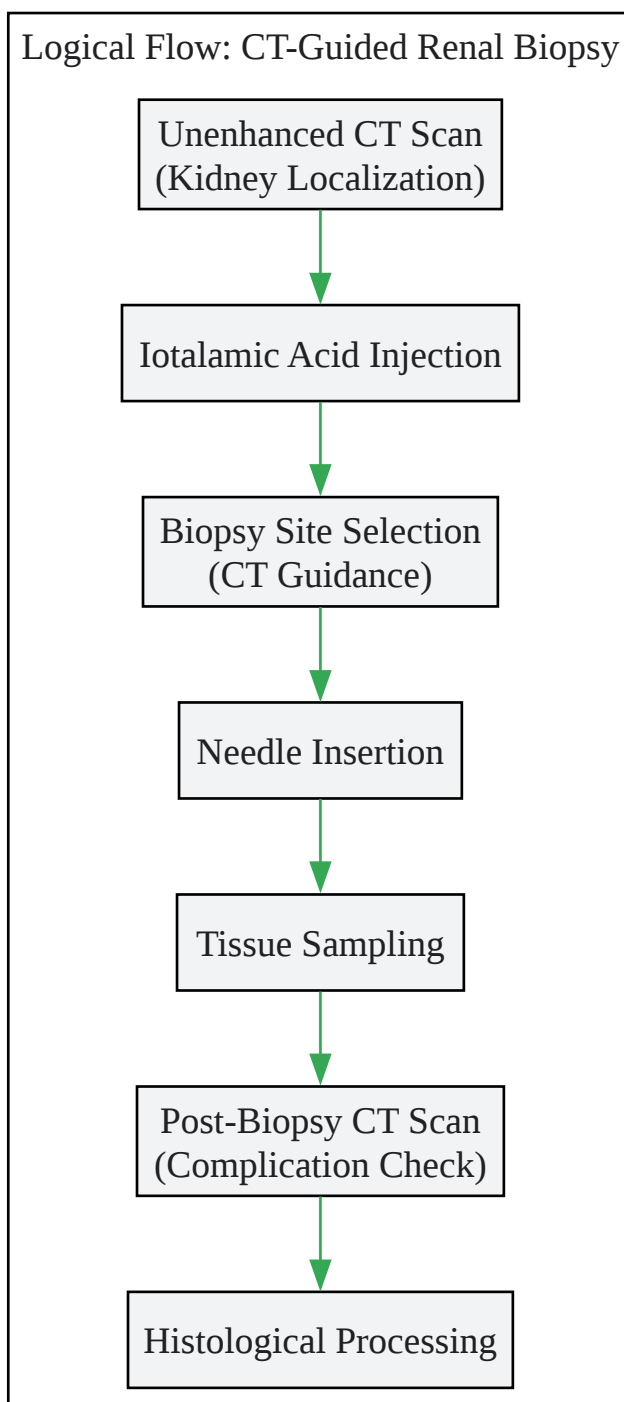
[Click to download full resolution via product page](#)

Experimental Workflow for CI-AKI Animal Models

B. CT-Guided Renal Biopsy

For direct histological correlation in larger animal models or clinical studies, a renal biopsy is required. CT guidance ensures accurate targeting of the desired renal tissue.

- **Patient/Animal Preparation:** The subject is positioned on the CT scanner table. An initial unenhanced CT scan is performed to localize the kidneys.
- **Contrast Administration:** **Iotalamic acid** is administered intravenously to enhance the renal parenchyma and vasculature.
- **Biopsy Site Selection:** The CT images are used to select a safe and appropriate needle trajectory, typically targeting the renal cortex and avoiding major blood vessels and the collecting system.
- **Needle Insertion:** Under real-time or intermittent CT guidance, a biopsy needle is advanced to the target location.
- **Tissue Sampling:** Once the needle is in the correct position, a tissue sample is obtained. Multiple samples may be taken.
- **Post-Biopsy Imaging:** A final CT scan may be performed to assess for any immediate complications, such as bleeding.
- **Histological Processing:** The biopsy core is then processed for histological examination as described above.



[Click to download full resolution via product page](#)

Logical Flow of CT-Guided Renal Biopsy

V. Comparison with Alternative Methods

Iotalamic acid CT imaging can be compared with other modalities for which histological validation is more established.

Modality	Advantages	Disadvantages	Histological Correlation
Iotalamic Acid CT	High spatial resolution, rapid acquisition, widely available.	Use of ionizing radiation, risk of CI-AKI.	Limited direct evidence; potential for correlation of quantitative metrics with histology.
Magnetic Resonance Imaging (MRI)	Excellent soft tissue contrast, no ionizing radiation. Techniques like T1 mapping and Diffusion Weighted Imaging (DWI) can provide quantitative data.	Longer scan times, higher cost, potential for nephrogenic systemic fibrosis with gadolinium-based contrast agents.	Strong correlation between T1 mapping/ECV and interstitial fibrosis has been demonstrated. [18] [19]
Ultrasound Elastography	Non-invasive, no radiation, provides information on tissue stiffness.	Operator dependent, limited by patient body habitus.	Correlates with the degree of renal fibrosis.
Renal Biopsy	Gold standard for diagnosis of renal parenchymal disease.	Invasive, risk of complications (bleeding, infection), potential for sampling error.	Provides the direct tissue sample for histological analysis.

VI. Conclusion

While direct, quantitative cross-validation studies of **iotalamic acid** CT imaging with renal histology are not abundant in the current literature, a substantial body of related research provides a strong foundation for such investigations. The known histopathological effects of iodinated contrast agents, coupled with the proven ability of quantitative CT to correlate with

histological features in other contexts, suggests that **iotalamic acid** CT is a powerful tool for renal assessment. Future research should focus on direct, head-to-head comparisons of **iotalamic acid** CT findings with histological analysis in well-controlled preclinical and clinical studies to further validate its role as a non-invasive biomarker of renal pathology.

Need Custom Synthesis?

BenchChem offers custom synthesis for rare earth carbides and specific isotopic labeling.

Email: info@benchchem.com or [Request Quote Online](#).

References

- 1. Predictive value of extracellular volume fraction determined using enhanced computed tomography for pathological grading of clear cell renal cell carcinoma: a preliminary study - PMC [pmc.ncbi.nlm.nih.gov]
- 2. kamj.journals.ekb.eg [kamj.journals.ekb.eg]
- 3. Detection and quantification of renal fibrosis by computerized tomography - PMC [pmc.ncbi.nlm.nih.gov]
- 4. Effects of iopromide contrast agents on kidney iNOS expression and tubular histopathology alterations - PMC [pmc.ncbi.nlm.nih.gov]
- 5. semmelweis.hu [semmelweis.hu]
- 6. Histopathological Evaluation of Contrast-Induced Acute Kidney Injury Rodent Models - PMC [pmc.ncbi.nlm.nih.gov]
- 7. X-Ray-Based 3D Histopathology of the Kidney Using Cryogenic Contrast-Enhanced MicroCT - PMC [pmc.ncbi.nlm.nih.gov]
- 8. Histopathological Evaluation of Contrast-Induced Acute Kidney Injury Rodent Models - PubMed [pubmed.ncbi.nlm.nih.gov]
- 9. A Novel Contrast-Induced Acute Kidney Injury Model Based on the 5/6-Nephrectomy Rat and Nephrotoxicological Evaluation of Iohexol and Iodixanol In Vivo - PMC [pmc.ncbi.nlm.nih.gov]
- 10. researchgate.net [researchgate.net]
- 11. Role of Contrast Enhancement and Corrected Attenuation Values of Renal Tumors in Predicting Renal Cell Carcinoma (RCC) Subtypes: Protocol for a Triphasic Multi-Slice Computed Tomography (CT) Procedure - PMC [pmc.ncbi.nlm.nih.gov]

- 12. iasj.rdd.edu.iq [iasj.rdd.edu.iq]
- 13. medicalsciencejournal.com [medicalsciencejournal.com]
- 14. [Correlation between pathologic features and perfusion CT of renal cancer: a feasibility study] - PubMed [pubmed.ncbi.nlm.nih.gov]
- 15. Predictive value of extracellular volume fraction determined using enhanced computed tomography for pathological grading of clear cell renal cell carcinoma: a preliminary study - PubMed [pubmed.ncbi.nlm.nih.gov]
- 16. researchgate.net [researchgate.net]
- 17. Detection and quantification of renal fibrosis by computerized tomography | PLOS One [journals.plos.org]
- 18. karger.com [karger.com]
- 19. Assessment of the extracellular volume fraction for the grading of clear cell renal cell carcinoma: first results and histopathological findings - PubMed [pubmed.ncbi.nlm.nih.gov]
- To cite this document: BenchChem. [Cross-Validation of Iotalamic Acid CT Imaging with Histological Findings: A Comparative Guide]. BenchChem, [2025]. [Online PDF]. Available at: [<https://www.benchchem.com/product/b1662528#cross-validation-of-iotalamic-acid-ct-imaging-with-histological-findings>]

Disclaimer & Data Validity:

The information provided in this document is for Research Use Only (RUO) and is strictly not intended for diagnostic or therapeutic procedures. While BenchChem strives to provide accurate protocols, we make no warranties, express or implied, regarding the fitness of this product for every specific experimental setup.

Technical Support: The protocols provided are for reference purposes. Unsure if this reagent suits your experiment? [[Contact our Ph.D. Support Team for a compatibility check](#)]

Need Industrial/Bulk Grade? [Request Custom Synthesis Quote](#)

BenchChem

Our mission is to be the trusted global source of essential and advanced chemicals, empowering scientists and researchers to drive progress in science and industry.

Contact

Address: 3281 E Guasti Rd

Ontario, CA 91761, United States

Phone: (601) 213-4426

Email: info@benchchem.com