

# Common pitfalls in the interpretation of Hynic-toc scans

**Author:** BenchChem Technical Support Team. **Date:** December 2025

## Compound of Interest

Compound Name: Hynic-toc

Cat. No.: B15605757

[Get Quote](#)

## Navigating Hynic-TOC Scans: A Technical Support Guide

Welcome to the technical support center for **Hynic-TOC** scans. This resource is designed for researchers, scientists, and drug development professionals to provide troubleshooting guidance and answer frequently asked questions regarding the interpretation of **Hynic-TOC** scan results.

### Frequently Asked Questions (FAQs)

Q1: What is **Hynic-TOC** and why is it used in imaging?

A1: **Hynic-TOC** (Hydrazinonicotinamide-Tyr3-Octreotide) is a radiopharmaceutical used for imaging tumors that express somatostatin receptors (SSTRs), particularly neuroendocrine tumors (NETs). It is labeled with Technetium-99m (99mTc), a radioisotope that is readily available and has favorable physical characteristics for gamma camera imaging, offering high-quality images with lower radiation exposure for the patient compared to other tracers like 111In-octreotide.<sup>[1][2][3][4]</sup>

Q2: What are the common causes of false-positive results in **Hynic-TOC** scans?

A2: False-positive findings in **Hynic-TOC** scans can arise from several factors:

- **Physiological Uptake:** Normal physiological uptake can occur in various organs and may be mistaken for malignancy. This includes the uncinate process of the pancreas, kidneys, spleen, pituitary gland, thyroid, and salivary glands.[1][2][4]
- **Inflammatory and Benign Lesions:** Increased tracer uptake can be seen in non-cancerous conditions such as inflammatory processes (e.g., colitis, prostatitis, thyroiditis), degenerative bone disease, fractures, and benign tumors like parathyroid adenomas.[2][5][6] Osteoblasts, for instance, express SSTR2, leading to accumulation at sites of bone remodeling.[2][6]
- **Other SSTR-Expressing Tumors:** Tumors other than NETs can also express somatostatin receptors, leading to positive scans. These may include meningioma, breast cancer, lymphoma, and prostatic cancer.[5]
- **Nonspecific Bowel Accumulation:** Nonspecific accumulation of the tracer in the bowel can lead to false-positive interpretations, especially when a single-acquisition protocol is used.[3]

Q3: What can lead to false-negative results in **Hynic-TOC** scans?

A3: False-negative results, where a tumor is present but not detected, can occur due to:

- **Low Receptor Density:** The tumor may have a low density of somatostatin receptors, or the receptor expression may change due to tumor dedifferentiation or therapy.[4][5]
- **Small Lesion Size:** The limited spatial resolution of SPECT imaging can make it difficult to detect very small lesions.[7]
- **High Background Activity:** Lesions located in or near organs with high physiological uptake, such as the liver or kidneys, can be obscured.[5]
- **Respiratory Motion Artifacts:** For lesions near the diaphragm, respiratory motion can cause artifacts that may lead to false-negative results.[8]

## Troubleshooting Guides

Issue 1: Unexpected uptake in the pancreatic head.

- **Question:** I see a focal intense uptake in the head of the pancreas on the scan, but there is no corresponding morphological abnormality on the CT. Could this be a false positive?

- Answer: Yes, this could be a physiological accumulation in the pancreatic uncinate process, which is a common finding in a small percentage of patients.[2][4] In some cases, it can be difficult to differentiate from a malignant process without further investigation.[2] SPECT/CT can help in assessing the normal anatomy, but if uncertainty remains, a multiphase CT or MRI may be required for a more accurate diagnosis.[2][6] One study noted that focal uptake in the uncinate process was observed in 19.4% of patients without evidence of malignancy.[7]

Issue 2: Diffuse or focal uptake in non-tumorous tissues.

- Question: My scan shows tracer accumulation in areas that do not correspond to the suspected tumor location, such as bones or the lungs. How should I interpret this?
- Answer: This is a common pitfall. Increased uptake in bones can be due to degenerative diseases or fractures, as osteoblasts express SSTR2.[2][6] Focal pulmonary uptake without a morphological pattern on CT has also been observed and can be associated with inflammatory reactions.[2][4] It's crucial to correlate the scintigraphic findings with clinical history and other imaging modalities like CT or MRI to avoid misinterpretation.

Issue 3: Inconsistent results between early and late imaging.

- Question: There is significant bowel activity on the 4-hour scan that was not present on the 1-hour scan. Is this indicative of a lesion?
- Answer: Not necessarily. Faint to moderate bowel activity is often visible on later scans due to hepatobiliary excretion of the tracer.[2][4] To minimize false-positive findings in the gut, a dual-acquisition protocol (e.g., at 1 and 4 hours post-injection) is recommended.[1][3] This allows for the differentiation of physiological bowel activity, which tends to change in location and intensity over time, from fixed pathological uptake.

## Data Presentation

The diagnostic performance of 99mTc-**Hynic-TOC** scans can vary between studies and patient populations. Below is a summary of reported quantitative data.

Study/Parameter	Sensitivity	Specificity	Positive Predictive Value (PPV)	Negative Predictive Value (NPV)	Accuracy
Artiko et al. (Multicenter Trial)	-	-	-	-	80%
Etchebehere et al. (L-NETs)	86%	85.7%	97.3%	50%	86%
Liepe and Becker (Midgut NETs)	81%	90%	94%	69%	-
Saponjski et al.	83.6%	82.6%	-	-	83.3%
Zhang et al. (PPGLs)	94.4%	42.9%	80.9%	75.0%	80.0%
Diagnostic Study for TIO	92.9%	54.5%	-	-	76.0%

Data compiled from multiple sources.[\[1\]](#)[\[8\]](#)[\[9\]](#)[\[10\]](#)[\[11\]](#)[\[12\]](#)

## Experimental Protocols

### Radiopharmaceutical Preparation (Tektrotyd® Kit)

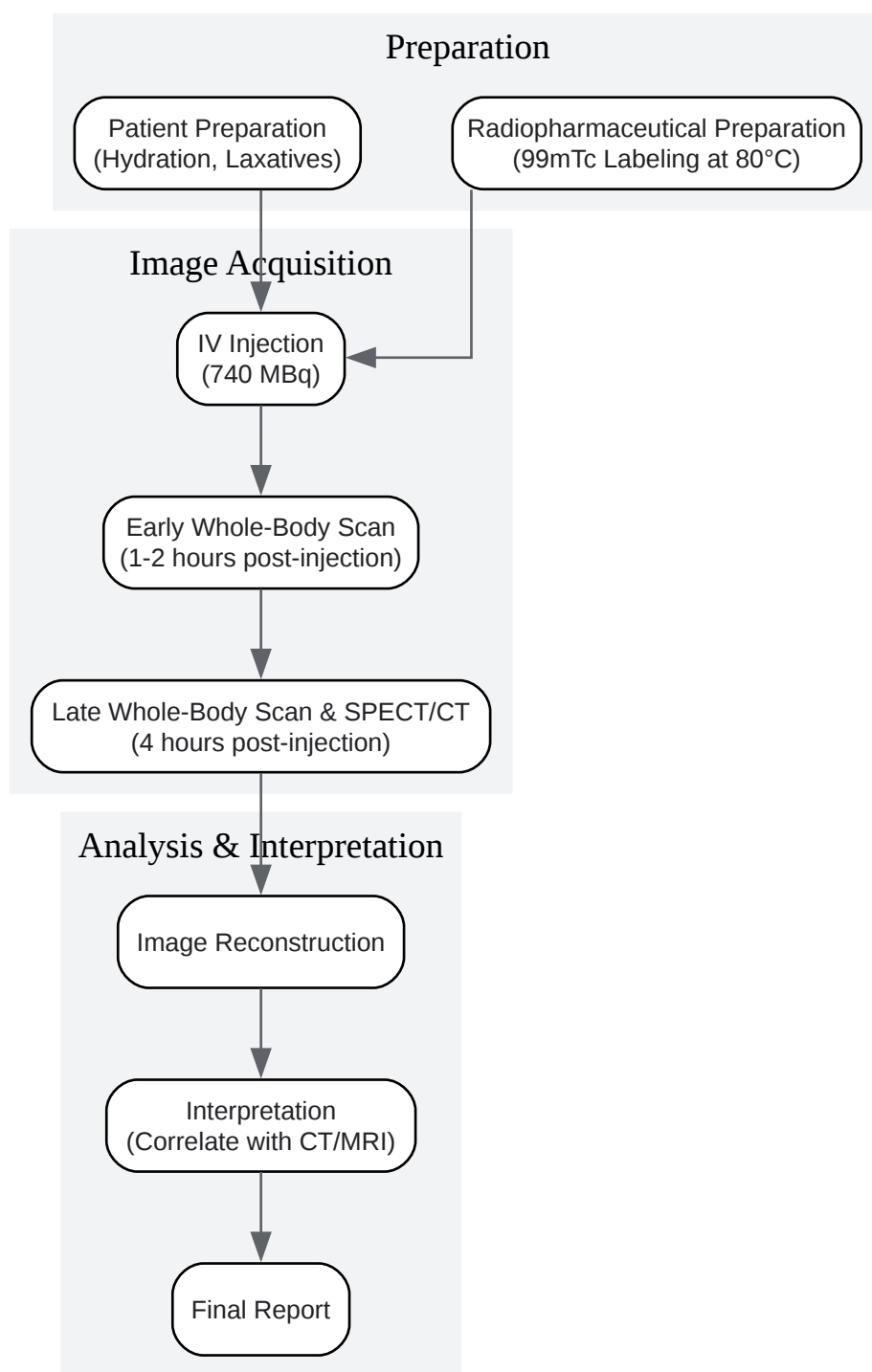
- Labeling: The **Hynic-TOC** peptide is labeled with 99mTc from a sodium pertechnetate solution. The radioactivity should be  $\leq 2.2$  GBq in a maximum volume of 1 ml.[\[1\]](#)
- Incubation: The solution is heated in a water bath or heating block at 80°C for 20 minutes.[\[1\]](#)  
[\[2\]](#)[\[4\]](#)[\[6\]](#) Maintaining this temperature is critical to achieve high radiochemical purity (ideally >90%).[\[2\]](#)[\[4\]](#)

- Administration: An average activity of 628–740 MBq (17-20 mCi) is administered to the patient intravenously.<sup>[1][11]</sup>

#### Patient Preparation and Image Acquisition

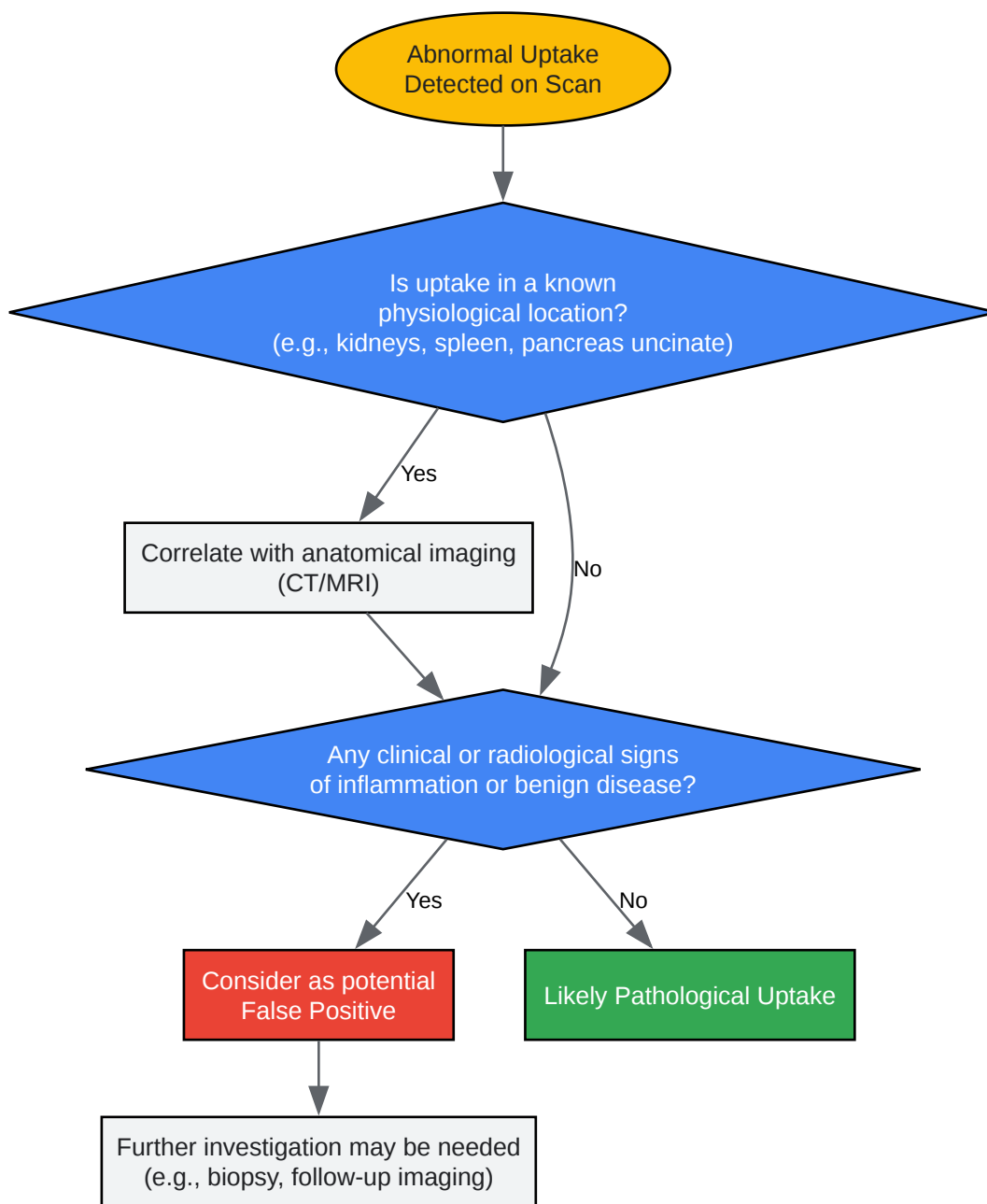
- Patient Preparation: Patients should be well-hydrated. Light food intake and mild laxatives are recommended, especially if the abdomen is the area of interest.<sup>[2]</sup>
- Imaging Protocol: A dual-acquisition protocol is often employed.
  - Early Scan: A whole-body scan is performed 1-2 hours after injection.<sup>[3][11]</sup>
  - Late Scan: A second whole-body scan and/or SPECT/CT of the region of interest is performed 4 hours post-injection.<sup>[2][3][6][11]</sup>
- Acquisition Parameters (Example):
  - Whole-Body Scan: Anterior and posterior projections, 256 x 1024 matrix, 13 cm/min scan speed.<sup>[2][6]</sup>
  - SPECT/CT: 360° noncircular orbit, step-and-shoot mode, 30 seconds per view, 128 x 128 matrix.<sup>[2][6]</sup>

## Visualizations



[Click to download full resolution via product page](#)

Caption: Standard experimental workflow for a **Hynic-TOC** scan.



[Click to download full resolution via product page](#)

Caption: Decision pathway for troubleshooting abnormal uptake.

#### Need Custom Synthesis?

BenchChem offers custom synthesis for rare earth carbides and specific isotopic labeling.

Email: [info@benchchem.com](mailto:info@benchchem.com) or [Request Quote Online](#).

## References

- 1. 99mTc-Hynic-TOC imaging in the diagnostic of neuroendocrine tumors - PMC [pmc.ncbi.nlm.nih.gov]
- 2. journals.viamedica.pl [journals.viamedica.pl]
- 3. jnm.snmjournals.org [jnm.snmjournals.org]
- 4. researchgate.net [researchgate.net]
- 5. journals.viamedica.pl [journals.viamedica.pl]
- 6. Limitations and pitfalls of 99mTc-EDDA/HYNIC-TOC (Tektrotyd) scintigraphy | Garai | Nuclear Medicine Review [journals.viamedica.pl]
- 7. researchgate.net [researchgate.net]
- 8. 99mTc-EDDA/HYNIC-TOC is a New Opportunity in Neuroendocrine Tumors of the Lung (and in other Malignant and Benign Pulmonary Diseases) - PMC [pmc.ncbi.nlm.nih.gov]
- 9. Diagnostic accuracy of 99mTc-HYNIC-TOC SPECT/CT for detecting osteomalacia-associated tumors - PMC [pmc.ncbi.nlm.nih.gov]
- 10. researchgate.net [researchgate.net]
- 11. The New Radiolabeled Peptide 99mTcEDDA/HYNIC-TOC: Is It a Feasible Choice for Diagnosing Gastroenteropancreatic NETs? - PMC [pmc.ncbi.nlm.nih.gov]
- 12. Diagnostic accuracy of 99mTc-HYNIC-TOC SPECT/CT for detecting osteomalacia-associated tumors - PubMed [pubmed.ncbi.nlm.nih.gov]
- To cite this document: BenchChem. [Common pitfalls in the interpretation of Hynic-toc scans]. BenchChem, [2025]. [Online PDF]. Available at: [https://www.benchchem.com/product/b15605757#common-pitfalls-in-the-interpretation-of-hynic-toc-scans]

---

### Disclaimer & Data Validity:

The information provided in this document is for Research Use Only (RUO) and is strictly not intended for diagnostic or therapeutic procedures. While BenchChem strives to provide accurate protocols, we make no warranties, express or implied, regarding the fitness of this product for every specific experimental setup.

**Technical Support:** The protocols provided are for reference purposes. Unsure if this reagent suits your experiment? [[Contact our Ph.D. Support Team for a compatibility check](#)]

**Need Industrial/Bulk Grade?** [Request Custom Synthesis Quote](#)

## BenchChem

Our mission is to be the trusted global source of essential and advanced chemicals, empowering scientists and researchers to drive progress in science and industry.

### Contact

Address: 3281 E Guasti Rd

Ontario, CA 91761, United States

Phone: (601) 213-4426

Email: [info@benchchem.com](mailto:info@benchchem.com)