

# Challenges in M-mode interpretation in patients with complex congenital heart disease

**Author:** BenchChem Technical Support Team. **Date:** December 2025

## Compound of Interest

Compound Name: M-MoDE-A (2)

Cat. No.: B15144752

[Get Quote](#)

## Technical Support Center: M-mode Interpretation in Complex Congenital Heart Disease

This technical support center provides troubleshooting guides and frequently asked questions (FAQs) to assist researchers, scientists, and drug development professionals in overcoming the challenges of M-mode echocardiography interpretation in patients with complex congenital heart disease (CHD).

### Troubleshooting Guide

This guide addresses specific issues you may encounter during M-mode acquisition and interpretation in patients with complex CHD.

Question	Answer
Q1: I am unable to obtain a standard parasternal long-axis view for M-mode measurements of the left ventricle. What should I do?	<p>In complex CHD, cardiac position and orientation are often abnormal. Do not rely on standard views alone. Use 2D echocardiography to identify the ventricular chambers and guide your M-mode cursor placement. The key is to ensure the cursor is perpendicular to the maximal diastolic dimension of the ventricle you intend to measure, regardless of the transducer position.</p> <p><a href="#">[1]</a><a href="#">[2]</a></p>
Q2: The M-mode tracing of the interventricular septum shows paradoxical motion (moves away from the left ventricular posterior wall during systole). How do I interpret this?	<p>Paradoxical septal motion is a common finding in conditions with right ventricular (RV) pressure or volume overload, such as in patients with a systemic RV (e.g., after an atrial switch operation for d-TGA) or significant pulmonary regurgitation (e.g., repaired Tetralogy of Fallot).</p> <p><a href="#">[3]</a> This finding reflects the altered interventricular dynamics and does not necessarily indicate intrinsic septal dysfunction. It is crucial to correlate this with the underlying anatomy and physiology.</p>
Q3: I am trying to assess right ventricular function using Tricuspid Annular Plane Systolic Excursion (TAPSE), but the values seem inconsistent. Why is this happening?	<p>TAPSE can be unreliable in complex CHD for several reasons. The complex geometry of the RV and its retrosternal position can make consistent M-mode cursor alignment on the lateral tricuspid annulus challenging.<a href="#">[4]</a></p> <p>Additionally, in cases of significant tricuspid regurgitation, TAPSE can be pseudo-normalized.<a href="#">[4]</a> Consider using multiple RV-focused views and be aware that TAPSE is load- and angle-dependent.</p>
Q4: My M-mode image is cluttered with bright, linear echoes, making it difficult to identify the	<p>These are likely reverberation artifacts, which occur when the ultrasound beam bounces between two strong reflectors. To mitigate this,</p>

endocardial borders. What are these and how can I reduce them?

try changing the transducer's angle of insonation, adjusting the time gain compensation (TGC) to reduce near-field gain, and using different acoustic windows.

Q5: I see a duplicate image of a valve or a vessel on my M-mode tracing. Is this a true anatomical abnormality?

This is likely a refraction artifact, also known as a "lens effect," where the ultrasound beam is bent as it passes through tissues of different densities, creating a duplicate image. These artifacts often create anatomically implausible images. Changing the imaging window or adjusting the transducer angle can help resolve this and confirm it is an artifact.

Q6: When assessing a single ventricle, especially after a Fontan procedure, how should I position the M-mode cursor for functional assessment?

Assessing a single ventricle with M-mode is challenging due to its often-abnormal morphology and the absence of a distinct septum for reference. M-mode is of limited value for assessing global function in these patients. However, you can use it to assess atrioventricular valve inflow and wall motion in specific segments identified on 2D imaging. For diastolic function, color M-mode can be used to measure inflow propagation velocity.

## Frequently Asked Questions (FAQs)

### General M-mode Challenges in Complex CHD

- Q: Why is M-mode interpretation so challenging in complex congenital heart disease? A: M-mode relies on standardized views and assumes normal cardiac anatomy and geometry for accurate measurements. In complex CHD, the heart's position, the orientation of chambers and great vessels, and the ventricular morphology are often significantly altered, making standard M-mode cursor placement difficult or impossible. This can lead to inaccurate and misleading measurements.
- Q: What are the primary limitations of M-mode in this patient population? A: The main limitations include:

- Geometric Assumptions: M-mode calculations of ventricular function (like ejection fraction) are based on geometric assumptions that are often invalid in abnormally shaped ventricles.
- "Ice-pick" View: M-mode provides a one-dimensional view of the heart, which can miss regional wall motion abnormalities and complex three-dimensional anatomy.
- Angle Dependence: Accurate measurements require the M-mode beam to be perpendicular to the structure of interest, which can be difficult to achieve in a malpositioned heart.
- Q: When is M-mode still considered useful in complex CHD? A: Despite its limitations, M-mode remains valuable for:
  - High Temporal Resolution: Its high sampling rate is excellent for assessing the timing of cardiac events and the motion of rapidly moving structures like valve leaflets.
  - Wall Thickness and Chamber Dimensions: When guided by 2D imaging to ensure perpendicularity, M-mode can provide accurate measurements of wall thickness and chamber dimensions in specific regions.
  - Assessment of Specific Parameters: It is used for specific measurements like TAPSE for RV function and mitral annular plane systolic excursion (MAPSE) for LV longitudinal function.

### Specific Congenital Heart Defects

- Q: What are the key M-mode challenges in a patient with repaired Tetralogy of Fallot? A: In repaired Tetralogy of Fallot, the right ventricle is often dilated and hypertrophied due to chronic pulmonary regurgitation. This altered RV geometry makes standard M-mode assessment of RV size and function difficult. Paradoxical septal motion is also common.
- Q: How is M-mode used to assess the systemic right ventricle in a patient with d-TGA after an atrial switch operation (e.g., Mustard or Senning procedure)? A: M-mode can be used to assess the wall thickness and dimensions of the systemic RV. However, conventional M-mode calculations of ejection fraction are inaccurate due to the RV's crescent shape. Paradoxical septal motion is an expected finding. Assessment of the systemic RV often

requires a multi-modality approach, with cardiac MRI being the gold standard for volumetric and functional assessment.

- Q: What are the limitations of M-mode in patients with a Fontan circulation? A: In a Fontan circulation, the systemic ventricle is often volume-unloaded, and its function can be influenced by the passive pulmonary blood flow. M-mode has significant limitations in assessing global ventricular function in this setting. It can be used to assess atrioventricular valve function and to look for signs of ventricular dysfunction, but a comprehensive assessment usually requires other imaging modalities.

## Data Presentation

Table 1: Comparison of M-mode and 2D Echocardiography for Ventricular Assessment

Parameter	M-mode	2D Echocardiography	Key Considerations in Complex CHD
Left Ventricular (LV) Dimensions	High reproducibility in intra- and inter-reader settings.	Good reproducibility, especially in the inter-acquisition setting.	Inaccurate if standard views are unobtainable. 2D guidance is crucial for correct cursor placement.
LV Shortening Fraction (SF)	Greater reproducibility than 2D-derived SF.	Lower reproducibility compared to M-mode SF.	Highly dependent on ventricular geometry; may not reflect global function in abnormally shaped ventricles.
Right Ventricular (RV) Function (TAPSE)	Simple and reproducible in normal hearts.	Not directly measured; relies on parameters like Fractional Area Change (FAC).	Often unreliable due to complex RV geometry, angle dependency, and load conditions.
LV Mass	Correlates well with 2D methods but can be inaccurate with abnormal geometry.	Biplane Simpson and truncated ellipsoid methods are common.	Both methods are prone to error in complex CHD due to non-standard ventricular shapes.
Inter-observer Reproducibility (Fetal Ventricular Wall Thickness)	Acceptable for LV free-wall and septum. Poor for RV free-wall.	Acceptable for LV free-wall and septum. Poor for RV free-wall.	Highlights the inherent difficulty in assessing the RV, even in fetal life.

## Experimental Protocols

Detailed Methodology for M-mode Assessment of Ventricular Dimensions and Function

This protocol outlines a standardized approach to M-mode imaging in patients with complex CHD, emphasizing the importance of 2D guidance.

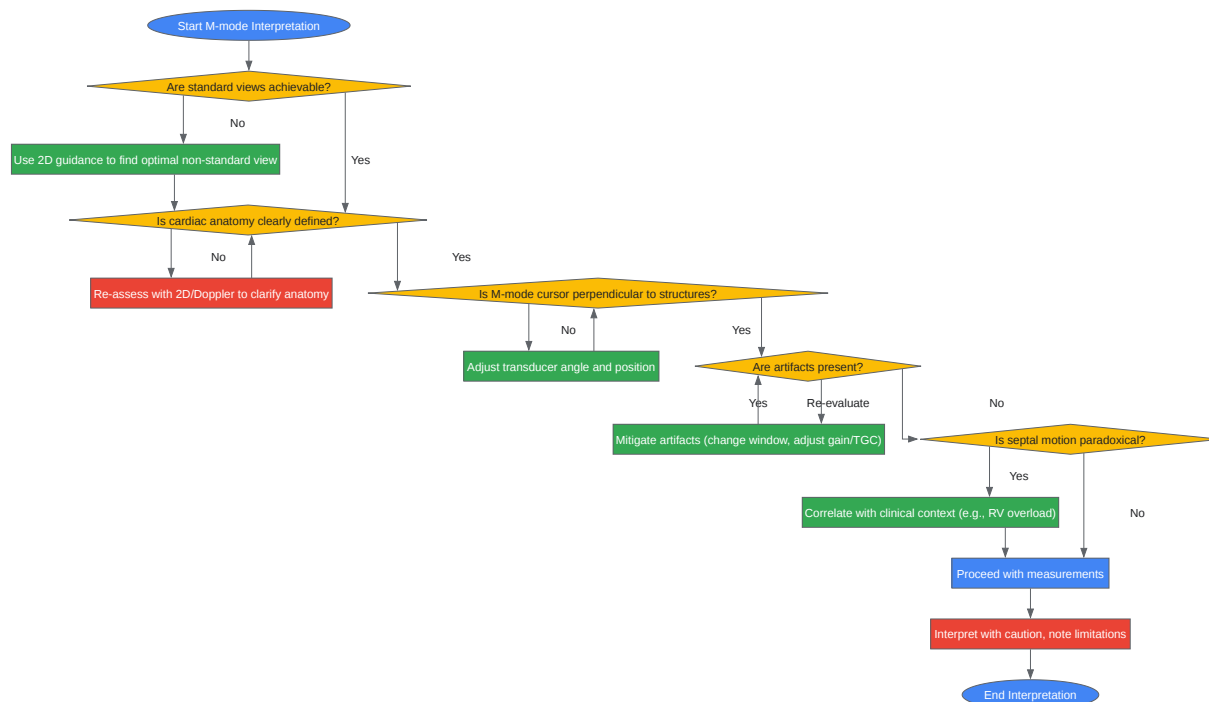
- Patient Preparation and Positioning:
  - Ensure the patient is in a stable and comfortable position, typically the left lateral decubitus position, to optimize acoustic windows.
  - For pediatric patients, ensure a calm environment to minimize motion artifacts. Sedation may be necessary in some cases.
  - Attach a 3-lead ECG to the monitor for accurate timing of cardiac events.
- 2D-Guided M-mode Acquisition:
  - Initial 2D Survey: Perform a comprehensive 2D echocardiographic examination to delineate the cardiac anatomy, including the position and morphology of the ventricles, the location of the great vessels, and the presence of any septal defects.
  - Ventricular Identification: Clearly identify the systemic and pulmonary ventricles based on their morphological features (e.g., trabeculations, atrioventricular valve morphology).
  - Optimal M-mode Cursor Placement:
    - From the 2D view that best visualizes the ventricle of interest in its long axis, activate the M-mode cursor.
    - Position the cursor perpendicular to the interventricular septum (if present and in a relatively normal position) and the ventricular posterior wall, just distal to the atrioventricular valve leaflets.
    - In cases of abnormal anatomy, orient the cursor to be perpendicular to the major axis of the ventricle at its widest point.
    - Activate the M-mode sweep.
  - Image Optimization:

- Adjust the gain and TGC to clearly define the endocardial borders.
- Use a high sweep speed (50-100 mm/s) to better visualize wall motion and allow for more accurate measurements.
- M-mode Measurements:
  - Timing of Measurements:
    - End-diastole: Measure at the onset of the QRS complex on the ECG.
    - End-systole: Measure at the point of maximal posterior motion of the septum or minimal ventricular dimension.
  - Standard Measurements (when applicable):
    - Interventricular septal thickness in diastole (IVSd)
    - Left ventricular internal dimension in diastole (LVIDd)
    - Left ventricular posterior wall thickness in diastole (LVPWd)
    - Left ventricular internal dimension in systole (LVIDs)
  - Derived Calculations:
    - Fractional Shortening (FS %) =  $[(LVIDd - LVIDs) / LVIDd] \times 100$
    - Ejection Fraction (EF %) can be estimated using various formulas (e.g., Teichholz), but be aware of their limitations in non-ellipsoidal ventricles.
  - Right Ventricular Assessment:
    - For TAPSE, obtain an apical four-chamber view focused on the RV. Place the M-mode cursor through the lateral tricuspid annulus and measure the total systolic excursion.
- Data Recording and Interpretation:
  - Save representative M-mode loops for offline analysis.



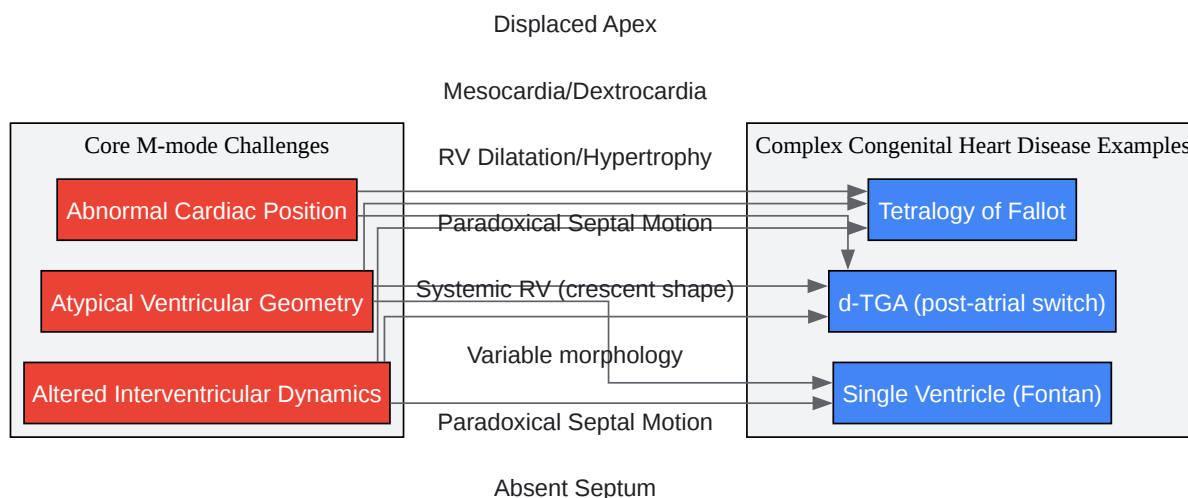
- Always interpret M-mode findings in the context of the 2D and Doppler findings, as well as the patient's specific diagnosis and surgical history.
- Clearly document the views used and any deviations from standard M-mode acquisition techniques due to the underlying anatomy.

## Mandatory Visualization



[Click to download full resolution via product page](#)

Caption: Troubleshooting workflow for M-mode interpretation in complex CHD.



[Click to download full resolution via product page](#)

Caption: Relationship between core M-mode challenges and specific complex CHDs.

### Need Custom Synthesis?

BenchChem offers custom synthesis for rare earth carbides and specific isotopic labeling.

Email: [info@benchchem.com](mailto:info@benchchem.com) or [Request Quote Online](#).

## References

- 1. [ecgwaves.com](http://ecgwaves.com) [[ecgwaves.com](http://ecgwaves.com)]
- 2. [researchgate.net](http://researchgate.net) [[researchgate.net](http://researchgate.net)]
- 3. [youtube.com](http://youtube.com) [[youtube.com](http://youtube.com)]
- 4. Assessment of Right Ventricular Function—a State of the Art - PMC [[pmc.ncbi.nlm.nih.gov](http://pmc.ncbi.nlm.nih.gov)]
- To cite this document: BenchChem. [Challenges in M-mode interpretation in patients with complex congenital heart disease]. BenchChem, [2025]. [Online PDF]. Available at:

[<https://www.benchchem.com/product/b15144752#challenges-in-m-mode-interpretation-in-patients-with-complex-congenital-heart-disease>]

---

#### Disclaimer & Data Validity:

The information provided in this document is for Research Use Only (RUO) and is strictly not intended for diagnostic or therapeutic procedures. While BenchChem strives to provide accurate protocols, we make no warranties, express or implied, regarding the fitness of this product for every specific experimental setup.

**Technical Support:** The protocols provided are for reference purposes. Unsure if this reagent suits your experiment? [[Contact our Ph.D. Support Team for a compatibility check](#)]

**Need Industrial/Bulk Grade?** [Request Custom Synthesis Quote](#)

## BenchChem

Our mission is to be the trusted global source of essential and advanced chemicals, empowering scientists and researchers to drive progress in science and industry.

#### Contact

Address: 3281 E Guasti Rd  
Ontario, CA 91761, United States  
Phone: (601) 213-4426  
Email: [info@benchchem.com](mailto:info@benchchem.com)