

Ceretec vs. Newer Imaging Modalities: A Comparative Guide for Neuroimaging in Research

Author: BenchChem Technical Support Team. **Date:** December 2025

Compound of Interest

Compound Name: Ceretec

Cat. No.: B1204290

[Get Quote](#)

For Researchers, Scientists, and Drug Development Professionals

This guide provides an objective comparison of **Ceretec**[™] (Technetium-99m exametazime) Single Photon Emission Computed Tomography (SPECT) with newer neuroimaging modalities, including Positron Emission Tomography (PET) with various tracers and Arterial Spin Labeling (ASL) Magnetic Resonance Imaging (MRI). We will delve into the limitations of **Ceretec** and highlight the advancements offered by these alternative techniques, supported by experimental data.

Executive Summary

Ceretec SPECT has long been a valuable tool for assessing regional cerebral blood flow (rCBF), providing insights into brain function in various neurological disorders. However, newer imaging modalities have emerged with significant advantages in terms of resolution, quantification, and specificity for particular molecular pathologies. For researchers and drug development professionals, understanding the nuanced capabilities of each technique is crucial for selecting the most appropriate tool for preclinical and clinical studies. This guide will explore these differences through quantitative data, detailed experimental protocols, and visual representations of the underlying principles and workflows.

Quantitative Data Comparison

The following tables summarize key performance metrics for **Ceretec** SPECT compared to FDG-PET, Amyloid PET, and ASL-MRI. Data is compiled from various studies to provide a comparative overview.

Modality	Parameter	Ceretec (99mTc- HMPAO) SPECT	FDG-PET	Amyloid PET	Arterial Spin Labeling (ASL) MRI
Primary Measurement	Physiological Process	Regional Cerebral Blood Flow (rCBF)	Regional Cerebral Glucose Metabolism	Amyloid- β Plaque Density	Regional Cerebral Blood Flow (rCBF)
Spatial Resolution	Typical Value	~10-12 mm	~4-6 mm	~4-6 mm	~3-4 mm in- plane, 4-8 mm through- plane
Temporal Resolution	Imaging Time	20-40 minutes acquisition	15-30 minutes acquisition	10-20 minutes acquisition	4-10 minutes acquisition
Quantification	Accuracy	Semi- quantitative	Quantitative (SUV)	Quantitative (SUVR, Centiloid)	Quantitative (ml/100g/min)
Radiation Exposure	Nature	Ionizing (gamma emitter)	Ionizing (positron emitter)	Ionizing (positron emitter)	Non-ionizing

Table 1: General Performance Characteristics of Neuroimaging Modalities

Parameter	Ceretec (99mTc-HMPAO) SPECT	FDG-PET	Amyloid PET
Sensitivity for Alzheimer's Disease	65-85% [1]	75-99% [1]	>90% (compared to post-mortem diagnosis) [2]
Specificity for Alzheimer's Disease	72-87% (for other neurodegenerative dementias) [1]	71-93% [1]	>90% (compared to post-mortem diagnosis) [2]
Diagnostic Accuracy (AUC)	0.61 - 0.79 [3] [4]	0.71 - 0.81 [3] [4]	High, but a positive scan is not a direct diagnosis of AD [5]

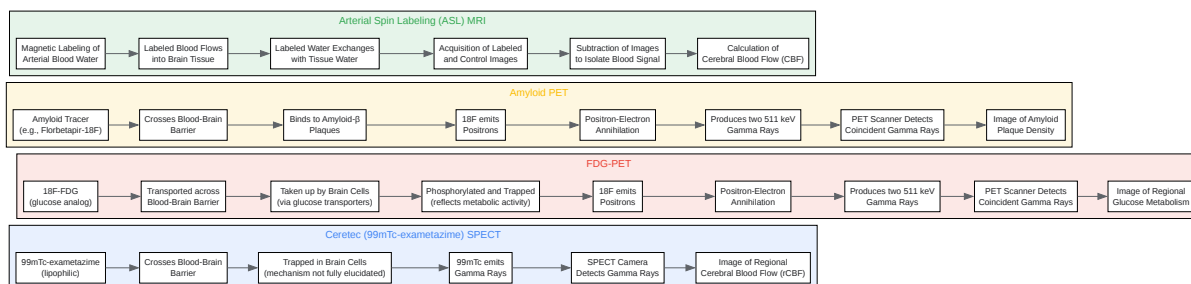
Table 2: Diagnostic Performance in Alzheimer's Disease

Parameter	Ceretec (99mTc-HMPAO) SPECT	Arterial Spin Labeling (ASL) MRI	15O-H2O PET (Gold Standard for CBF)
Gray/White Matter CBF Ratio	2.44 ± 0.18 [6]	2.47 ± 0.39 [6]	N/A
Global CBF (ml/100g/min)	Semi-quantitative	47.70 ± 9.75 [7]	40.6 ± 4.1 [8]

Table 3: Cerebral Blood Flow (CBF) Measurement Comparison

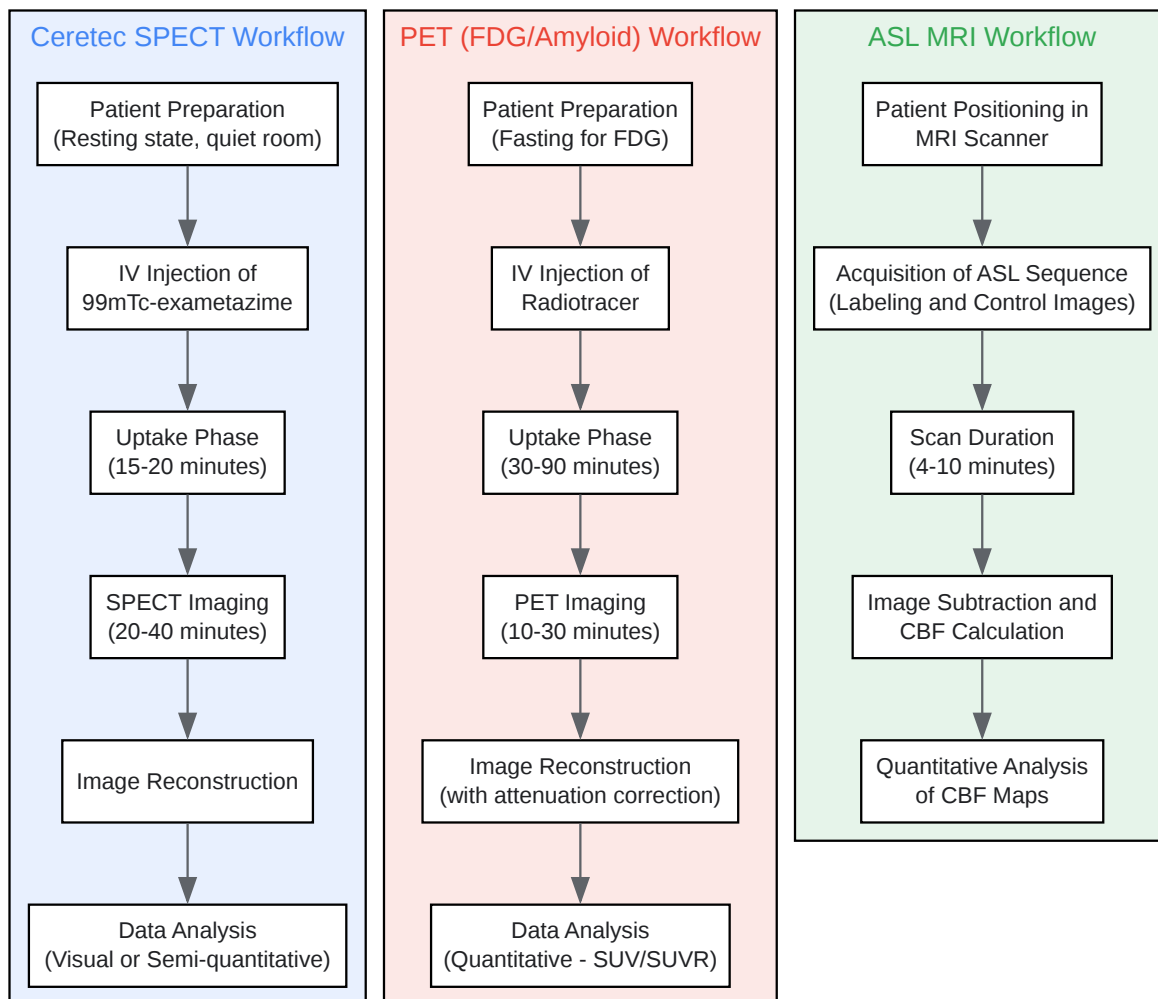
Physiological Principles and Imaging Workflows

The following diagrams illustrate the fundamental principles behind each imaging modality and their respective experimental workflows.



[Click to download full resolution via product page](#)

Caption: Physiological principles of different neuroimaging modalities.



[Click to download full resolution via product page](#)

Caption: Generalized experimental workflows for neuroimaging.

Detailed Methodologies

Ceretec (99mTc-exametazime) SPECT Protocol

- **Patient Preparation:** The patient should rest in a quiet, dimly lit room for at least 15 minutes prior to injection to establish a baseline cerebral blood flow state.[9] An intravenous line is placed.[9]
- **Radiopharmaceutical Preparation and Injection:** Aseptically reconstitute the **Ceretec** kit with Technetium-99m pertechnetate. The recommended adult dose is 370-1110 MBq (10-30 mCi) administered intravenously.[10][11]
- **Uptake Phase:** Following injection, there is a waiting period of approximately 15-20 minutes to allow for the tracer to distribute and become trapped in the brain.[9][11]
- **Image Acquisition:** The patient is positioned supine on the scanner bed with their head in a holder.[9] SPECT images are acquired for 20-40 minutes using a gamma camera equipped with a high-resolution collimator.[9][12]
- **Image Reconstruction and Analysis:** The acquired projection data is reconstructed into transverse, sagittal, and coronal slices. Analysis is typically qualitative (visual inspection of perfusion patterns) or semi-quantitative, comparing regional counts to a reference region like the cerebellum.

FDG-PET Protocol for Dementia Diagnosis

- **Patient Preparation:** Patients are required to fast for at least 4-6 hours to ensure stable blood glucose levels. Blood glucose should be checked prior to tracer injection and should ideally be below 200 mg/dL.[13] The patient rests in a quiet, dimly lit room for at least 30 minutes before and during the uptake phase to minimize sensory and cognitive stimulation.[13]
- **Radiopharmaceutical Injection:** An intravenous injection of 18F-Fluorodeoxyglucose (FDG) is administered.
- **Uptake Phase:** There is a 30-60 minute uptake period during which the FDG is taken up by brain cells.[13]
- **Image Acquisition:** The patient is positioned in the PET scanner, and images of the brain are acquired for 15-30 minutes.[13]

- Image Reconstruction and Analysis: Images are reconstructed with attenuation correction, often using a co-registered CT scan. Analysis is quantitative, typically using Standardized Uptake Value (SUV) calculations to identify regions of hypometabolism.[10][14]

Amyloid PET Protocol

- Patient Preparation: No specific preparation such as fasting is required.[15]
- Radiopharmaceutical Injection: An intravenous injection of an amyloid-targeting radiotracer (e.g., Florbetapir-18F, Flutemetamol-18F, or Florbetaben-18F) is administered.[15]
- Uptake Phase: The uptake period varies depending on the tracer, typically ranging from 30 to 90 minutes.[15][16]
- Image Acquisition: A PET scan of the brain is performed for 10-20 minutes.[16]
- Image Reconstruction and Analysis: Images are reconstructed, and analysis involves visual assessment of gray matter uptake compared to white matter.[16] Quantitative analysis is also performed using the Standardized Uptake Value Ratio (SUVR), often with the cerebellum as a reference region, to determine the extent of amyloid plaque deposition.[16]

Arterial Spin Labeling (ASL) MRI Protocol

- Patient Preparation: No specific patient preparation is required. The patient is positioned in the MRI scanner.
- Image Acquisition: ASL is an MRI technique that uses magnetically labeled arterial blood water as an endogenous tracer.[17] A series of "labeled" images (where the arterial blood is magnetically inverted) and "control" images (without labeling) are acquired.[17] The recommended technique is pseudo-continuous ASL (pCASL) with background suppression and a 3D readout.[18]
- Post-Labeling Delay (PLD): A crucial parameter is the post-labeling delay, which is the time between labeling and image acquisition, allowing the labeled blood to reach the brain tissue. A typical PLD is around 1.5 to 2.5 seconds.[19]
- Image Processing and Analysis: The labeled and control images are subtracted to create a perfusion-weighted image.[17] From this, quantitative cerebral blood flow maps (in

ml/100g/min) are calculated using a kinetic model.[20]

Limitations of Ceretec and Advantages of Newer Modalities

Ceretec (99mTc-exametazime) SPECT

- **Lower Spatial Resolution:** SPECT imaging has inherently lower spatial resolution compared to PET and MRI, which can limit the detection of small or subtle changes in cerebral blood flow.
- **Semi-Quantitative Nature:** While relative changes in rCBF can be assessed, absolute quantification is challenging with SPECT, making it less precise for longitudinal studies monitoring treatment effects.
- **Lack of Pathological Specificity:** **Ceretec** measures blood flow, which is an indirect marker of neuronal activity. It does not provide information about specific molecular pathologies, such as amyloid plaques or tau tangles, which are hallmarks of diseases like Alzheimer's.[5]
- **Radiation Exposure:** As a nuclear medicine technique, SPECT involves the administration of a radioactive tracer, which results in radiation exposure to the patient.

Advantages of Newer Modalities

- **FDG-PET:**
 - **Higher Resolution and Better Quantification:** PET offers superior spatial resolution and more accurate quantification of cerebral glucose metabolism compared to SPECT.
 - **Direct Measure of Neuronal Function:** Glucose metabolism is more directly coupled to synaptic activity than blood flow, potentially offering a more sensitive marker of neuronal dysfunction.
- **Amyloid PET:**
 - **Pathological Specificity:** This technique allows for the in-vivo detection and quantification of amyloid- β plaques, a core pathology of Alzheimer's disease.[5] This is a significant

advantage for patient stratification and for assessing the efficacy of anti-amyloid therapies.

- Arterial Spin Labeling (ASL) MRI:
 - Non-Invasive: ASL does not require the injection of a contrast agent or radioactive tracer, making it a safer option for repeated measurements, especially in vulnerable populations. [\[17\]](#)
 - High Resolution and Quantification: ASL provides high-resolution, quantitative maps of cerebral blood flow.
 - Integration with other MRI sequences: ASL can be easily integrated into a standard MRI protocol, providing both structural and functional information in a single imaging session.

Conclusion

While **Ceretec** SPECT has been a foundational tool in neuroimaging, its limitations in resolution, quantification, and specificity are addressed by newer modalities. For researchers and drug development professionals, FDG-PET offers a more sensitive and quantitative assessment of neuronal function. Amyloid PET provides invaluable information on specific disease pathology, crucial for targeted drug development. ASL-MRI emerges as a powerful, non-invasive alternative for quantitative cerebral blood flow measurement with high resolution. The choice of imaging modality should be guided by the specific research question, the need for quantitative data, and the desired level of pathological specificity.

Need Custom Synthesis?

BenchChem offers custom synthesis for rare earth carbides and specific isotopic labeling.

Email: info@benchchem.com or [Request Quote Online](#).

References

- 1. A comparison of FDG-PET and blood flow SPECT in the diagnosis of neurodegenerative dementias: a systematic review - PubMed [pubmed.ncbi.nlm.nih.gov]
- 2. youtube.com [youtube.com]
- 3. researchgate.net [researchgate.net]

- 4. Support vector machine-based classification of neuroimages in Alzheimer's disease: direct comparison of FDG-PET, rCBF-SPECT and MRI data acquired from the same individuals - PMC [pmc.ncbi.nlm.nih.gov]
- 5. jnm.snmjournals.org [jnm.snmjournals.org]
- 6. Comparison of relative CBF maps using pseudo-continuous ASL and SPECT - PMC [pmc.ncbi.nlm.nih.gov]
- 7. Comparison of non-invasive MRI measurements of cerebral blood flow in a large multisite cohort - PMC [pmc.ncbi.nlm.nih.gov]
- 8. researchgate.net [researchgate.net]
- 9. radiology.unm.edu [radiology.unm.edu]
- 10. mahidol.elsevierpure.com [mahidol.elsevierpure.com]
- 11. snmmi.org [snmmi.org]
- 12. radiologysa.com.au [radiologysa.com.au]
- 13. tech.snmjournals.org [tech.snmjournals.org]
- 14. Brain [F-18]FDG PET for Clinical Dementia Workup: Differential Diagnosis of Alzheimer's Disease and Other Types of Dementing Disorders - PubMed [pubmed.ncbi.nlm.nih.gov]
- 15. Amyloid Brain PET-CT for Alzheimer's Disease Services - NYC & Westchester | ColumbiaDoctors - New York | ColumbiaDoctors [columbiadoctors.org]
- 16. mdpi.com [mdpi.com]
- 17. radiopaedia.org [radiopaedia.org]
- 18. mriquestions.com [mriquestions.com]
- 19. Head-to-Head Visual Comparison between Brain Perfusion SPECT and Arterial Spin-Labeling MRI with Different Postlabeling Delays in Alzheimer Disease - PMC [pmc.ncbi.nlm.nih.gov]
- 20. mri-q.com [mri-q.com]
- To cite this document: BenchChem. [Ceretec vs. Newer Imaging Modalities: A Comparative Guide for Neuroimaging in Research]. BenchChem, [2025]. [Online PDF]. Available at: [https://www.benchchem.com/product/b1204290#limitations-of-ceretec-compared-to-newer-imaging-modalities]

Disclaimer & Data Validity:

The information provided in this document is for Research Use Only (RUO) and is strictly not intended for diagnostic or therapeutic procedures. While BenchChem strives to provide accurate protocols, we make no warranties, express or implied, regarding the fitness of this product for every specific experimental setup.

Technical Support: The protocols provided are for reference purposes. Unsure if this reagent suits your experiment? [[Contact our Ph.D. Support Team for a compatibility check](#)]

Need Industrial/Bulk Grade? [Request Custom Synthesis Quote](#)

BenchChem

Our mission is to be the trusted global source of essential and advanced chemicals, empowering scientists and researchers to drive progress in science and industry.

Contact

Address: 3281 E Guasti Rd

Ontario, CA 91761, United States

Phone: (601) 213-4426

Email: info@benchchem.com