

BF-227 PET Image Interpretation Technical Support Center

Author: BenchChem Technical Support Team. **Date:** December 2025

Compound of Interest

Compound Name: BF 227

Cat. No.: B15617340

[Get Quote](#)

This technical support center provides troubleshooting guides and frequently asked questions (FAQs) to address common challenges encountered during the interpretation of BF-227 PET images. The information is tailored for researchers, scientists, and drug development professionals.

FAQs & Troubleshooting Guides

Image Quality and Artifacts

Question 1: What are common artifacts in BF-227 PET imaging and how can they be identified?

Answer: Similar to other PET/CT imaging, BF-227 PET images can be affected by several artifacts. Recognition of these is crucial to avoid misinterpretation. Common artifacts include:

- **Attenuation Correction (AC) Artifacts:** These are among the most frequent artifacts in PET/CT. They can arise from high-density materials like metallic implants or contrast agents, leading to artificially high or low tracer uptake signals.^[1]
- **Motion Artifacts:** Patient movement during the scan can cause blurring and misregistration between the PET and CT images, leading to inaccurate localization of tracer uptake.^[2]
- **Truncation Artifacts:** This occurs when the CT field of view (FOV) is smaller than the PET FOV, typically in larger patients. The periphery of the PET image will lack corresponding CT

data for accurate attenuation correction, potentially leading to over- or underestimation of BF-227 uptake.[3]

- **Beam-Hardening Artifacts:** These appear as linear bands of abnormal attenuation near high-density objects like bone or metal, which can affect the accuracy of the PET data.[3]

Troubleshooting:

- **Review the CT scan:** Carefully inspect the CT images for the presence of metallic implants, dense oral or intravenous contrast, and motion.
- **Compare with non-attenuation-corrected (NAC) images:** If available, comparing the AC images with NAC images can help identify artifacts caused by the attenuation correction process.[1]
- **Patient positioning:** Ensure patients are positioned comfortably and with arms up or down to minimize truncation and beam-hardening artifacts.[3]
- **Pre-scan instructions:** Advise patients to remain as still as possible during the scan. Consider head restraints for brain imaging.

Question 2: My BF-227 PET image shows high uptake in the skull. Is this a pathological finding?

Answer: High uptake of BF-227 in the skull is a known potential artifact and may not necessarily represent a pathological finding. This can be due to non-specific binding of the tracer.[4] Misregistration of this skull uptake during anatomical standardization can lead to it being included within the brain area in the final processed images, resulting in erroneously high Z-scores at the periphery of the brain.[5]

Troubleshooting:

- **Visual Inspection:** Carefully examine the raw and anatomically standardized PET images to see if the high uptake corresponds to the skull.
- **Scalping:** In voxel-based analysis, a "scalping" procedure to remove radioactivity outside of the brain can be performed to mitigate the effects of skull uptake on the analysis results.[5]

- Review Anatomical Standardization: Check the accuracy of the anatomical standardization process to ensure that extra-cerebral tissues are not being included in the brain mask.[5]

Image Analysis and Quantification

Question 3: I am using 3D-SSP for BF-227 PET image analysis and observing paradoxical results. What could be the cause?

Answer: Three-dimensional stereotactic surface projection (3D-SSP) analysis can sometimes produce paradoxical results with amyloid PET imaging, including with BF-227. A primary cause is errors in the anatomical standardization (AS) process, especially when using a standard ^{18}F -FDG template for BF-227 images.[6] This can lead to image distortions.[6]

Troubleshooting: A modified 3D-SSP analysis method has been developed to address this issue.[6] The key difference is in the anatomical standardization step. Instead of directly applying the FDG template to the BF-227 image, the patient's own FDG-PET scan is first standardized, and then the transformation parameters from that process are applied to the co-registered BF-227 image.[6] This method has been shown to correct for AS errors.[6]

Experimental Protocol: Modified 3D-SSP Analysis for BF-227 PET[6]

- Image Acquisition: Acquire both ^{18}F -FDG and $[^{11}\text{C}]\text{BF-227}$ PET scans for the same subject.
- Anatomical Standardization of FDG Image: Perform anatomical standardization on the FDG-PET image using a standard FDG template (e.g., using Neurostat software).
- Co-registration: Co-register the subject's BF-227 PET image to their own FDG-PET image.
- Apply Transformation Parameters: Apply the transformation parameters calculated from the FDG image standardization (Step 2) to the co-registered BF-227 image.
- Normalization and Calculation: Normalize regional values using the average value from a reference region like the cerebellum. Calculate values for specific regions of interest (e.g., frontal, parietal, temporal, and occipital lobes).[6]

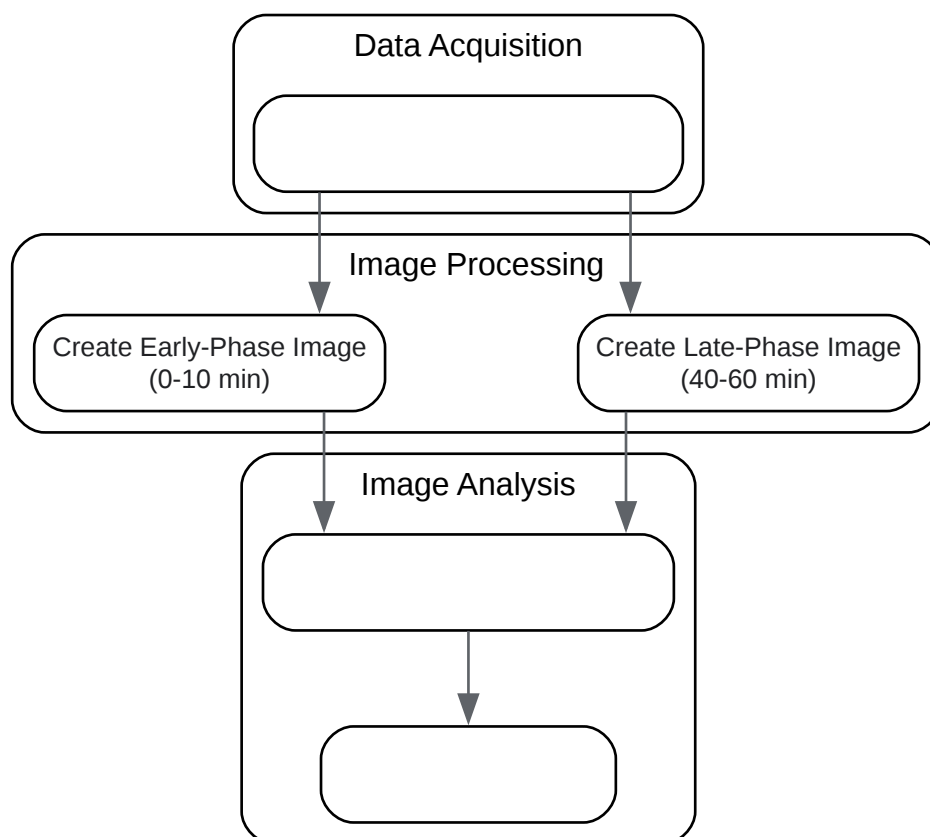
Question 4: How can I improve the anatomical standardization of my late-phase BF-227 PET images?

Answer: A useful technique is to utilize the early-phase BF-227 PET data. The early-phase images (e.g., 0-10 minutes post-injection) can provide perfusion-like information.^{[7][8]} These early-phase images can be used for the anatomical standardization of the late-phase (e.g., 40-60 minutes post-injection) amyloid imaging data.^{[7][8]} This method has been shown to be successful for anatomical standardization in all cases in one study and enables appropriate 3D-SSP analyses.^[7]

Experimental Protocol: Early-Phase BF-227 for Anatomical Standardization^{[7][8]}

- **Dynamic Acquisition:** Acquire dynamic PET data from the time of [¹¹C]BF-227 injection.
- **Image Summation:** Create an early-phase summed image from the first 10 minutes of data and a late-phase summed image from 40-60 minutes post-injection.
- **Anatomical Standardization:** Perform anatomical standardization on the late-phase BF-227 image using the corresponding early-phase BF-227 image as the reference for transformation.
- **Voxel-Based Analysis:** Proceed with 3D-SSP or other voxel-based analyses on the correctly standardized late-phase images.

Logical Workflow for Improved Anatomical Standardization of BF-227 PET Images



[Click to download full resolution via product page](#)

Caption: Workflow for using early-phase BF-227 PET data for anatomical standardization.

Tracer-Specific Issues

Question 5: I am investigating synucleinopathies. Is BF-227 a suitable tracer for imaging alpha-synuclein?

Answer: Current evidence suggests that BF-227 is not a suitable tracer for imaging alpha-synuclein aggregates. In vitro autoradiography studies on postmortem brain tissue from patients with Multiple System Atrophy (MSA), a synucleinopathy, showed no specific binding of [^{18}F]BF-227 to cytoplasmic glial inclusions (CGI), which are composed of aggregated alpha-synuclein.[9] While one initial PET study suggested BF-227 might be useful for monitoring intracellular alpha-synuclein deposition in MSA, subsequent autoradiography did not support significant binding at concentrations typically achieved in PET experiments.[9] Any observed PET signal differences in MSA patients are therefore unlikely to be related to direct binding to alpha-synuclein.[9]

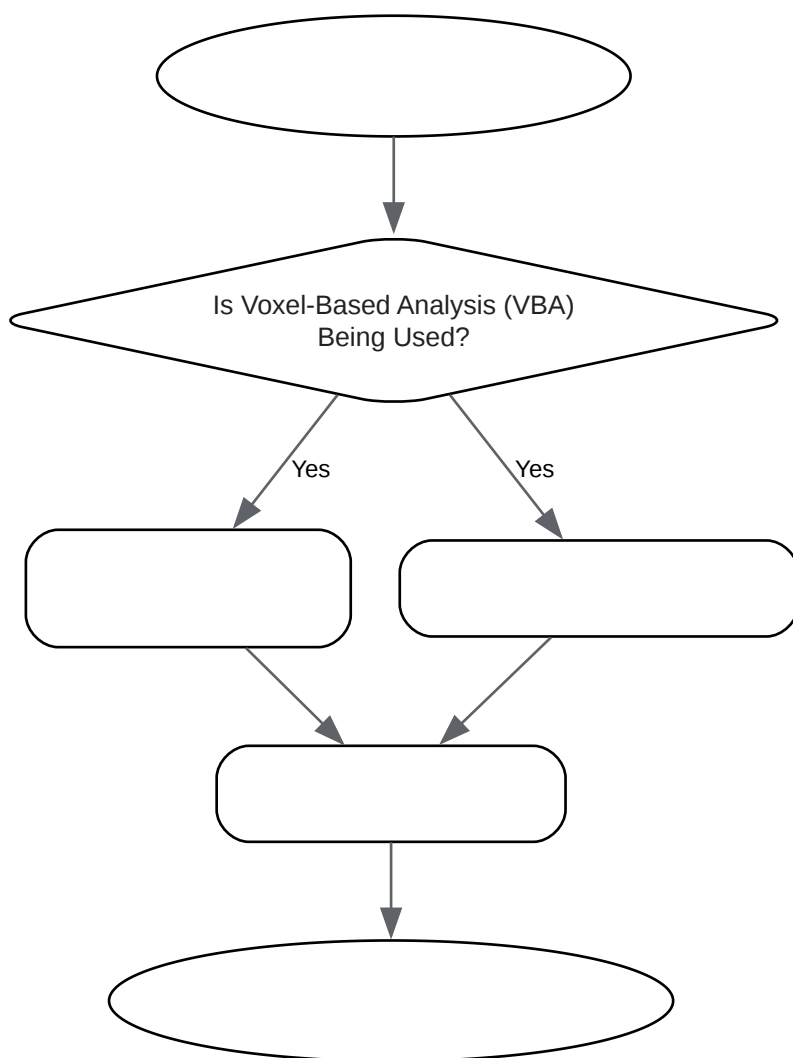
Question 6: My BF-227 PET images show high white matter retention. Is this expected and how does it affect interpretation?

Answer: Yes, high retention of BF-227 in the white matter has been observed.^[8] This non-specific binding can complicate image interpretation, particularly when using voxel-based analysis methods like 3D-SSP.^[4] Diffuse, non-specific uptake in the white matter that is higher than cortical uptake can lead to discrepancies in the results of different analysis methods.^[4]

Troubleshooting:

- **Choice of Analysis Method:** Be aware that different voxel-based analysis methods (e.g., 3D-SSP and SPM) may be affected differently by high white matter uptake. It may be beneficial to use more than one analysis method and compare the results.^[4]
- **Region of Interest (ROI) Analysis:** In addition to voxel-based methods, consider using ROI-based analysis with carefully defined cortical regions to minimize the influence of white matter uptake.
- **Reference Region Selection:** Ensure the chosen reference region (e.g., cerebellum) is not unduly affected by non-specific binding.

Troubleshooting Logic for High White Matter Signal



[Click to download full resolution via product page](#)

Caption: Decision-making process for addressing high white matter uptake in BF-227 PET.

Quantitative Data Summary

Table 1: Comparison of BF-227 Uptake in Different Patient Cohorts

Brain Region	Alzheimer's Disease (AD) vs. Normal Control (NC)	Mild Cognitive Impairment (MCI) vs. Normal Control (NC)	Mild Cognitive Impairment (MCI) vs. Alzheimer's Disease (AD)	Reference
Neocortical Areas	Increased uptake in AD	Increased uptake in MCI	No significant difference	[10]
Striatum	Increased uptake in AD	Not specified	Not specified	
Parietal Lobe	Significantly higher in AD	Significantly higher in MCI	Most significant difference between MCI and other groups observed here	[10]
Temporal Lobe	Significantly higher in AD	Significantly higher in MCI	Not specified	[6]
Occipital Lobe	Significantly higher in AD	Significantly higher in MCI	Not specified	[6]
Frontal Lobe	Significant difference shown with modified 3D-SSP	Significant difference shown with modified 3D-SSP	Not specified	[6]

Table 2: Diagnostic Performance of BF-227 PET vs. FDG-PET for Differentiating AD from Normal Controls

Imaging Modality	Sensitivity	Specificity	Reference
[¹¹ C]BF-227-PET	Higher	Higher	[10]
FDG-PET	Lower	Lower	[10]

Need Custom Synthesis?

BenchChem offers custom synthesis for rare earth carbides and specific isotopic labeling.

Email: info@benchchem.com or [Request Quote Online](#).

References

- 1. PET/CT Artifacts - PMC [pmc.ncbi.nlm.nih.gov]
- 2. PET/CT Artifacts, Pitfalls and Variants [inis.iaea.org]
- 3. cme.lww.com [cme.lww.com]
- 4. researchgate.net [researchgate.net]
- 5. researchgate.net [researchgate.net]
- 6. researchgate.net [researchgate.net]
- 7. Analysis of early phase [11C]BF-227 PET, and its application for anatomical standardization of late-phase images for 3D-SSP analysis - PubMed [pubmed.ncbi.nlm.nih.gov]
- 8. researchgate.net [researchgate.net]
- 9. Amyloid-Beta Radiotracer [18F]BF-227 Does Not Bind to Cytoplasmic Glial Inclusions of Postmortem Multiple System Atrophy Brain Tissue - PMC [pmc.ncbi.nlm.nih.gov]
- 10. Amyloid PET in mild cognitive impairment and Alzheimer's disease with BF-227: comparison to FDG-PET - PubMed [pubmed.ncbi.nlm.nih.gov]
- To cite this document: BenchChem. [BF-227 PET Image Interpretation Technical Support Center]. BenchChem, [2025]. [Online PDF]. Available at: [https://www.benchchem.com/product/b15617340#challenges-in-bf-227-pet-image-interpretation]

Disclaimer & Data Validity:

The information provided in this document is for Research Use Only (RUO) and is strictly not intended for diagnostic or therapeutic procedures. While BenchChem strives to provide accurate protocols, we make no warranties, express or implied, regarding the fitness of this product for every specific experimental setup.

Technical Support: The protocols provided are for reference purposes. Unsure if this reagent suits your experiment? [[Contact our Ph.D. Support Team for a compatibility check](#)]

Need Industrial/Bulk Grade? [Request Custom Synthesis Quote](#)

BenchChem

Our mission is to be the trusted global source of essential and advanced chemicals, empowering scientists and researchers to drive progress in science and industry.

Contact

Address: 3281 E Guasti Rd
Ontario, CA 91761, United States
Phone: (601) 213-4426
Email: info@benchchem.com