

Attenuation correction artifacts in Thallium-201 SPECT imaging

Author: BenchChem Technical Support Team. **Date:** December 2025

Compound of Interest

Compound Name: *Thallous chloride TL-201*

Cat. No.: *B1258455*

[Get Quote](#)

Technical Support Center: Thallium-201 SPECT Imaging

This technical support center provides troubleshooting guides and frequently asked questions (FAQs) to help researchers, scientists, and drug development professionals address attenuation correction artifacts in Thallium-201 (TI-201) SPECT imaging.

Frequently Asked Questions (FAQs)

Q1: What are attenuation correction artifacts in TI-201 SPECT imaging?

A: Photon attenuation is a physical process that reduces the number of photons detected from the patient's body, which can lead to inaccuracies in SPECT images.^[1] Attenuation correction (AC) is a method used to compensate for this effect.^[2] However, the correction process itself can sometimes introduce errors or artifacts, which may obscure or mimic true perfusion defects.^[3] These are known as attenuation correction artifacts. In TI-201 imaging, this is particularly significant due to the lower energy of its photons, which are more susceptible to attenuation compared to tracers like Technetium-99m (Tc-99m).^[4]

Q2: Why is attenuation correction more challenging for Thallium-201?

A: The lower photon energy of Tl-201 makes it more prone to attenuation by soft tissues.[4] The attenuation coefficient for Tl-201 is about 19% greater than that for Tc-99m.[4] This means that for the same amount of tissue, a larger fraction of Tl-201 photons are absorbed or scattered before they can be detected by the SPECT camera.[4] This can lead to more pronounced artifacts, especially in regions with significant overlying tissue such as the inferior wall (due to diaphragmatic attenuation) and the anterior wall (due to breast attenuation).[2][5]

Q3: What is the most common cause of artifacts in SPECT imaging?

A: The most common artifacts in SPECT imaging are patient-related, primarily from patient motion and soft tissue attenuation.[5] Photon attenuation by soft tissue is arguably the most prevalent source of artifacts in SPECT myocardial perfusion imaging (MPI).[4][5]

Q4: How does patient motion cause artifacts, and how can it be confused with attenuation artifacts?

A: Patient motion during a SPECT scan can cause blurring or misregistration of the acquired data, leading to artifacts that can appear as perfusion defects.[5] For instance, motion can result in a "tuning fork" defect due to misalignment of the heart walls.[5] These motion-induced defects can sometimes be mistaken for attenuation artifacts or true ischemic defects. It is crucial to review the raw projection data (sinogram) for any signs of patient movement to differentiate between motion and attenuation artifacts.[5]

Q5: What is misregistration in SPECT/CT, and how does it affect attenuation correction?

A: Misregistration occurs when the patient's position changes between the CT scan (used for the attenuation map) and the SPECT emission scan.[6][7] This misalignment causes the attenuation correction factors to be applied to the wrong areas of the SPECT image, creating significant artifacts.[6][8] For example, lung tissue correction might be incorrectly applied to the myocardium, or vice versa, leading to artificially decreased or increased counts in those regions.[9] Reviewing the fused SPECT and CT images is essential to check for proper alignment.[7][9]

Troubleshooting Guide

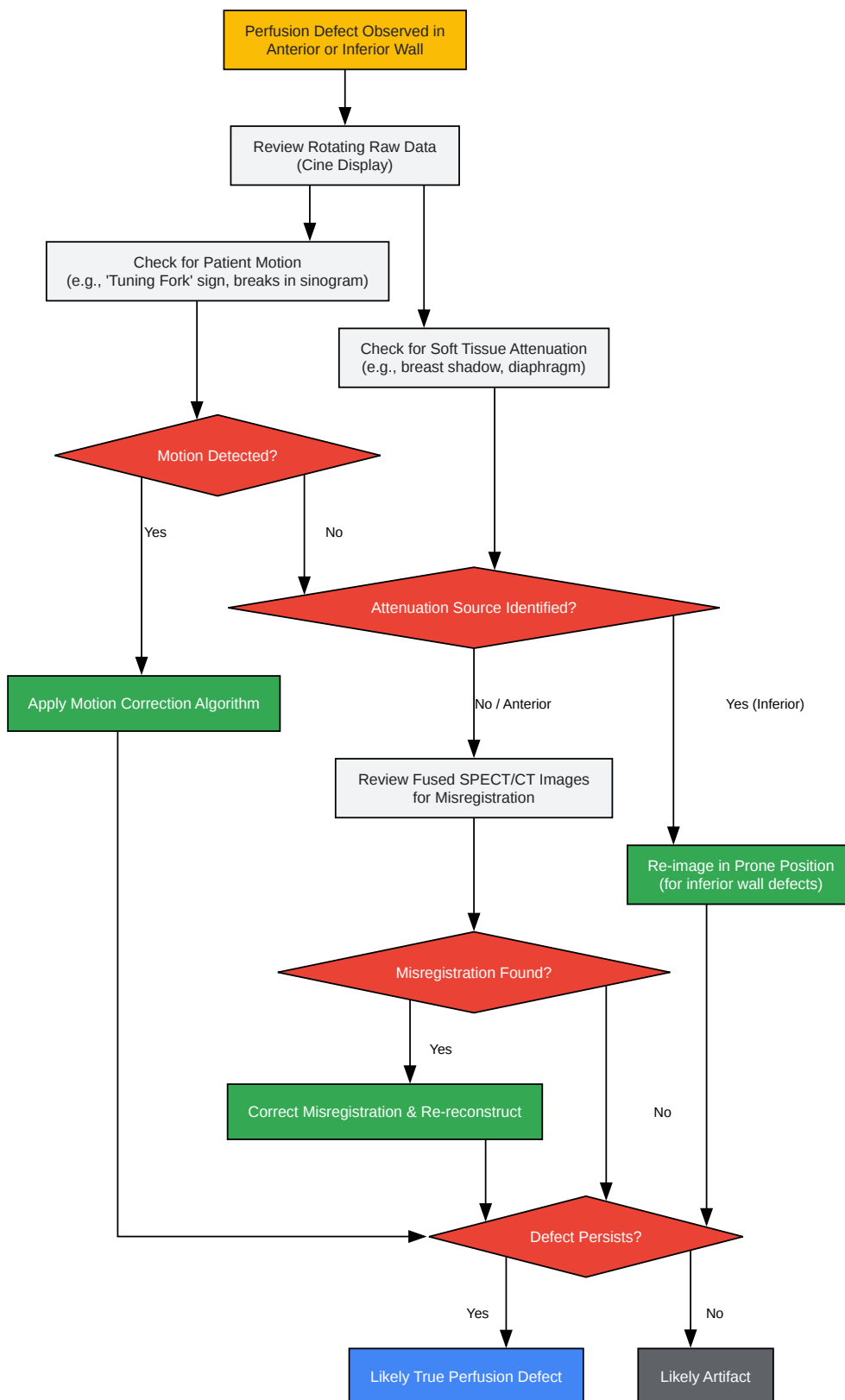
This guide provides systematic steps to identify, troubleshoot, and prevent common attenuation correction artifacts in TI-201 SPECT imaging.

Issue 1: Apparent Perfusion Defect in a Region Prone to Attenuation

Symptoms:

- A fixed or reversible perfusion defect is observed in the anterior, anterolateral, or inferior wall.
[4][5]
- The defect does not conform to a specific coronary artery distribution.[5]

Workflow for Differentiating Artifact from True Defect



[Click to download full resolution via product page](#)

Caption: Workflow for troubleshooting suspected attenuation artifacts.

Troubleshooting Steps & Solutions

Potential Cause	Identification Method	Recommended Solution	Prevention Strategy
Breast Attenuation	Review rotating projection images for a shadow over the anterior or lateral walls.[4][5]	Re-image with breast positioning aids or utilize CT-based attenuation correction.	Ensure consistent breast positioning between rest and stress scans. Counsel the patient to remain still.[5]
Diaphragmatic Attenuation	A perfusion defect in the inferior wall, often more prominent in male patients.[4]	Re-image the patient in the prone position. If the defect resolves or lessens, it is likely an artifact.[5]	Prone imaging can be used as a supplementary view in patients with suspected inferior wall attenuation.[5]
Patient Motion	Review sinogram data for sharp breaks or a "tuning fork" appearance on processed images.[5]	Apply vendor-specific motion correction software. If motion is severe, repeat the acquisition.[5]	Make the patient as comfortable as possible. Explain the importance of remaining still during the scan.[5]
SPECT/CT Misregistration	Fused SPECT and CT images show misalignment of the heart or surrounding structures.[7][9]	Manually or automatically re-register the emission and transmission data before reconstruction.[7]	Instruct the patient not to move between the CT and SPECT acquisitions.[7]

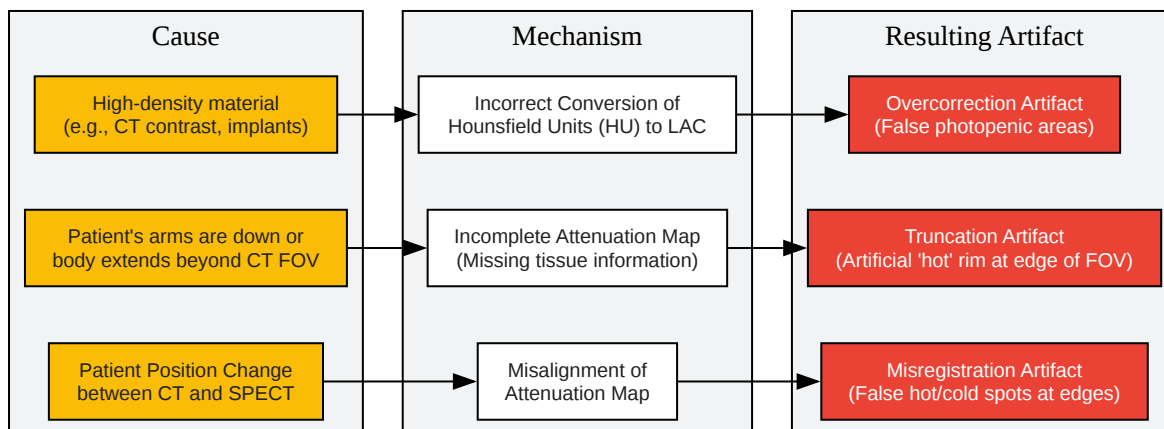
Issue 2: Artifacts Introduced by the Attenuation Correction Process

Symptoms:

- Unusual "hot" or "cold" spots appear near the heart after AC is applied.[6]

- Image noise is significantly increased in the corrected images.
- The outline of the body is truncated in the CT scan.

Logical Relationship of CT-Based AC Artifacts



[Click to download full resolution via product page](#)

Caption: Relationship between causes and types of CT-based AC artifacts.

Troubleshooting Steps & Solutions

Artifact Type	Common Cause	Identification	Recommended Action
Misregistration	Patient movement between CT and SPECT scans. [6] [7]	Review fused images for misalignment of anatomical structures (e.g., heart, diaphragm, spine). [7]	Use software to re-register the CT and SPECT datasets and reprocess the images. [7]
Truncation	The patient's body is wider than the CT Field of View (FOV). [6]	The edges of the patient's body are cut off on the CT image.	Use software algorithms designed to extrapolate the missing CT data. Ensure proper patient positioning with arms up. [6]
CT Contrast/Metal Artifacts	Presence of high-density materials leads to incorrect attenuation values. [6]	Streaking artifacts on the CT image; review patient history for contrast administration or metallic implants.	If possible, acquire the CT scan for attenuation correction before contrast administration. Review non-corrected images for comparison. [6]

Experimental Protocols: Quality Control

Performing regular Quality Control (QC) is critical to prevent artifacts.[\[4\]](#)[\[10\]](#) Key QC tests for SPECT/CT systems include:

1. Daily Quality Control

Procedure	Methodology	Acceptance Criteria	Frequency
Energy Peaking	Use the correct radionuclide source (e.g., Tc-99m) to verify that the photopeak is centered in the energy window.	The photopeak should be centered within the manufacturer's specified limits. The energy window should not have drifted.[11]	Daily, before patient imaging.[11]
Uniformity Flood	Acquire an image of a uniform source of radioactivity (intrinsic with a point source or extrinsic with a sheet source) for 2-5 million counts.[11]	The image should be free of non-uniformities or "cold" spots, within manufacturer specifications.	Daily, before patient imaging.[11]
CT QC (if applicable)	Perform daily calibration/QC scans as recommended by the CT manufacturer.	Must pass the manufacturer's internal checks.	Daily.

2. Weekly/Monthly Quality Control

Procedure	Methodology	Acceptance Criteria	Frequency
Center of Rotation (COR)	Acquire a SPECT scan of a point source placed off-center in the field of view.[11]	The analysis should show a misalignment of <0.5 pixels. If greater, recalibration is required.[11]	Weekly or as per manufacturer recommendation.[4]
SPECT/CT Registration	Scan a phantom containing radioactive markers that are visible on both SPECT and CT.[9]	The measured centers of the markers on both modalities should align within manufacturer-specified tolerances. [9]	Weekly or monthly, and after any major service.[9]

Experimental Protocol: Prone Imaging for Inferior Wall Defects

- **Patient Preparation:** After the standard supine stress or rest acquisition is complete, explain the need for an additional scan to the patient.
- **Positioning:** Assist the patient in moving safely to a prone position on the imaging table. Ensure they are as comfortable as possible to minimize motion. The arms are typically positioned overhead.
- **Acquisition:** Perform a SPECT acquisition using the same parameters (e.g., angle, time per stop, matrix size) as the supine scan.
- **Processing:** Reconstruct the prone images using the same reconstruction parameters (including attenuation correction if applicable) as the supine images.
- **Analysis:** Compare the inferior wall perfusion on the prone images to the supine images. A significant improvement or normalization of an inferior defect on the prone study is indicative of a diaphragmatic attenuation artifact.[5]

Need Custom Synthesis?

BenchChem offers custom synthesis for rare earth carbides and specific isotopic labeling.

Email: info@benchchem.com or [Request Quote Online](#).

References

- 1. Attenuation Correction for Dedicated Cardiac SPECT Imaging Without Using Transmission Data - PMC [pmc.ncbi.nlm.nih.gov]
- 2. Understanding Attenuation Correction - Digirad [digirad.com]
- 3. UpToDate 2018 [sniv3r2.github.io]
- 4. tech.snmjournals.org [tech.snmjournals.org]
- 5. Recognizing and preventing artifacts with SPECT and PET imaging | Radiology Key [radiologykey.com]
- 6. Morphology supporting function: attenuation correction for SPECT/CT, PET/CT, and PET/MR imaging - PMC [pmc.ncbi.nlm.nih.gov]

- 7. asnc.org [asnc.org]
- 8. irjnm.tums.ac.ir [irjnm.tums.ac.ir]
- 9. SPECT/CT Physical Principles and Attenuation Correction | Journal of Nuclear Medicine Technology [tech.snmjournals.org]
- 10. eanm.org [eanm.org]
- 11. Quality Control in SPECT and PET Imaging | Thoracic Key [thoracickey.com]
- To cite this document: BenchChem. [Attenuation correction artifacts in Thallium-201 SPECT imaging]. BenchChem, [2025]. [Online PDF]. Available at: [<https://www.benchchem.com/product/b1258455#attenuation-correction-artifacts-in-thallium-201-spect-imaging>]

Disclaimer & Data Validity:

The information provided in this document is for Research Use Only (RUO) and is strictly not intended for diagnostic or therapeutic procedures. While BenchChem strives to provide accurate protocols, we make no warranties, express or implied, regarding the fitness of this product for every specific experimental setup.

Technical Support: The protocols provided are for reference purposes. Unsure if this reagent suits your experiment? [[Contact our Ph.D. Support Team for a compatibility check](#)]

Need Industrial/Bulk Grade? [Request Custom Synthesis Quote](#)

BenchChem

Our mission is to be the trusted global source of essential and advanced chemicals, empowering scientists and researchers to drive progress in science and industry.

Contact

Address: 3281 E Guasti Rd
Ontario, CA 91761, United States
Phone: (601) 213-4426
Email: info@benchchem.com