

Artifacts in Pentetreotide SPECT imaging and how to avoid them

Author: BenchChem Technical Support Team. **Date:** December 2025

Compound of Interest

Compound Name: Pentetreotide

Cat. No.: B1205498

[Get Quote](#)

Technical Support Center: Pentetreotide SPECT Imaging

This technical support center provides troubleshooting guidance and frequently asked questions (FAQs) for researchers, scientists, and drug development professionals utilizing **Pentetreotide** SPECT imaging. The information aims to help identify and mitigate common artifacts to ensure high-quality, reliable data.

Frequently Asked Questions (FAQs)

Q1: What are the most common artifacts encountered in **Pentetreotide** SPECT imaging?

A1: The most frequently observed artifacts in SPECT imaging, including with **Pentetreotide**, are patient-related, such as motion and soft tissue attenuation.^[1] Other common issues include artifacts arising from equipment malfunction, reconstruction errors, and altered radiopharmaceutical biodistribution.^{[1][2]}

Q2: How does patient motion affect the quality of SPECT images?

A2: Patient motion during image acquisition is a significant source of artifacts.^[1] It can lead to blurring and misregistration of the collected data, which may mimic perfusion defects or obscure true findings.^{[1][3][4]} Abrupt movements and motion occurring in the middle of the acquisition are particularly detrimental to image quality.^[1]

Q3: What is soft tissue attenuation and how does it impact the images?

A3: Soft tissue attenuation is the absorption or scattering of photons by the patient's own tissues, such as the breasts or diaphragm, before they reach the camera detector.[1][5] This can create artificially reduced counts in certain areas, potentially leading to false-positive findings that may be misinterpreted as disease.[1] This is a very common source of artifacts in SPECT imaging.[1]

Q4: Can physiological uptake of **Pentetreotide** be mistaken for pathology?

A4: Yes, physiological uptake of **Pentetreotide** in organs like the kidneys, liver, spleen, and bowel can sometimes be misinterpreted.[6][7] For instance, uptake in mesenteric lymph nodes can be mistaken for physiological small bowel activity, and liver metastases can be confused with normal gallbladder uptake.[6][7] Using SPECT/CT for anatomical correlation is crucial to avoid these pitfalls.[6][7][8]

Q5: What is the significance of "free pertechnetate" in the radiopharmaceutical preparation?

A5: Free pertechnetate (^{99m}Tc) is a common impurity that can result from faulty radiopharmaceutical preparation.[9] Its presence leads to altered biodistribution, with increased tracer uptake in the stomach, thyroid, and salivary glands, which can compromise the diagnostic quality of the images.[9]

Troubleshooting Guide

This guide provides solutions for specific artifacts you may encounter during **Pentetreotide** SPECT imaging.

Observed Artifact/Issue	Potential Cause(s)	Identification	Recommended Action(s) & Prevention
Blurring, Streaking, or "Ghosting" of Lesions	Patient Motion	Review of raw projection data (sinogram) may show discontinuities or misalignments.[4][10]	Prevention: Ensure patient comfort, clearly explain the procedure to improve cooperation, and use immobilization devices if necessary.[1][11] Correction: Some software packages offer motion correction algorithms that can be applied post-acquisition.[4] If severe, the acquisition may need to be repeated.[4]
Reduced Uptake in Inferior or Anterior Walls (False-Positive)	Soft Tissue Attenuation (e.g., from diaphragm or breast tissue)	Review rotating planar projection images to identify shadows from attenuating tissue.[1] The defect may not conform to a specific coronary artery distribution.[1]	Prevention: Image patients with arms placed above the head consistently for both rest and stress images.[1] Imaging without a bra can also help minimize breast attenuation.[1] Correction: Utilize attenuation correction hardware/software (often CT-based in SPECT/CT systems). [1][12] Prone imaging can also help by displacing abdominal

organs away from the heart.[\[12\]](#)

Uptake in Stomach, Thyroid, and Salivary Glands

Free Pertechnetate in Radiopharmaceutical

Visualization of these organs on the scan, which are not typical sites of Pentetreotide accumulation.[\[9\]](#)

Prevention: Strictly follow the radiopharmaceutical preparation protocol. Perform quality control (e.g., chromatography) to check for radiochemical purity before injection. Improper reconstitution of kits can lead to poor labeling.[\[13\]](#)

"Halo" Artifact Around Intense Hot Spots

Iterative Reconstruction Error

A photopenic "halo" appears around areas of very high tracer uptake.[\[10\]](#)

Correction: This is a known artifact of some iterative reconstruction algorithms.[\[10\]](#) If suspected, re-reconstructing the data with a different algorithm, like filtered backprojection (FBP), can help confirm and resolve the artifact, though FBP may introduce other artifacts like streaking.[\[10\]](#)

Ring or "Bull's-Eye" Artifacts

Detector Non-Uniformity

Circular or concentric ring artifacts appear throughout the reconstructed image.

Prevention: Perform daily and weekly quality control procedures, including

uniformity flood corrections, as recommended by the manufacturer.[\[14\]](#) This ensures the detector's response is uniform across its surface.

Image Blurring and Spatial Distortion	Center of Rotation (COR) Error	Subtle or glaring artifacts, including image blurring, that degrade spatial resolution. [10] [15] Even a small 0.5-pixel COR error can degrade image quality. [15]	Prevention: Perform regular COR calibration as part of the quality control schedule. If an error is detected, the system should be recalibrated by a service engineer before performing further SPECT studies. [10]
---------------------------------------	--------------------------------	--	---

Mislocalization of Uptake (e.g., Bowel vs. Tumor)	Lack of Anatomical Correlation	Functional uptake is seen on SPECT-only images, but its precise anatomical location is ambiguous. [6] [7]	Prevention/Correction: Always acquire a co-registered CT scan (SPECT/CT). The CT provides the anatomical map needed to accurately localize functional uptake and differentiate pathological lesions from physiological activity in organs like the bowel or uncinate process of the pancreas. [6] [7] [16]
---	--------------------------------	---	--

High Background/Poor	Intense Physiological Bowel/Biliary Activity	Diffuse or focal activity in the abdomen that	Prevention: Ensure the patient is well-
----------------------	--	---	---

Contrast in Abdomen

can obscure or mimic pathological uptake.
[12][16]

hydrated.[17] A mild laxative may be considered, especially when the abdomen is the area of interest.[8]
[17] Correction: Delayed imaging (e.g., at 24 hours) can allow for washout of physiological bowel activity, improving the distinction between transient and fixed pathological uptake.
[16] Comparing 4-hour and 24-hour images is a standard technique.
[18]

Quantitative Data Summary

While specific artifact frequencies can vary widely based on equipment, protocols, and patient populations, the following table summarizes quantitative data related to **Pentetreotide** biodistribution, which is crucial for interpreting images and avoiding pitfalls.

Table 1: Normal Organ Uptake & Variability with ¹¹¹In-**Pentetreotide** SPECT

Organ	Mean SPECT Uptake Value (SPECT-UV) \pm SD	Coefficient of Variation (COV) - Across All Scans	Key Consideration
Liver	1.7 \pm 0.6	0.33	Lower uptake compared to kidneys, but can be a site of metastases. [19] SPECT/CT improves detection in the liver. [8]
Left Kidney	7.5 \pm 1.7	0.22	High physiological uptake is expected as the tracer is primarily excreted by the kidneys. [8] [19]
Right Kidney	8.0 \pm 2.4	0.30	Similar to the left kidney, high uptake is normal. [19] Impaired renal function can increase tracer retention. [20]
Spleen	Data not specified in the same format	Data not specified	Physiological uptake is normal. Accessory spleens or splenosis can be mistaken for metastases. [21]

Data adapted from studies on **¹¹¹In-pentetreotide**, which has similar biodistribution characteristics to ^{99m}Tc-Tektrotyd.[\[8\]](#)[\[19\]](#)

Experimental Protocols

1. Protocol: Radiopharmaceutical Quality Control (Radiochemical Purity)

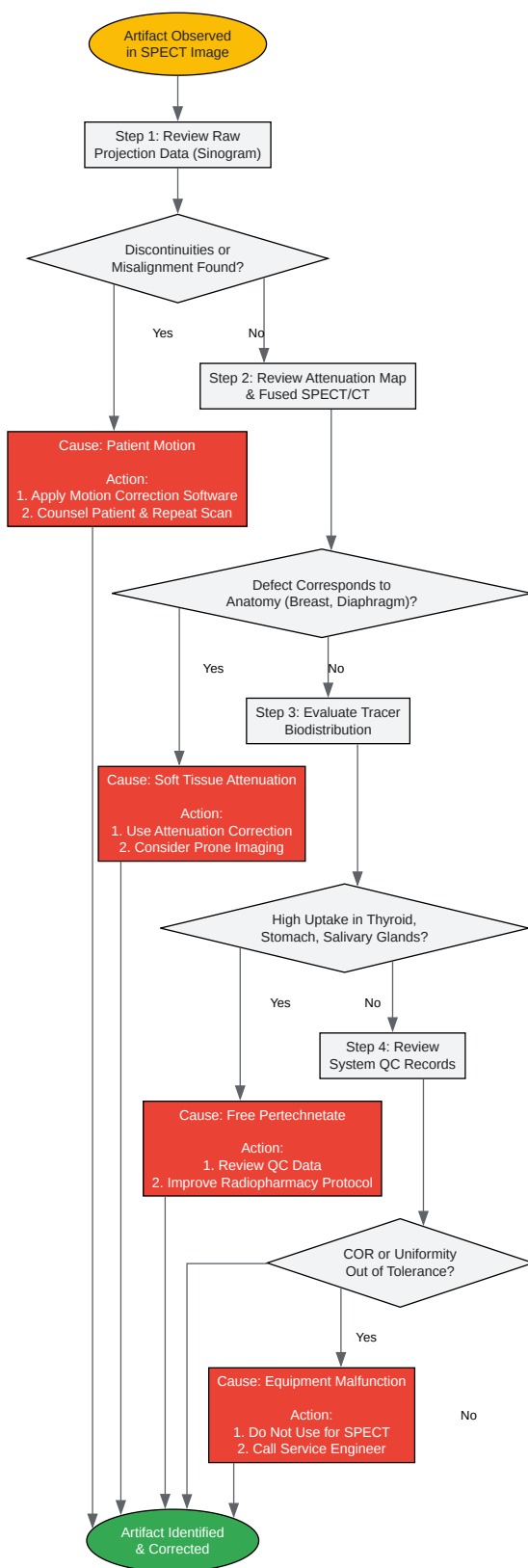
- Purpose: To determine the percentage of free pertechnetate ($^{99m}\text{TcO}_4^-$) in the final ^{99m}Tc -Tektrotyd preparation. A radiochemical purity of >90% is typically required.
- Methodology: Instant Thin-Layer Chromatography (ITLC).
 - Stationary Phase: ITLC-SG (Silica Gel) strip.
 - Mobile Phase: Acetone.
 - Procedure: a. Apply a small spot of the prepared ^{99m}Tc -Tektrotyd solution approximately 1 cm from the bottom of the ITLC-SG strip. b. Place the strip in a chromatography tank containing the acetone mobile phase, ensuring the spot is above the solvent level. c. Allow the solvent to migrate up the strip until it is near the top. d. Remove the strip and let it dry. e. Cut the strip in half (or at a predefined migration front).
 - Analysis:
 - Free pertechnetate ($^{99m}\text{TcO}_4^-$) is soluble in acetone and will migrate with the solvent front to the top of the strip ($R_f = 1.0$).
 - Radiolabeled ^{99m}Tc -Tektrotyd and any hydrolyzed-reduced ^{99m}Tc will remain at the origin ($R_f = 0.0$). f. Measure the radioactivity of each half of the strip in a dose calibrator or gamma counter.
 - Calculation: % Free Pertechnetate = (Counts at Solvent Front / Total Counts) * 100

2. Protocol: Standard Patient Preparation for **Pentetreotide** Imaging

- Purpose: To optimize image quality by ensuring patient safety and minimizing physiological tracer uptake that could interfere with interpretation.
- Methodology:
 - Medication Review: In consultation with the referring physician, consider discontinuing long-acting octreotide therapy for 4-6 weeks and short-acting therapy for at least 24 hours before tracer injection, where clinically appropriate.[\[17\]](#)

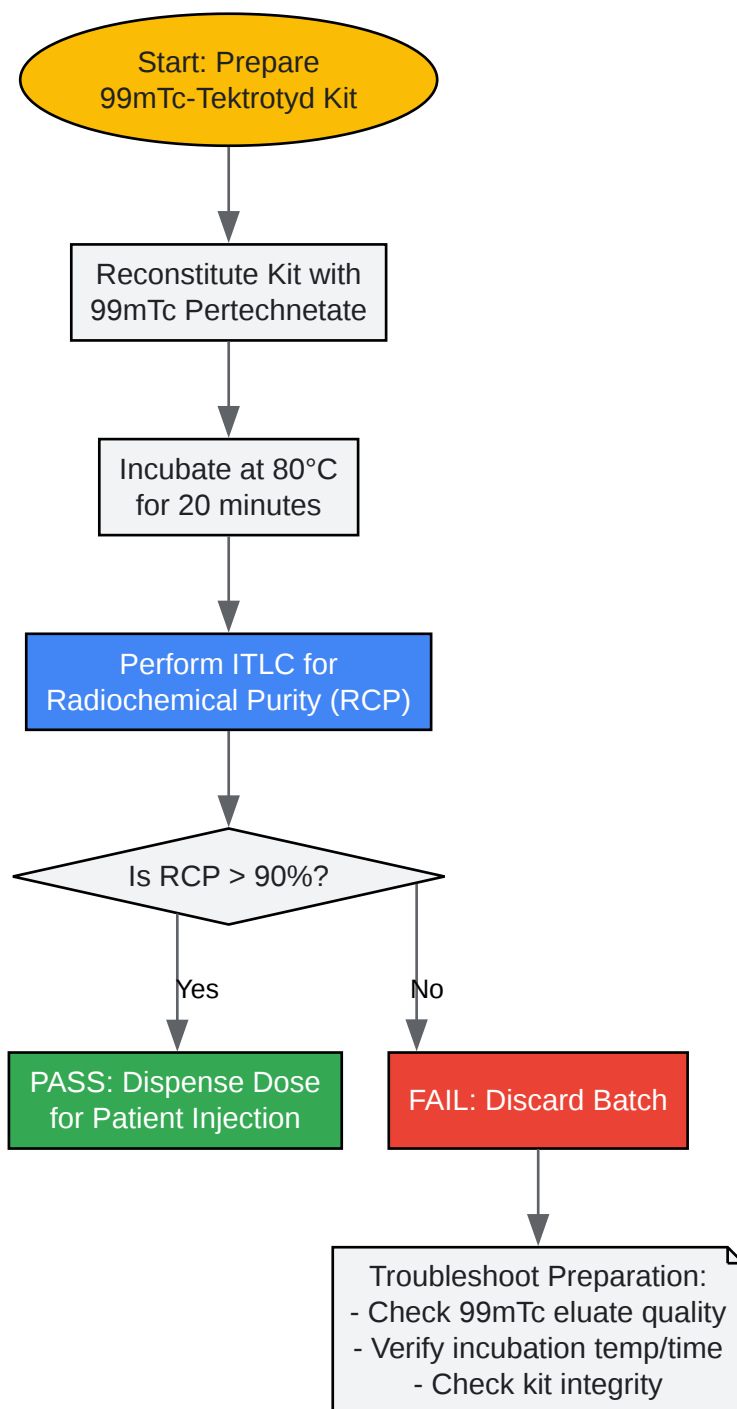
- Hydration: Instruct the patient to be well-hydrated before the tracer injection and for at least one day after to minimize radiation exposure and promote clearance of unbound tracer.[17]
- Bowel Preparation: The use of a mild oral laxative the evening before and after the injection should be considered on an individual basis, particularly if the abdomen is the primary area of interest. This is contraindicated in patients with active diarrhea or suspected insulinoma.[8][17]
- Patient Instructions: Explain the entire procedure to the patient, including the need to remain still during the scan, to enhance cooperation and reduce motion artifacts.[1]
- Pre-Imaging: The patient should void immediately before image acquisition to reduce bladder activity, which can obscure pelvic lesions.[2][17]

Visual Guides & Workflows



[Click to download full resolution via product page](#)

Caption: A troubleshooting workflow for identifying and correcting common artifacts in SPECT imaging.



[Click to download full resolution via product page](#)

Caption: Quality control workflow for the preparation of 99mTc-Tektrotyd radiopharmaceutical.

Need Custom Synthesis?

BenchChem offers custom synthesis for rare earth carbides and specific isotopic labeling.

Email: info@benchchem.com or [Request Quote Online](#).

References

- 1. Recognizing and preventing artifacts with SPECT and PET imaging | Radiology Key [radiologykey.com]
- 2. Nuclear Medicine Artifacts - StatPearls - NCBI Bookshelf [ncbi.nlm.nih.gov]
- 3. revistamedicinamilitara.ro [revistamedicinamilitara.ro]
- 4. youtube.com [youtube.com]
- 5. Image Artifacts | Thoracic Key [thoracickey.com]
- 6. omjournal.org [omjournal.org]
- 7. omjournal.org [omjournal.org]
- 8. Limitations and pitfalls of 99mTc-EDDA/HYNIC-TOC (Tektrotyd) scintigraphy | Garai | Nuclear Medicine Review [journals.viamedica.pl]
- 9. med.emory.edu [med.emory.edu]
- 10. academic.oup.com [academic.oup.com]
- 11. tech.snmjournals.org [tech.snmjournals.org]
- 12. Subdiaphragmatic activity-related artifacts in myocardial perfusion scintigraphy - PMC [pmc.ncbi.nlm.nih.gov]
- 13. An Easily Overlooked Cause of High Level of Free Pertechnetate in Lung Perfusion Scintigraphy with 99mTc-MAA Resulting From Improper Kit Reconstitution - PMC [pmc.ncbi.nlm.nih.gov]
- 14. Quality Control in SPECT and PET Imaging | Thoracic Key [thoracickey.com]
- 15. dergipark.org.tr [dergipark.org.tr]
- 16. eprints.whiterose.ac.uk [eprints.whiterose.ac.uk]
- 17. researchgate.net [researchgate.net]
- 18. polatom.pl [polatom.pl]

- 19. Repeatability of Radiotracer Uptake in Normal Abdominal Organs with ^{111}In -Pentetreotide Quantitative SPECT/CT - PMC [pmc.ncbi.nlm.nih.gov]
- 20. jnm.snmjournals.org [jnm.snmjournals.org]
- 21. researchgate.net [researchgate.net]
- To cite this document: BenchChem. [Artifacts in Pentetreotide SPECT imaging and how to avoid them]. BenchChem, [2025]. [Online PDF]. Available at: [https://www.benchchem.com/product/b1205498#artifacts-in-pentetreotide-spect-imaging-and-how-to-avoid-them]

Disclaimer & Data Validity:

The information provided in this document is for Research Use Only (RUO) and is strictly not intended for diagnostic or therapeutic procedures. While BenchChem strives to provide accurate protocols, we make no warranties, express or implied, regarding the fitness of this product for every specific experimental setup.

Technical Support: The protocols provided are for reference purposes. Unsure if this reagent suits your experiment? [[Contact our Ph.D. Support Team for a compatibility check](#)]

Need Industrial/Bulk Grade? [Request Custom Synthesis Quote](#)

BenchChem

Our mission is to be the trusted global source of essential and advanced chemicals, empowering scientists and researchers to drive progress in science and industry.

Contact

Address: 3281 E Guasti Rd
Ontario, CA 91761, United States
Phone: (601) 213-4426
Email: info@benchchem.com