

Application of Jenner's Stain in Veterinary Hematology: Detailed Application Notes and Protocols

Author: BenchChem Technical Support Team. **Date:** December 2025

Compound of Interest

Compound Name: Jenner's Stain

Cat. No.: B8821939

[Get Quote](#)

For Researchers, Scientists, and Drug Development Professionals

Jenner's stain, a Romanowsky-type stain, is a classic and effective tool in veterinary hematology for the differential staining of blood smears. Composed of a mixture of methylene blue and eosin dyes dissolved in methanol, it allows for the clear visualization and differentiation of various blood cell types based on their acidic and basic components.^[1] This document provides detailed application notes and protocols for the use of **Jenner's stain** in the morphological assessment of blood cells from various animal species.

Principle of Staining

Jenner's stain operates on the principle of differential staining by utilizing both an acidic dye (eosin) and a basic dye (methylene blue).^[2] The methanolic solution also serves as a fixative for the blood smear.^{[3][4]} The staining mechanism is as follows:

- Basic components of the cell, such as hemoglobin and eosinophilic granules, are acidic and bind to the eosin, staining them in shades of pink or red.^[3]
- Acidic components, including the nucleic acids (DNA and RNA) in the nucleus and ribosomes in the cytoplasm, are basic and attract the methylene blue and its oxidation products (azures), resulting in blue to purple staining.

The final coloration of cellular elements is pH-dependent, with a buffered solution typically used to ensure optimal and consistent staining results.

Application Notes

Jenner's stain is particularly useful for routine hematological examinations, including:

- Differential white blood cell (WBC) counts: It provides clear differentiation of neutrophils, lymphocytes, monocytes, eosinophils, and basophils.
- Red blood cell (RBC) morphology assessment: It allows for the identification of variations in size (anisocytosis), shape (poikilocytosis), and staining characteristics (e.g., polychromasia, hypochromasia), which are indicative of various anemic conditions.
- Platelet estimation and morphology: It facilitates the assessment of platelet numbers and the identification of morphological abnormalities.
- Detection of blood parasites: **Jenner's stain** can aid in the identification of certain hemoparasites.

While **Jenner's stain** is a standalone stain, it is also frequently used in combination with Giemsa stain (Jenner-Giemsa or May-Grünwald-Giemsa techniques) to enhance the staining of certain cellular features, particularly in bone marrow aspirates.

Species-Specific Considerations

The morphology of blood cells can vary significantly between different animal species. Below are general morphological characteristics observed with Romanowsky-type stains like **Jenner's stain**.

- Canine: Erythrocytes are relatively uniform with a distinct central pallor. Neutrophils have distinctly segmented nuclei. Platelets are typically uniform in size.
- Feline: Erythrocytes are smaller than in dogs and exhibit minimal central pallor. Rouleaux formation (stacking of RBCs) can be a normal finding. Feline platelets are often larger and more variable in size compared to other species.

- Equine: Erythrocytes are uniform in size and lack central pallor. Rouleaux formation is a prominent and normal feature. Neutrophil nuclei are often less distinctly segmented.
- Bovine: Erythrocytes show some degree of anisocytosis and lack central pallor. Lymphocytes can be more variable in size compared to other species, and in some healthy cattle, lymphocytes may outnumber neutrophils.

Experimental Protocols

Proper preparation of the blood smear is critical for accurate morphological assessment.

Blood Smear Preparation

- Place a small drop of well-mixed fresh or EDTA-anticoagulated blood approximately 1-2 cm from the frosted end of a clean, grease-free microscope slide.
- Hold a second "spreader" slide at a 30-45 degree angle and bring it back to make contact with the blood drop.
- Allow the blood to spread along the edge of the spreader slide.
- In a smooth, rapid motion, push the spreader slide forward to the end of the first slide, creating a thin film of blood.
- A good smear should have a "feathered edge" and a monolayer of cells where they are close together but not overlapping.
- Air-dry the smear quickly to prevent cellular distortion.

Staining Protocol (Immersion Method)

This is a common and straightforward method for staining blood smears.

- Fixation: Immerse the completely dried blood smear in absolute methanol for 15 seconds to 5 minutes. This step fixes the cells to the slide.
- Staining: Immerse the fixed slide in **Jenner's stain** solution for 1-3 minutes.

- **Washing:** Briefly rinse the slide in distilled or buffered water (pH 6.4-6.8) until the smear appears pinkish-red. Over-washing can lead to a pale stain.
- **Drying:** Allow the slide to air dry in an upright position.
- **Microscopy:** Examine the smear under a microscope, starting at low power to assess the overall quality and cell distribution, then moving to higher power (with oil immersion) for detailed morphological evaluation.

Data Presentation

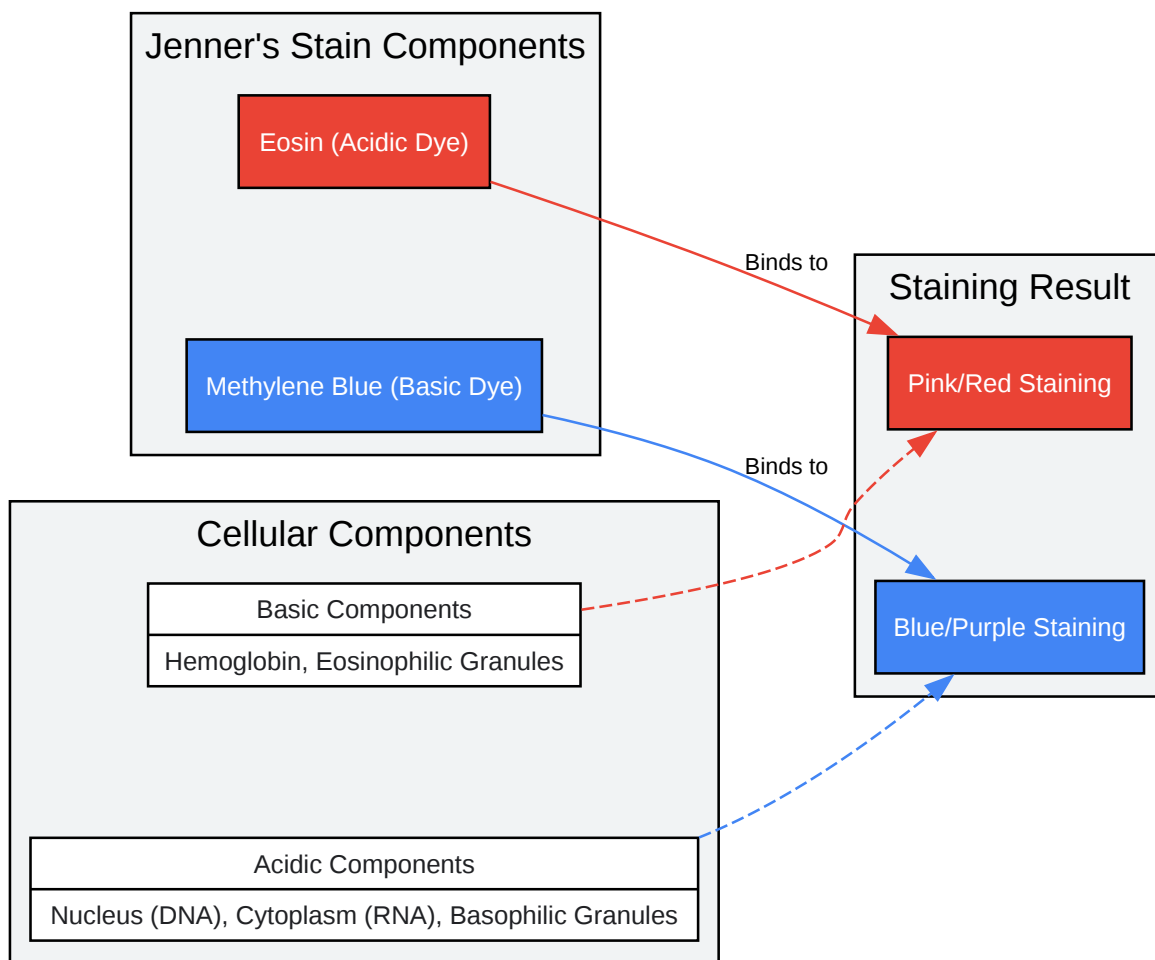
Table 1: General Staining Characteristics of Blood Cells with Jenner's Stain

Cellular Component	Staining Color	Rationale
Erythrocytes	Pink to Reddish-Pink	Binding of eosin to the basic hemoglobin.
Leukocyte Nuclei	Purple to Dark Blue	Binding of methylene blue and azures to the acidic DNA.
Neutrophil Cytoplasm	Pale Pink/Gray with fine, diffuse granules	Neutral staining characteristics.
Eosinophil Granules	Bright Red to Orange-Red	Strong affinity of the basic granules for the acidic eosin dye.
Basophil Granules	Deep Purple to Blue-Black	Strong affinity of the acidic granules for the basic methylene blue dye.
Lymphocyte Cytoplasm	Light to Dark Blue	Varies with the amount of RNA present.
Monocyte Cytoplasm	Gray-Blue	Characteristic ground-glass appearance.
Platelets	Light Blue with Purple Granules	Contains both acidic and basic components.

Table 2: Troubleshooting Common Issues with Jenner's Staining

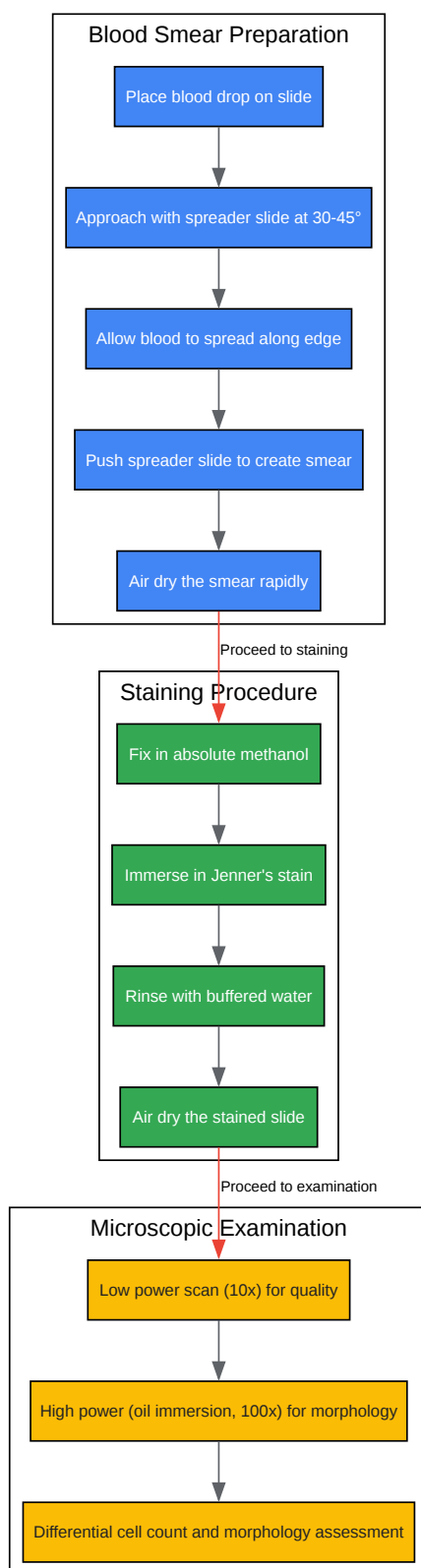
Issue	Possible Cause(s)	Recommended Solution(s)
Overall stain is too blue	- Stain time too long- Inadequate washing- Smear is too thick- pH of stain or buffer is too alkaline	- Reduce staining time- Ensure proper rinsing with buffered water- Prepare a thinner blood smear- Check and adjust the pH of the buffer to be more acidic
Overall stain is too red/pink	- Stain time too short- Over-washing- pH of stain or buffer is too acidic	- Increase staining time- Reduce rinsing time- Check and adjust the pH of the buffer to be more alkaline
Cells appear washed out or pale	- Old or exhausted stain- Over-washing- Inadequate fixation	- Use fresh staining solution- Reduce rinsing time- Ensure proper fixation time in methanol
Precipitate on the slide	- Stain was not filtered- Stain was allowed to dry on the slide	- Filter the stain before use- Do not allow the stain to dry on the slide during the staining process
Cellular morphology is poor	- Slow drying of the smear- Poor quality blood sample	- Dry the smear quickly after preparation- Use a fresh blood sample and prepare the smear promptly

Mandatory Visualization



[Click to download full resolution via product page](#)

Principle of **Jenner's Stain**



[Click to download full resolution via product page](#)

Jenner's Stain Experimental Workflow

Need Custom Synthesis?

BenchChem offers custom synthesis for rare earth carbides and specific isotopic labeling.

Email: info@benchchem.com or [Request Quote Online](#).

References

- 1. [scytek.com](https://www.scytek.com) [[scytek.com](https://www.scytek.com)]
- 2. [eclinpath.com](https://www.eclinpath.com) [[eclinpath.com](https://www.eclinpath.com)]
- 3. [documents.thermofisher.com](https://www.documents.thermofisher.com) [[documents.thermofisher.com](https://www.documents.thermofisher.com)]
- 4. [emsdiasum.com](https://www.emsdiasum.com) [[emsdiasum.com](https://www.emsdiasum.com)]
- To cite this document: BenchChem. [Application of Jenner's Stain in Veterinary Hematology: Detailed Application Notes and Protocols]. BenchChem, [2025]. [Online PDF]. Available at: [<https://www.benchchem.com/product/b8821939#application-of-jenner-s-stain-in-veterinary-hematology>]

Disclaimer & Data Validity:

The information provided in this document is for Research Use Only (RUO) and is strictly not intended for diagnostic or therapeutic procedures. While BenchChem strives to provide accurate protocols, we make no warranties, express or implied, regarding the fitness of this product for every specific experimental setup.

Technical Support: The protocols provided are for reference purposes. Unsure if this reagent suits your experiment? [[Contact our Ph.D. Support Team for a compatibility check](#)]

Need Industrial/Bulk Grade? [Request Custom Synthesis Quote](#)

BenchChem

Our mission is to be the trusted global source of essential and advanced chemicals, empowering scientists and researchers to drive progress in science and industry.

Contact

Address: 3281 E Guasti Rd

Ontario, CA 91761, United States

Phone: (601) 213-4426

Email: info@benchchem.com