

Application of 19-Iodocholesterol 3-acetate in Primary Aldosteronism Research and Diagnosis

Author: BenchChem Technical Support Team. **Date:** December 2025

Compound of Interest

Compound Name: 19-Iodocholesterol 3-acetate

Cat. No.: B1208695

[Get Quote](#)

Application Notes and Protocols for Researchers, Scientists, and Drug Development Professionals

Introduction

19-Iodocholesterol 3-acetate, also known as ^{131}I -6 β -iodomethyl-19-norcholesterol (NP-59), is a radiolabeled cholesterol analog used in adrenal scintigraphy. This technique provides both functional and morphological information about the adrenal cortex. In the context of primary aldosteronism (PA), NP-59 scintigraphy, particularly when combined with dexamethasone suppression, is a valuable tool for differentiating between an aldosterone-producing adenoma (APA) and bilateral adrenal hyperplasia (BAH). This distinction is crucial as APA is often surgically curable, while BAH typically requires lifelong medical management. NP-59 is taken up by functioning adrenal cortical tissue, mirroring the pathway of cholesterol, a precursor for steroid hormone synthesis.

Principle of the Method

The diagnostic utility of NP-59 scintigraphy in primary aldosteronism is based on the differential regulation of cholesterol uptake in normal and abnormal adrenal tissue. The pituitary hormone ACTH (adrenocorticotrophic hormone) stimulates cholesterol uptake in the adrenal cortex. In patients with an aldosterone-producing adenoma, aldosterone secretion is autonomous and not primarily driven by the renin-angiotensin system or ACTH. By administering dexamethasone, a potent synthetic glucocorticoid, endogenous ACTH production is suppressed. This leads to reduced NP-59 uptake in normal adrenal tissue and in cases of bilateral adrenal hyperplasia

that are ACTH-dependent. However, an autonomous aldosterone-producing adenoma will continue to take up NP-59, allowing for its visualization and lateralization on scintigraphy. The addition of Single-Photon Emission Computed Tomography/Computed Tomography (SPECT/CT) can further enhance the accuracy of localization, especially for smaller adenomas. [\[1\]](#)[\[2\]](#)[\[3\]](#)[\[4\]](#)

Diagnostic Performance

The diagnostic accuracy of NP-59 adrenal scintigraphy in distinguishing APA from BAH has been evaluated in several studies. The performance can be influenced by factors such as adenoma size and the use of SPECT/CT. [\[1\]](#)[\[5\]](#)

Diagnostic Parameter	Value	Study/Note
Sensitivity for APA Detection	83.3%	Retrospective study analyzing patients from 2000-2016. [6]
Specificity for APA Detection	44.4%	Same retrospective study. [6]
Positive Predictive Value for APA	92.3%	Same retrospective study. [6]
Sensitivity with SPECT/CT	85.0%	The addition of SPECT/CT showed an increase in sensitivity. [6]
Specificity with SPECT/CT	60.0%	The addition of SPECT/CT showed an increase in specificity. [6]
Positive Predictive Value with SPECT/CT	89.5%	[6]
Overall Accuracy (Planar Scintigraphy)	47% to 94%	Varies across different studies for differentiating adenoma from hyperplasia. [4]
Correct Lesion Identification	77%	In a study of 26 patients undergoing suppression scintiscans. [7]

Experimental Protocols

Patient Preparation

- **Medication Review:** Certain medications that can interfere with the renin-angiotensin-aldosterone system should be discontinued prior to the study. This includes spironolactone, eplerenone, amiloride, potassium-wasting diuretics, and potentially others. The specific washout period should be determined by a clinician.
- **Thyroid Blockade:** To prevent the uptake of free radioiodine by the thyroid gland, administer a saturated solution of potassium iodide (SSKI) or Lugol's solution. This should begin 1-2 days prior to the administration of NP-59 and continue for the duration of the imaging study.
- **Bowel Preparation:** A laxative may be prescribed to reduce interfering background activity from the bowel.

Dexamethasone Suppression Protocol

The goal of dexamethasone administration is to suppress pituitary ACTH secretion, thereby reducing NP-59 uptake in normal and hyperplastic adrenal tissue.

- **Regimen:** Administer dexamethasone orally. A common regimen is 4 mg per day, given in divided doses (e.g., 1 mg every 6 hours).[8] Other protocols might use 0.5 mg every 6 hours for up to 7 days.[9]
- **Duration:** Dexamethasone is typically started 2-7 days before the injection of NP-59 and continued throughout the imaging period.[8][10]

NP-59 Administration and Imaging

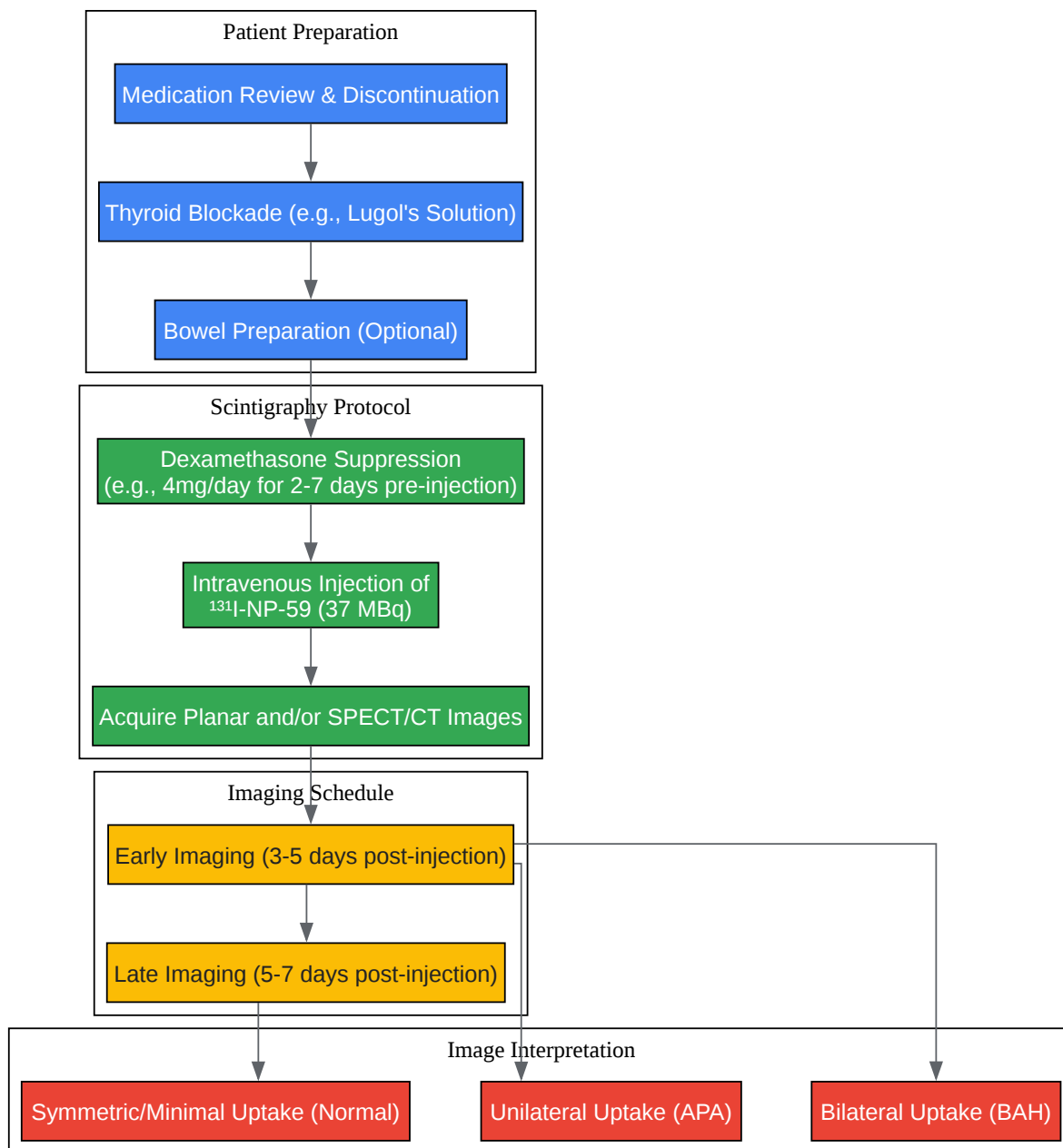
- **Radiopharmaceutical:** ^{131}I -6 β -iodomethyl-19-norcholesterol (NP-59).
- **Dose:** The typical administered activity is 37 MBq (1 mCi).[11]
- **Administration:** Administer intravenously.
- **Imaging Schedule:**
 - Initial images are typically acquired 3 to 5 days post-injection.

- Delayed imaging may be performed at 5 to 7 days post-injection.[8][10]
- Imaging Technique:
 - Planar scintigraphy of the adrenal glands is the standard technique.
 - SPECT/CT can be performed to improve localization and diagnostic accuracy by providing anatomical context to the functional data.[1][2][3]

Image Interpretation

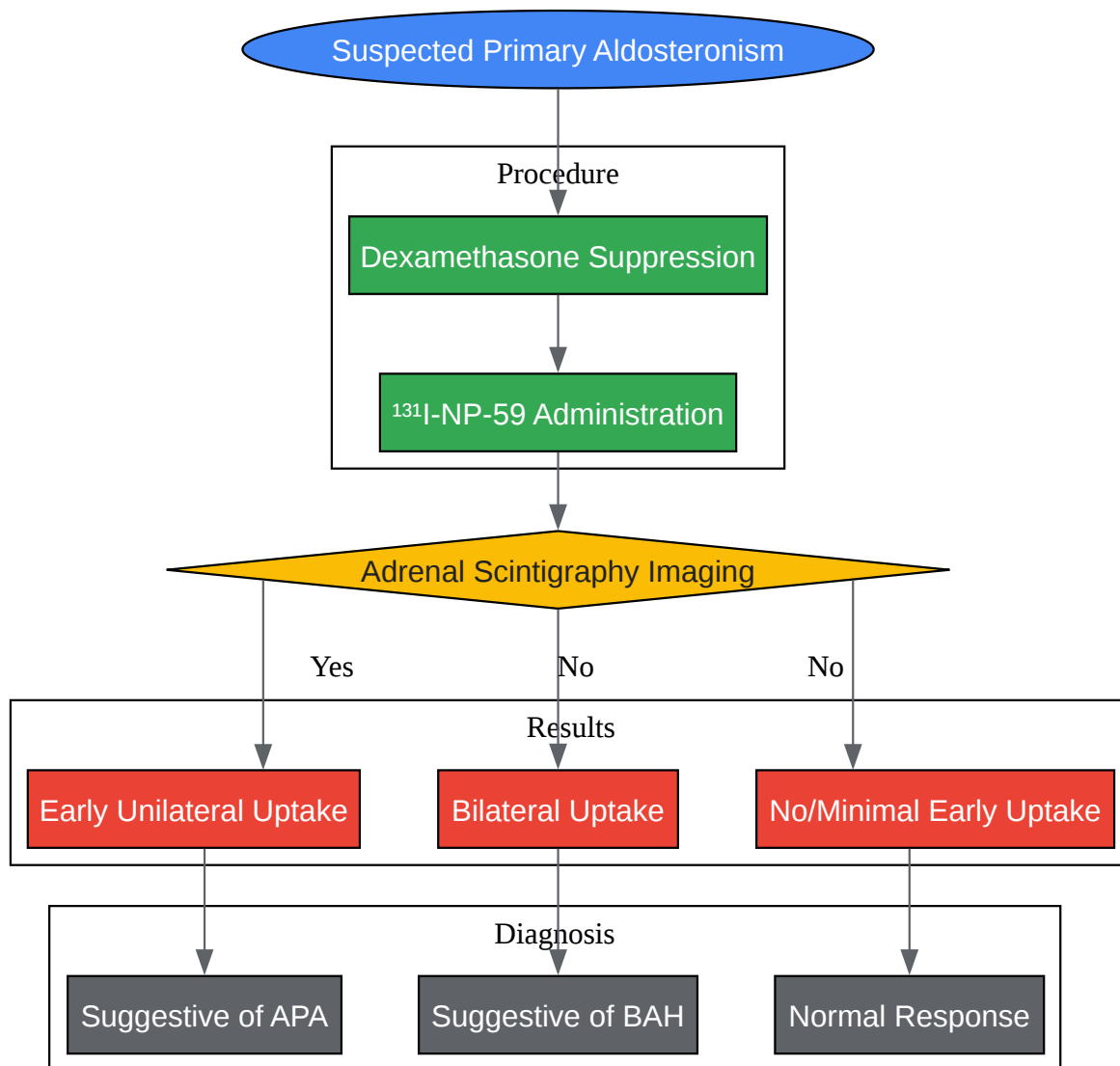
- Aldosterone-Producing Adenoma (APA): Early, unilateral visualization of NP-59 uptake at the site of the adenoma, with suppression of uptake in the contralateral gland.[7]
- Bilateral Adrenal Hyperplasia (BAH): Typically shows bilateral uptake of NP-59, which may be symmetrical or asymmetrical.[7] In some cases, uptake may not be visualized until later images.
- Normal Adrenals: With adequate dexamethasone suppression, there should be minimal to no visualization of the adrenal glands in the early imaging phase (3-5 days). Faint, symmetric uptake may become visible on later images (5-7 days).[10]

Diagrams



[Click to download full resolution via product page](#)

Caption: Experimental Workflow for NP-59 Adrenal Scintigraphy.



[Click to download full resolution via product page](#)

Caption: Diagnostic Logic of NP-59 Scintigraphy in Primary Aldosteronism.

Limitations and Considerations

- False-Negative Results: Small adenomas may yield false-negative results, as the uptake of NP-59 has been shown to correlate with adenoma volume.[5]

- Availability: NP-59 scintigraphy is a specialized procedure and may not be routinely available in all nuclear medicine departments.[11]
- Adrenal Venous Sampling (AVS): AVS is often considered the gold standard for lateralizing aldosterone secretion, particularly when imaging results are equivocal or discordant with clinical findings. NP-59 scintigraphy can be a useful alternative when AVS is contraindicated, unsuccessful, or the results are inconclusive.[1]
- Radiation Exposure: As with any nuclear medicine procedure, there is exposure to ionizing radiation. The effective dose for ^{131}I -Norcholesterol is reported to be 1.8 mSv/MBq.[4]

Conclusion

19-Iodocholesterol 3-acetate (NP-59) scintigraphy with dexamethasone suppression is a well-established functional imaging modality for the investigation of primary aldosteronism. It plays a significant role in the preoperative localization of aldosterone-producing adenomas, thereby guiding therapeutic decisions. While it has limitations, its non-invasive nature makes it a valuable tool in the diagnostic workup, especially when combined with SPECT/CT or when adrenal venous sampling is not feasible.

Need Custom Synthesis?

BenchChem offers custom synthesis for rare earth carbides and specific isotopic labeling.

Email: info@benchchem.com or [Request Quote Online](#).

References

1. emedicine.medscape.com [emedicine.medscape.com]
2. Diagnosis of primary aldosteronism in chronic kidney disease by I-131 NP-59 SPECT/CT imaging - PubMed [pubmed.ncbi.nlm.nih.gov]
3. researchgate.net [researchgate.net]
4. European Nuclear Medicine Guide [nucmed-guide.app]
5. Iodomethylnorcholesterol uptake in an aldosteronoma shown by dexamethasone-suppression scintigraphy: relationship to adenoma size and functional activity - PubMed [pubmed.ncbi.nlm.nih.gov]

- 6. Diagnostic value of adrenal iodine-131 6-beta-iodomethyl-19-norcholesterol scintigraphy for primary aldosteronism: a retrospective study at a medical center in North Taiwan - PubMed [pubmed.ncbi.nlm.nih.gov]
- 7. Adrenal imaging with 131I-19-iodocholesterol in the diagnostic evaluation of patients with aldosteronism - PubMed [pubmed.ncbi.nlm.nih.gov]
- 8. [Adrenal cortex scintigraphy with and without dexamethasone suppression in the study of primary aldosteronism] - PubMed [pubmed.ncbi.nlm.nih.gov]
- 9. nbt.nhs.uk [nbt.nhs.uk]
- 10. jnm.snmjournals.org [jnm.snmjournals.org]
- 11. Primary Aldosteronism Workup: Approach Considerations, Screening (First-Tier) Tests, Confirmatory (Second-Tier) Tests [emedicine.medscape.com]
- To cite this document: BenchChem. [Application of 19-Iodocholesterol 3-acetate in Primary Aldosteronism Research and Diagnosis]. BenchChem, [2025]. [Online PDF]. Available at: [https://www.benchchem.com/product/b1208695#application-of-19-iodocholesterol-3-acetate-in-primary-aldosteronism-research]

Disclaimer & Data Validity:

The information provided in this document is for Research Use Only (RUO) and is strictly not intended for diagnostic or therapeutic procedures. While BenchChem strives to provide accurate protocols, we make no warranties, express or implied, regarding the fitness of this product for every specific experimental setup.

Technical Support: The protocols provided are for reference purposes. Unsure if this reagent suits your experiment? [[Contact our Ph.D. Support Team for a compatibility check](#)]

Need Industrial/Bulk Grade? [Request Custom Synthesis Quote](#)

BenchChem

Our mission is to be the trusted global source of essential and advanced chemicals, empowering scientists and researchers to drive progress in science and industry.

Contact

Address: 3281 E Guasti Rd

Ontario, CA 91761, United States

Phone: (601) 213-4426

Email: info@benchchem.com

