

# Application Notes and Protocols for a Large Animal Model of Syndesmotic Injury

**Author:** BenchChem Technical Support Team. **Date:** December 2025

## Compound of Interest

Compound Name: SQ 27786

Cat. No.: B1681082

[Get Quote](#)

These comprehensive application notes and protocols are designed for researchers, scientists, and drug development professionals to establish a robust and reproducible large animal model for studying syndesmotic injuries. This model is crucial for investigating the pathophysiology of high ankle sprains, evaluating novel therapeutic interventions, and testing new fixation devices. The sheep is recommended as the primary animal model due to its anatomical and biomechanical similarities to the human ankle joint, as well as its docile nature and ease of handling in a research setting.<sup>[1]</sup>

## Animal Model Selection and Rationale

The ovine (sheep) model is a well-established and translational model for orthopedic research.<sup>[1]</sup> Key advantages include:

- **Anatomical Similarity:** The bone and ligamentous structures of the sheep carpus bear resemblance to the human distal tibiofibular syndesmosis.<sup>[1]</sup>
- **Biomechanical Equivalence:** The loading patterns and forces experienced at the sheep carpal joint are comparable to the human ankle syndesmosis during ambulation.<sup>[1]</sup>
- **Size and Weight:** The size of the sheep allows for the use of human-sized surgical implants and fixation devices, facilitating direct translation of research findings.
- **Temperament:** Sheep are generally placid animals, making them easier to manage in a laboratory setting compared to other large animals.

## Experimental Protocols

### Surgical Protocol: Creation of Syndesmotic Injury

This protocol details the surgical procedure for creating a unilateral syndesmotic injury in a skeletally mature sheep.

#### 2.1.1. Pre-operative Preparation:

- **Animal Selection:** Use skeletally mature female sheep (e.g., Suffolk or Dorset breed), weighing between 50-70 kg.
- **Acclimatization:** Allow animals to acclimate to the facility for at least one week prior to surgery.
- **Fasting:** Withhold food for 12-24 hours and water for 8-12 hours before surgery to prevent regurgitation and aspiration during anesthesia.
- **Anesthesia and Analgesia:**
  - Administer a pre-operative sedative (e.g., xylazine).
  - Induce general anesthesia using an intravenous agent (e.g., ketamine and diazepam).
  - Maintain anesthesia with an inhalant anesthetic (e.g., isoflurane) delivered via an endotracheal tube.
  - Provide pre-emptive analgesia with a non-steroidal anti-inflammatory drug (NSAID) (e.g., meloxicam) and an opioid (e.g., buprenorphine) to manage pain.[\[2\]](#)[\[3\]](#)

#### 2.1.2. Surgical Procedure:

- **Positioning:** Place the sheep in lateral recumbency with the operative limb (forelimb) positioned uppermost.
- **Aseptic Preparation:** Shave the surgical site (carpal region) and prepare the skin using a standard aseptic technique (e.g., chlorhexidine and alcohol scrubs). Drape the surgical area.
- **Surgical Approach:** Make a longitudinal incision over the dorsal aspect of the carpus.

- **Ligament Transection:** Carefully dissect through the subcutaneous tissue and fascia to expose the dorsal carpal ligaments. Identify and transect the dorsal and interosseous ligaments between the distal carpal bones, mimicking a syndesmotic injury.[1][4]
- **Wound Closure:** Close the fascial layers with absorbable sutures and the skin with non-absorbable sutures or surgical staples.
- **Post-operative Radiographs:** Obtain immediate post-operative radiographs to confirm the joint space widening and document the initial injury.

## Post-operative Care and Pain Management

Effective post-operative care is critical for animal welfare and the success of the study.

- **Recovery from Anesthesia:** Monitor the animal closely during recovery until it is fully conscious and able to maintain sternal recumbency.
- **Pain Management:**
  - Continue NSAID administration for 3-5 days post-operatively.[2][3]
  - Administer additional opioid analgesics as needed based on pain scoring (e.g., grimace scale, behavioral observation).[5]
  - Consider a multimodal approach, which may include local anesthetic blocks or epidural analgesia for more severe pain.[3][6]
- **Wound Care:**
  - Inspect the surgical incision daily for signs of infection (redness, swelling, discharge).[7]
  - Keep the incision clean and dry. An Elizabethan collar may be necessary to prevent the animal from licking or chewing at the sutures.[7]
- **Activity Restriction:**
  - House the animal in a small pen to restrict movement for the first 2-4 weeks.[1][8]

- Prevent running, jumping, or climbing.
- After the initial restriction period, gradually increase activity in a controlled manner.

## Outcome Measures and Assessment Protocols

A combination of imaging, biomechanical, and histological assessments should be used to evaluate ligament healing and joint stability.

### Radiographic Assessment Protocol

Radiographs are used to assess the integrity of the syndesmosis and monitor healing over time.

- Imaging Schedule: Obtain radiographs immediately post-operatively and at specified time points (e.g., 2, 4, 8, and 12 weeks) post-injury.
- Radiographic Views:
  - Anteroposterior (AP) View: To measure the tibiofibular clear space. A value greater than 5.3 mm is often indicative of syndesmotic injury in humans and can be adapted for the sheep model.[\[9\]](#)
  - Mortise View: To assess the medial clear space. A value greater than 4-5 mm can suggest deltoid ligament involvement and instability.[\[9\]](#)
  - Lateral View: To evaluate for anteroposterior displacement of the fibula relative to the tibia.
- Measurements:
  - Tibiofibular Clear Space: The distance between the medial border of the fibula and the lateral border of the posterior tibia.[\[9\]](#)
  - Tibiofibular Overlap: The amount of overlap between the anterior tibial tubercle and the anterior aspect of the fibula. A decreased overlap can indicate syndesmotic widening.[\[9\]](#)
  - Medial Clear Space: The distance between the medial border of the talus and the lateral border of the medial malleolus.

## Biomechanical Testing Protocol

Biomechanical testing provides quantitative data on the stability of the syndesmosis.

- Specimen Preparation:
  - At the study endpoint, euthanize the animal and harvest the entire carpal joint.
  - Dissect away all soft tissues, leaving the syndesmotic ligaments intact.
  - Pot the proximal and distal ends of the bones in a suitable material (e.g., polymethylmethacrylate) for mounting in a materials testing machine.
- Testing Modalities:
  - Rotational Testing: Apply an external rotation torque to the foot/distal carpus while fixing the tibia/proximal carpus. Measure the resulting angular displacement.
  - Translational Testing (Diastasis): Apply a lateral force to the fibula/lateral carpal bone and measure the displacement between the two bones.
- Data Analysis: Calculate the rotational and translational stiffness of the joint. Compare the values between the injured and a contralateral control limb.

## Histological Analysis Protocol

Histology provides a qualitative and semi-quantitative assessment of the ligament healing process.

- Tissue Harvesting and Processing:
  - Harvest the syndesmotic ligaments and surrounding bone at the study endpoint.
  - Fix the tissues in 10% neutral buffered formalin.
  - Decalcify the bony portions if necessary.
  - Embed the tissues in paraffin and section them for staining.

- **Staining:**
  - Hematoxylin and Eosin (H&E): For general assessment of tissue morphology, cellularity, and inflammation.
  - Masson's Trichrome: To visualize collagen fibers and assess their organization.
- **Histological Scoring:** Use a semi-quantitative scoring system to evaluate ligament healing based on the following parameters:
  - Collagen Fiber Organization: (0: normal, parallel fibers; 4: completely disorganized).
  - Cellularity: (0: normal cellularity; 4: hypercellular).
  - Vascularity: (0: normal vascularity; 4: hypervascular).
  - Inflammation: (0: no inflammatory cells; 4: severe inflammation).

## Data Presentation

Summarize all quantitative data in clearly structured tables for easy comparison between experimental groups and time points.

Table 1: Radiographic Measurements (in mm)

| Time Point | Tibiofibular<br>Clear Space<br>(Injured) | Tibiofibular<br>Clear Space<br>(Control) | Medial Clear<br>Space<br>(Injured) | Medial Clear<br>Space<br>(Control) |
|------------|--|--|------------------------------------|------------------------------------|
| Post-op    |  |  |                                    |                                    |
| 2 Weeks    |  |  |                                    |                                    |
| 4 Weeks    |  |  |                                    |                                    |
| 8 Weeks    |  |  |                                    |                                    |
| 12 Weeks   |  |  |                                    |                                    |

Table 2: Biomechanical Testing Results

| Group   | Rotational Stiffness<br>(Nm/degree) | Translational Stiffness<br>(N/mm) |
|---------|-------------------------------------|-----------------------------------|
| Injured |                                     |                                   |
| Control |                                     |                                   |

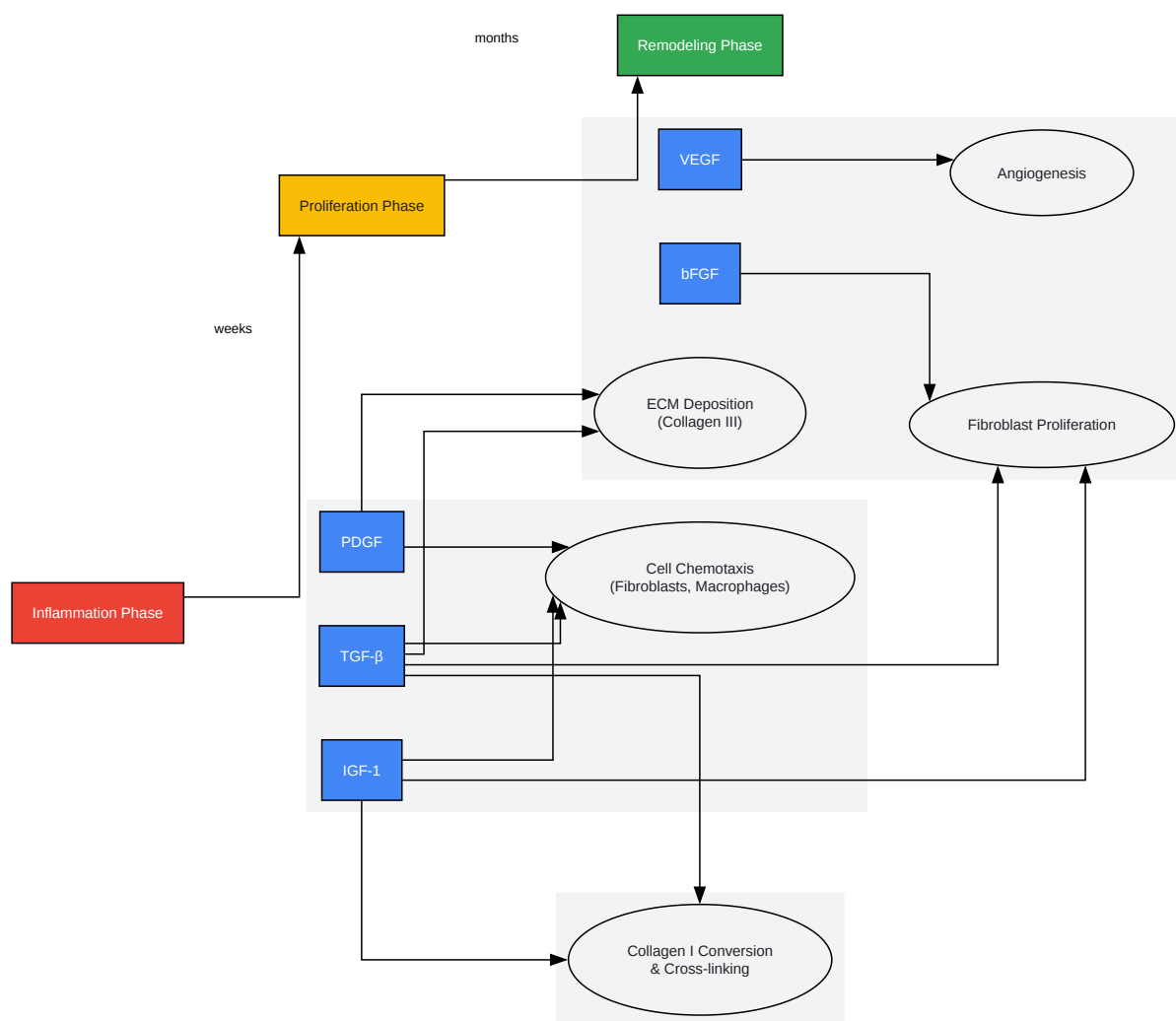
Table 3: Histological Scores (Mean ± SD)

| Group   | Collagen<br>Organization | Cellularity | Vascularity | Inflammation | Total Score |
|---------|--------------------------|-------------|-------------|--------------|-------------|
| Injured |                          |             |             |              |             |
| Control |                          |             |             |              |             |

## Visualizations

### Signaling Pathways in Ligament Healing

The healing of syndesmotic ligaments is a complex process involving a cascade of cellular and molecular events. Key growth factors orchestrate the three main phases of healing: inflammation, proliferation, and remodeling.[\[10\]](#)[\[11\]](#)[\[12\]](#)[\[13\]](#)[\[14\]](#)



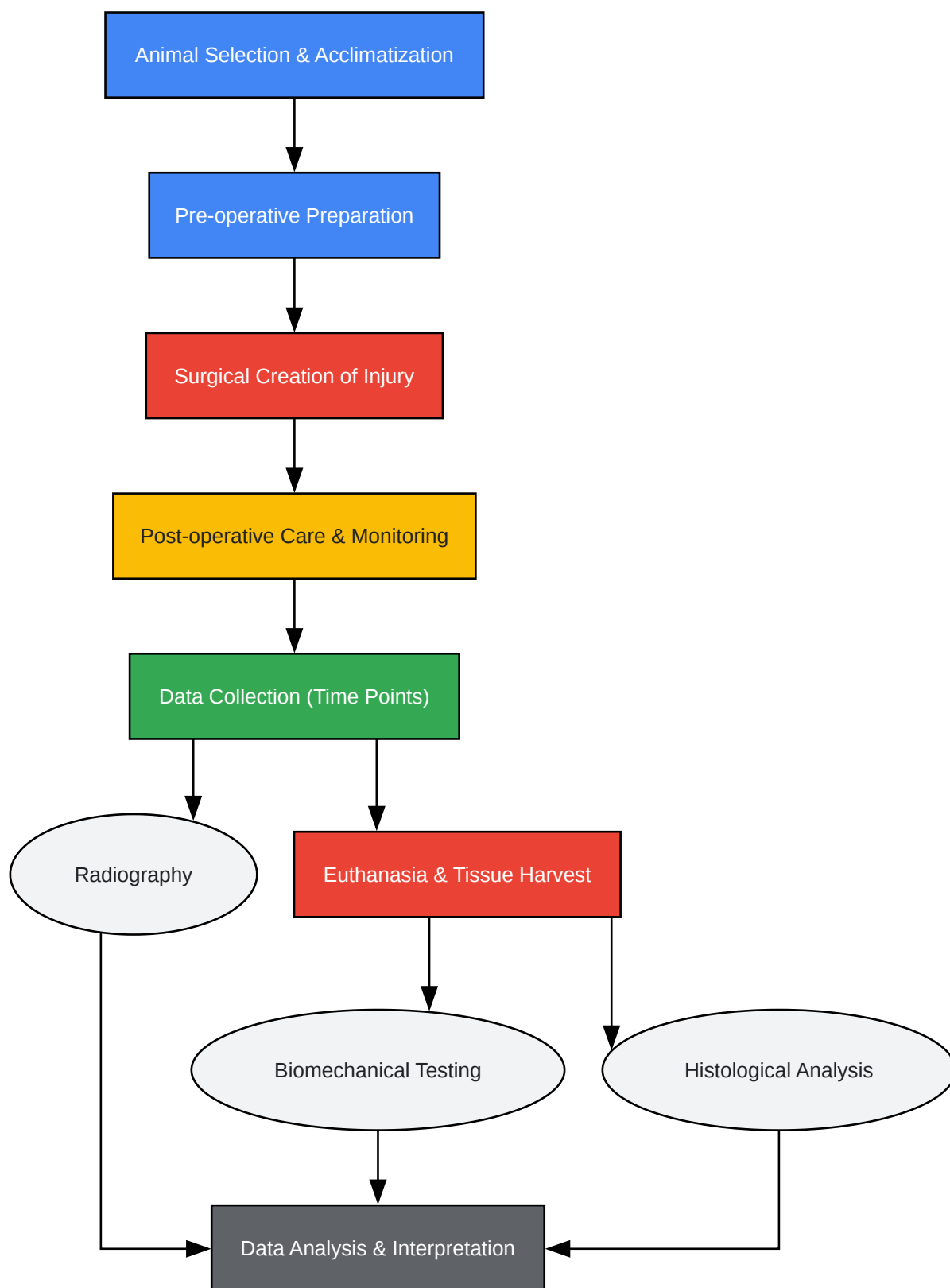
[Click to download full resolution via product page](#)

Caption: Signaling pathways in ligament healing.



## Experimental Workflow

The following diagram illustrates the logical flow of the experimental procedures, from animal selection to data analysis.



[Click to download full resolution via product page](#)

Caption: Experimental workflow diagram.

**Need Custom Synthesis?**

BenchChem offers custom synthesis for rare earth carbides and specific isotopic labeling.

Email: [info@benchchem.com](mailto:info@benchchem.com) or [Request Quote Online](#).

## References

- 1. [advancedvetcarenm.com](https://advancedvetcarenm.com) [[advancedvetcarenm.com](https://advancedvetcarenm.com)]
- 2. An Exploration of Analgesia Options for Australian Sheep - PMC [[pmc.ncbi.nlm.nih.gov](https://pubmed.ncbi.nlm.nih.gov)]
- 3. - NADIS [[nadis.org.uk](https://nadis.org.uk)]
- 4. Validation of a histologic scoring system for the examination of quality of tendon graft to bone tunnel healing in anterior cruciate ligament reconstruction - PubMed [[pubmed.ncbi.nlm.nih.gov](https://pubmed.ncbi.nlm.nih.gov)]
- 5. Clinical validation of the Unesp-Botucatu acute pain scale in sheep undergoing orthopedic surgery - PMC [[pmc.ncbi.nlm.nih.gov](https://pubmed.ncbi.nlm.nih.gov)]
- 6. [mvmj.researchcommons.org](https://mvmj.researchcommons.org) [[mvmj.researchcommons.org](https://mvmj.researchcommons.org)]
- 7. Essential Post-Surgery Care Tips for a Safe and Comfortable Pet Recovery [[tuckahoeanimalhospital.com](https://tuckahoeanimalhospital.com)]
- 8. Caring for Your Pet After Orthopedic Surgery [[arkanimalvets.com](https://arkanimalvets.com)]
- 9. [radiopaedia.org](https://radiopaedia.org) [[radiopaedia.org](https://radiopaedia.org)]
- 10. The roles of growth factors in tendon and ligament healing - PubMed [[pubmed.ncbi.nlm.nih.gov](https://pubmed.ncbi.nlm.nih.gov)]
- 11. Frontiers | Growth factors in the treatment of Achilles tendon injury [[frontiersin.org](https://frontiersin.org)]
- 12. [karger.com](https://karger.com) [[karger.com](https://karger.com)]
- 13. Wound healing - Wikipedia [[en.wikipedia.org](https://en.wikipedia.org)]
- 14. Current progress in growth factors and extracellular vesicles in tendon healing - PMC [[pmc.ncbi.nlm.nih.gov](https://pubmed.ncbi.nlm.nih.gov)]
- To cite this document: BenchChem. [Application Notes and Protocols for a Large Animal Model of Syndesmotic Injury]. BenchChem, [2025]. [Online PDF]. Available at: [<https://www.benchchem.com/product/b1681082#developing-a-large-animal-model-for-syndesmotic-injury-research>]

**Disclaimer & Data Validity:**

The information provided in this document is for Research Use Only (RUO) and is strictly not intended for diagnostic or therapeutic procedures. While BenchChem strives to provide accurate protocols, we make no warranties, express or implied, regarding the fitness of this product for every specific experimental setup.

**Technical Support:** The protocols provided are for reference purposes. Unsure if this reagent suits your experiment? [[Contact our Ph.D. Support Team for a compatibility check](#)]

**Need Industrial/Bulk Grade?** [Request Custom Synthesis Quote](#)

## BenchChem

Our mission is to be the trusted global source of essential and advanced chemicals, empowering scientists and researchers to drive progress in science and industry.

### Contact

Address: 3281 E Guasti Rd  
Ontario, CA 91761, United States  
Phone: (601) 213-4426  
Email: [info@benchchem.com](mailto:info@benchchem.com)