

Application Notes and Protocols for Transvaginal Sonography in Uterine Fibroid Characterization

Author: BenchChem Technical Support Team. **Date:** December 2025

Compound of Interest

Compound Name: FR 76830

Cat. No.: B1674034

[Get Quote](#)

For Researchers, Scientists, and Drug Development Professionals

These application notes provide a comprehensive overview of transvaginal sonography (TVS) techniques for the detailed assessment of uterine fibroid characteristics. The included protocols are designed to offer standardized methodologies for acquiring high-quality, reproducible data essential for clinical research and drug development.

Standard 2D and 3D Transvaginal Sonography for Fibroid Mapping

Two-dimensional (2D) TVS is the primary imaging modality for detecting and measuring uterine fibroids, while three-dimensional (3D) TVS offers superior visualization of the fibroid's location, size, and relationship with the endometrium and uterine walls.^{[1][2][3][4]} 3D reconstructions, particularly in the coronal plane, are invaluable for accurate fibroid mapping and classification according to the International Federation of Gynecology and Obstetrics (FIGO) system.^{[2][5]}

Key Characteristics Assessed

- **Number:** The total count of fibroids. 3D TVS is more accurate than 2D TVS in differentiating closely located fibroids.^[1]

- Size: Measured in three orthogonal dimensions (length, width, height) to calculate volume, typically using the ellipsoid formula ($\pi \times (d1 \times d2 \times d3)/6$).[\[6\]](#)
- Location: Described as anterior, posterior, fundal, or lateral.[\[7\]](#)
- FIGO Classification: Categorization based on the fibroid's relationship to the endometrium and serosa.[\[2\]](#)[\[5\]](#)[\[7\]](#)
- Echogenicity: Typically, fibroids appear as well-defined, hypoechoic, and heterogeneous masses.[\[7\]](#)[\[8\]](#) Degenerative changes can alter this appearance, showing calcifications (hyperechoic foci) or cystic areas.[\[9\]](#)
- Acoustic Shadowing: Often observed at the edges of the lesion.[\[7\]](#)

Experimental Protocol: 2D/3D Transvaginal Sonography

1.2.1. Patient Preparation

- The patient should empty her bladder immediately before the examination to optimize image quality.[\[10\]](#)
- Position the patient in the dorsal lithotomy position.[\[10\]](#)
- Obtain informed consent and explain the procedure.

1.2.2. Equipment and Settings

- Ultrasound system equipped with a high-frequency (4–9 MHz) transvaginal transducer.[\[9\]](#)[\[11\]](#)
- Cover the transducer with a sterile probe cover and apply ultrasound gel.[\[10\]](#)[\[12\]](#)
- Optimize imaging settings (e.g., frequency, gain, focus) for pelvic imaging. For larger uteri, a lower frequency "penetration mode" may be necessary.[\[9\]](#)

1.2.3. Imaging Procedure

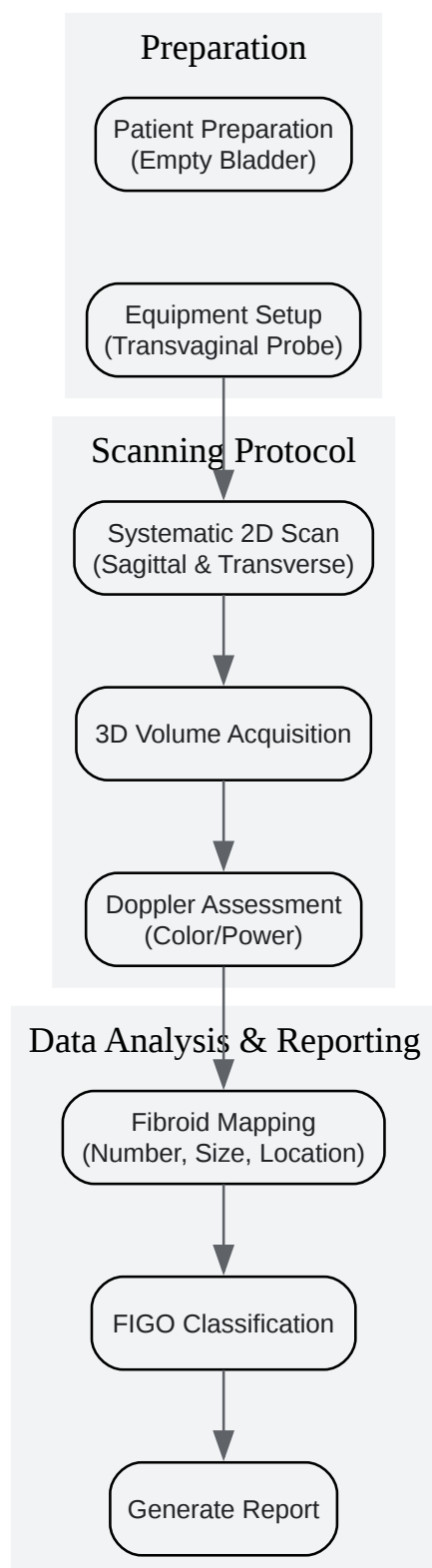
- Gently insert the transducer into the vagina.[\[12\]](#)
- Perform a systematic scan of the uterus in both sagittal and transverse planes.[\[3\]](#)

- Identify and document all fibroids, measuring each in three dimensions.
- For 3D imaging, acquire a volume dataset of the uterus by performing a sagittal or transverse sweep.[\[3\]](#)
- Reconstruct the 3D volume to visualize the coronal plane, which is crucial for assessing the relationship between fibroids and the endometrial cavity.[\[1\]](#)
- Utilize fibroid mapping software, if available, to create a 3D reconstruction of the uterus with the mapped locations and sizes of all fibroids.[\[3\]](#)[\[5\]](#)

1.2.4. Data Analysis and Reporting

- Record the number, size, and location of each fibroid.
- Classify each fibroid according to the FIGO classification system (Types 0-8).[\[7\]](#)
- Describe the sonographic characteristics of each fibroid, including echogenicity and any degenerative features.
- Report the overall uterine volume.[\[7\]](#)

Visualization of the General Diagnostic Workflow



[Click to download full resolution via product page](#)

Caption: General workflow for transvaginal ultrasound assessment of uterine fibroids.

Doppler Sonography for Vascularity Assessment

Color and power Doppler ultrasound are used to evaluate the vascularity of uterine fibroids.[4] [13] This information is crucial for predicting fibroid growth, assessing the risk of bleeding during surgery, and monitoring the response to treatments like uterine artery embolization (UAE).[13] A common finding is the presence of circumferential vascularity around the fibroid. [7]

Key Characteristics Assessed

- **Vascularity Pattern:** Typically peripheral, with vessels surrounding the fibroid.[13] Some fibroids may also show internal vascularity.
- **Vascularization Index:** A quantitative measure of blood flow within the fibroid, often obtained using 3D power Doppler.[14]
- **Doppler Indices:** Pulsatility Index (PI) and Resistance Index (RI) of perifibroid and intrafibroid arteries can provide information about blood flow impedance.

Experimental Protocol: Doppler Sonography

2.2.1. Patient Preparation

- Follow the same patient preparation protocol as for standard 2D/3D TVS.

2.2.2. Equipment and Settings

- Ultrasound system with color Doppler and power Doppler capabilities.
- Optimize Doppler settings to be sensitive to low-velocity flow. This includes adjusting the pulse repetition frequency (PRF), color gain, and wall filter.
- Create a standardized preset for fibroid assessment to ensure consistency.[14]

2.2.3. Imaging Procedure

- After identifying a fibroid in B-mode, activate color or power Doppler.

- Map the vascularity around and within the fibroid. Document the pattern of blood flow (e.g., peripheral, central, or both).^[13]
- Place the pulsed-wave Doppler gate over a perifibroid or intrafibroid artery to obtain a spectral waveform.
- Measure the Doppler indices (PI and RI) from the waveform.
- For 3D power Doppler, acquire a volume of the fibroid and use software to calculate the vascularization index.

2.2.4. Data Analysis and Reporting

- Describe the vascularity of each fibroid as avascular, hypovascular, isovascular, or hypervascular.^[7]
- Report the pattern of vascularization.
- Record the measured Doppler indices for perifibroid and intrafibroid arteries.

Quantitative Data: Doppler Indices in Uterine Fibroids

| Artery Location | Pulsatility Index (PI) | Resistance Index (RI) |
|---------------------|------------------------|-----------------------|
| Perifibroid Artery | Higher | Higher |
| Intrafibroid Artery | Lower | Lower |

Note: Perifibroid arteries generally exhibit higher impedance (higher PI and RI) compared to intrafibroid arteries.^[13] The degree of vascularity tends to increase with fibroid volume.^[13]

Sonoelastography for Tissue Stiffness Evaluation

Sonoelastography is an advanced technique that assesses tissue stiffness.[15] Uterine fibroids are typically harder than the surrounding myometrium due to their composition of smooth muscle and excess extracellular matrix.[11][16] This technique can help differentiate fibroids from adenomyosis, which is generally softer.[11][15][16]

Key Characteristics Assessed

- **Color Pattern:** On qualitative elastograms, fibroids typically appear as dark blue or purple, indicating stiffer tissue.[11][15]
- **Strain Ratio (SR):** A semi-quantitative measure comparing the stiffness of the fibroid to the adjacent normal myometrium. Fibroids have a significantly higher strain ratio than adenomyosis.[17]

Experimental Protocol: Strain-Ratio Elastography

3.2.1. Patient Preparation

- Follow the same patient preparation protocol as for standard 2D/3D TVS.

3.2.2. Equipment and Settings

- Ultrasound system with elastography software (e.g., ElastoScan™) and a compatible transvaginal transducer.[11]
- Use a color map where blue/purple represents stiff tissue and red/yellow represents soft tissue.[11][17]

3.2.3. Imaging Procedure

- Obtain a clear 2D image of the fibroid and surrounding myometrium.
- Activate the elastography mode.
- Apply light, rhythmic pressure with the transducer to generate the elastogram. A "steady-state" image should be achieved, showing a stable and reproducible color pattern.[11]
- Once a high-quality elastogram is obtained, freeze the image.

- Place two regions of interest (ROIs): one within the target fibroid and another in an area of adjacent normal myometrium.[17]
- The software will automatically calculate the strain ratio.

3.2.4. Data Analysis and Reporting

- Describe the color pattern of the fibroid on the elastogram.
- Report the mean and maximum strain ratio values.
- Compare the findings with established cutoff values to differentiate between fibroids and adenomyosis.

Quantitative Data: Strain Ratios for Differentiating Fibroids and Adenomyosis

| Condition | Mean Strain Ratio (SR) | Max Strain Ratio (SR) |
|------------------|------------------------|-----------------------|
| Uterine Fibroids | Lower (e.g., < 7.71) | Lower (e.g., < 8.91) |
| Adenomyosis | Higher (e.g., > 7.71) | Higher (e.g., > 8.91) |

Note: These are example cutoff values from one study and may vary based on equipment and patient population. Adenomyosis is significantly stiffer than fibroids in this context, which contradicts some other findings and highlights the need for standardized protocols.[17]

Another study suggests fibroids are stiffer than adenomyosis.[16]

Contrast-Enhanced Ultrasound (CEUS) for Microvascularization Assessment

Contrast-enhanced ultrasound (CEUS) uses microbubble contrast agents to visualize tissue perfusion in real-time. It provides detailed information about the microvasculature of fibroids, which is often not detectable with conventional Doppler.[18] CEUS is particularly useful for assessing fibroid viability before and after treatments like UAE and has shown good correlation with contrast-enhanced MRI.[19]

Key Characteristics Assessed

- **Enhancement Pattern:** Describes how the contrast agent perfuses the fibroid (e.g., peripheral rim enhancement, centripetal fill-in).[18][20]
- **Time to Enhancement:** The timing of fibroid enhancement relative to the surrounding myometrium.[20]
- **Degree of Enhancement:** The extent of contrast uptake within the fibroid, which indicates the degree of vascularization.

Experimental Protocol: Contrast-Enhanced Ultrasound

4.2.1. Patient Preparation

- Establish intravenous (IV) access for contrast agent administration.
- Obtain informed consent, explaining the use of a contrast agent.
- No other specific patient preparation is typically required.

4.2.2. Equipment and Settings

- Ultrasound system with contrast-specific imaging software.
- A second-generation ultrasound contrast agent (e.g., SonoVue®, Lumason®).[19][20]
- Set the mechanical index (MI) to a low value to prevent premature bursting of the microbubbles.

4.2.3. Imaging Procedure

- Obtain a stable 2D image of the target fibroid.
- Administer a bolus of the ultrasound contrast agent (e.g., 2.0 mL) via the IV line, followed by a saline flush.[\[19\]](#)
- Immediately start a timer and acquire a digital video clip (cineloop) of the fibroid for at least 2-3 minutes to capture the entire wash-in and wash-out phases.
- Observe and record the time to enhancement and the pattern of perfusion within the fibroid and the adjacent myometrium.

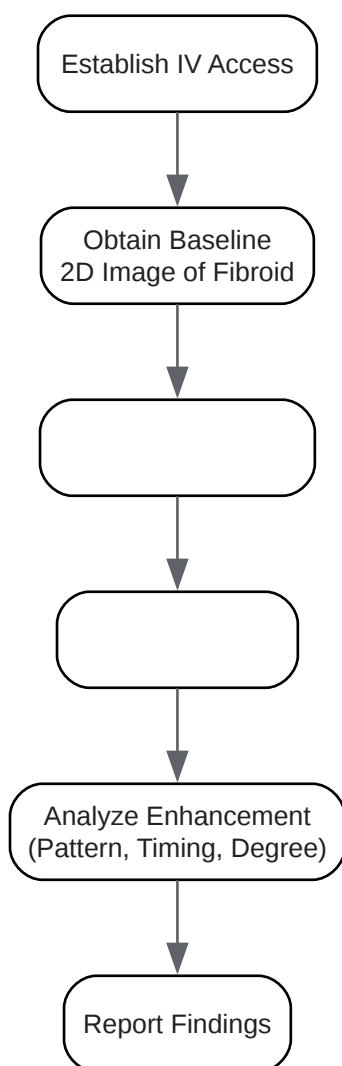
4.2.4. Data Analysis and Reporting

- Analyze the cineloops to describe the fibroid's vascular characteristics.
- Report the enhancement pattern (e.g., peripheral, centripetal, branching).[\[20\]](#)
- Document the timing of enhancement relative to the myometrium (e.g., fibroid enhances before, after, or simultaneously with the myometrium).[\[20\]](#)
- Characterize the fibroid as hypervascular or hypovascular based on the degree of enhancement.[\[19\]](#)
- For post-treatment evaluation (e.g., after UAE), assess for any residual enhancement, which would indicate treatment failure.

Quantitative Data: CEUS Findings in Uterine Fibroids (Pre-Embolization)

| CEUS Characteristic | Finding in a Cohort Study |
|--|--|
| Time to Enhancement | 66% of fibroids enhanced before the myometrium. [20] |
| Enhancement Pattern | 45.8% showed peripheral rim enhancement. [20] |
| 41.6% showed a branching pattern from a principal pedicle. [20] | |
| 12.6% showed enhancement from the center. [20] | |
| Data from a study of 40 women before uterine artery embolization. [20] | |

Visualization of the CEUS Workflow



[Click to download full resolution via product page](#)

Caption: Workflow for a contrast-enhanced ultrasound (CEUS) examination of a uterine fibroid.

Need Custom Synthesis?

BenchChem offers custom synthesis for rare earth carbides and specific isotopic labeling.

Email: info@benchchem.com or [Request Quote Online](#).

References

- 1. epos.myesr.org [epos.myesr.org]
- 2. researchgate.net [researchgate.net]

- 3. volusonclub.net [volusonclub.net]
- 4. Ultrasonography of uterine leiomyomas - PMC [pmc.ncbi.nlm.nih.gov]
- 5. Fibroid Mapping | GE HealthCare (United States) [gehealthcare.com]
- 6. Magnetic resonance imaging and transvaginal ultrasound for determining fibroid burden: implications for clinical research - PMC [pmc.ncbi.nlm.nih.gov]
- 7. Reporting of uterine fibroids on ultrasound examinations: an illustrated report template focused on surgical planning - PMC [pmc.ncbi.nlm.nih.gov]
- 8. cbmcb.org [cbmcb.org]
- 9. institutobernabeu.com [institutobernabeu.com]
- 10. Sonography Transvaginal Assessment, Protocols, and Interpretation - StatPearls - NCBI Bookshelf [ncbi.nlm.nih.gov]
- 11. images.samsung.com [images.samsung.com]
- 12. my.clevelandclinic.org [my.clevelandclinic.org]
- 13. Doppler sonography of perifibroid and intrafibroid arteries of uterine leiomyomas - PMC [pmc.ncbi.nlm.nih.gov]
- 14. How to use power Doppler ultrasound in transvaginal assessment of uterine fibroids - PubMed [pubmed.ncbi.nlm.nih.gov]
- 15. Real-time elastography for assessment of uterine disorders - PubMed [pubmed.ncbi.nlm.nih.gov]
- 16. Advances in the clinical application of ultrasound elastography in uterine imaging - PMC [pmc.ncbi.nlm.nih.gov]
- 17. Value of Strain-Ratio Elastography in the Diagnosis and Differentiation of Uterine Fibroids and Adenomyosis - PMC [pmc.ncbi.nlm.nih.gov]
- 18. researchgate.net [researchgate.net]
- 19. Evaluation of Uterine Fibroid Vascularity Using Contrast-Enhanced Ultrasound in Comparison with Contrast-Enhanced Magnetic Resonance Imaging - PubMed [pubmed.ncbi.nlm.nih.gov]
- 20. fibrome-info-france.org [fibrome-info-france.org]
- To cite this document: BenchChem. [Application Notes and Protocols for Transvaginal Sonography in Uterine Fibroid Characterization]. BenchChem, [2025]. [Online PDF]. Available at: [https://www.benchchem.com/product/b1674034#transvaginal-sonography-techniques-for-assessing-uterine-fibroid-characteristics]

Disclaimer & Data Validity:

The information provided in this document is for Research Use Only (RUO) and is strictly not intended for diagnostic or therapeutic procedures. While BenchChem strives to provide accurate protocols, we make no warranties, express or implied, regarding the fitness of this product for every specific experimental setup.

Technical Support: The protocols provided are for reference purposes. Unsure if this reagent suits your experiment? [[Contact our Ph.D. Support Team for a compatibility check](#)]

Need Industrial/Bulk Grade? [Request Custom Synthesis Quote](#)

BenchChem

Our mission is to be the trusted global source of essential and advanced chemicals, empowering scientists and researchers to drive progress in science and industry.

Contact

Address: 3281 E Guasti Rd
Ontario, CA 91761, United States
Phone: (601) 213-4426
Email: info@benchchem.com