

Application Notes and Protocols for Radiographic Evaluation of Sargentol Root Canal Fillings

Author: BenchChem Technical Support Team. **Date:** December 2025

Compound of Interest

Compound Name: Sargentol

Cat. No.: B15596442

[Get Quote](#)

For Researchers, Scientists, and Drug Development Professionals

Introduction

These application notes provide a framework for the radiographic evaluation of root canal fillings, with a specific focus on treatments utilizing **Sargentol**, a paraformaldehyde-containing root canal sealer. Radiographic analysis is a primary non-invasive method for assessing the technical quality and outcome of endodontic therapy.^{[1][2]} It allows for the evaluation of the filling's three-dimensional obturation of the root canal system and the subsequent response of the periapical tissues. While specific long-term radiographic outcome data for **Sargentol** is limited in contemporary literature, the evaluation principles remain consistent with other root canal filling materials. The success of a root canal treatment is often determined by clinical and radiographic findings.^{[3][4][5]}

Data Presentation

Due to a lack of specific quantitative data on the radiographic success rates of **Sargentol** from the provided search results, the following table summarizes common radiographic outcomes for root canal treatments in general. These metrics are essential for designing studies to evaluate **Sargentol** fillings.

Table 1: Summary of General Radiographic Outcomes for Root Canal Treatments

Radiographic Outcome	Success Rate/Incidence	Tooth Type/Study Population	Citation
Adequate Filling Length	89.88%	General patient pool, 10-year follow-up	[4]
81.4% (flush with apex)	Patients treated with Obtura II system	[5]	
32.6% (acceptable)	Senior dental students	[6]	
Underfilling	6.74%	General patient pool, 10-year follow-up	
12.7%	Patients treated with Obtura II system	[5]	
46.9% of failed treatments	Patients with endodontic treatment failure	[7]	
Overfilling (Extrusion)	3.37%	General patient pool, 10-year follow-up	
5.9%	Patients treated with Obtura II system	[5]	
13% of failed treatments	Patients with endodontic treatment failure	[7]	
Presence of Voids	Decreased sensitivity with radiopaque sealers	Ex vivo study on maxillary canines	
Periapical Healing (Complete)	35.3% (one-step obturation)	In vivo study in dogs	[9][10]
36.8% (with Ca(OH) ₂ medication)	In vivo study in dogs	[9][10]	
Periapical Healing (Improvement)	23.5% (one-step obturation)	In vivo study in dogs	

47.4% (with Ca(OH) ₂ medication)	In vivo study in dogs	[9][10]	
Overall Radiographic Success	92.13% (cumulative probability)	General patient pool, 10-year follow-up	[4]
89.5%	Dental students, 13.8-month follow-up	[3]	
75.4%	General patient pool, 6.3-year follow-up	[11]	

Experimental Protocols

The following are detailed methodologies for key experiments in the radiographic evaluation of root canal fillings. These can be adapted for studies on **Sargentol**.

Protocol 1: In Vivo Radiographic Evaluation of Periapical Healing

This protocol is adapted from a study on periapical repair following obturation of infected root canals.[9][10]

1. Subject Selection and Preoperative Radiographs:

- Select subjects (e.g., animal models or human patients) with teeth requiring root canal treatment due to pulp necrosis and evidence of periapical radiolucency.
- Obtain standardized preoperative periapical radiographs using a paralleling technique to ensure consistent imaging geometry for longitudinal comparison.[1]

2. Root Canal Treatment Procedure:

- Perform standard root canal preparation, including cleaning and shaping of the canals.
- For a comparative study, divide subjects into groups:
- Group A (**Sargentol**): Obturate the canals with **Sargentol** paste.
- Group B (Control): Obturate with a standard, well-documented material (e.g., gutta-percha with a non-paraformaldehyde sealer).

- Obtain immediate postoperative radiographs to assess the technical quality of the filling (length, density, and taper).

3. Follow-up and Radiographic Assessment:

- Schedule follow-up appointments at standardized intervals (e.g., 6 months, 1 year, and 2 years).
- At each follow-up, acquire standardized periapical radiographs.
- Blinded and calibrated examiners should evaluate the radiographs to minimize bias.
- Assess periapical healing based on a scoring index such as the Periapical Index (PAI).^[12]
^[13] Healing is categorized as:
- Complete Healing: Absence of a periapical radiolucency and reformation of the periodontal ligament space.
- Incomplete (Partial) Healing: Reduction in the size of the periapical radiolucency.
- Uncertain Healing: No change in the size of the periapical radiolucency.
- Failure: Increase in the size of the periapical radiolucency or appearance of a new lesion.

4. Statistical Analysis:

- Use appropriate statistical tests (e.g., Chi-square or Fisher's exact test) to compare the healing outcomes between the **Sargentol** and control groups.

Protocol 2: Ex Vivo Evaluation of Radiographic Filling Quality

This protocol is based on studies assessing the radiographic appearance of root canal fillings.
^[1]^[8]

1. Sample Preparation:

- Use extracted human teeth with single, straight canals.
- Prepare the root canals to a standardized apical size and taper.

2. Root Canal Obturation:

- Divide the teeth into experimental groups for different filling materials or techniques.
- Group A: Obturate with **Sargentol**.
- Group B (Control): Obturate with a standard material.

- To test the detection of defects, voids can be intentionally created in a subset of samples.

3. Radiographic Imaging:

- Obtain standardized buccolingual and mesiodistal radiographs using a paralleling technique.
[1]
- Include an aluminum step wedge in the radiographs for densitometric analysis.[14][15]

4. Radiographic Evaluation:

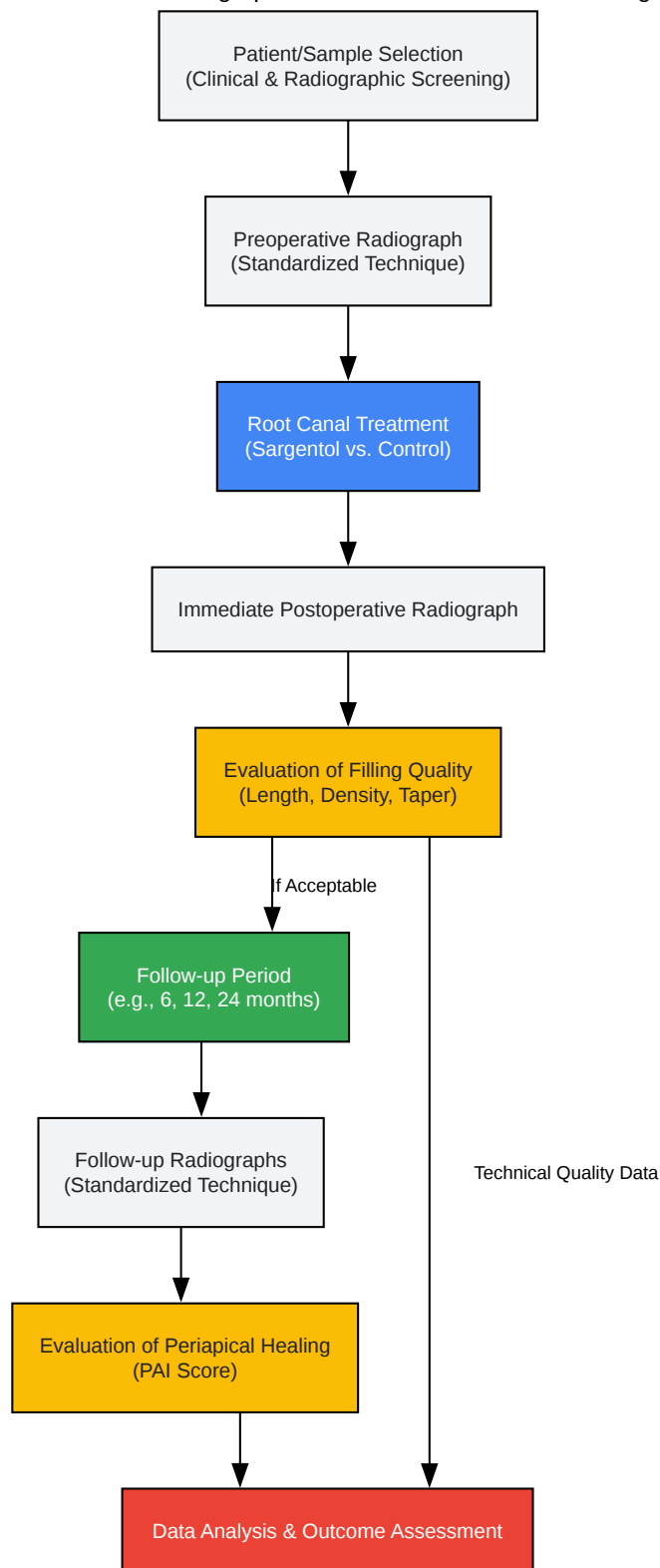
- Have calibrated examiners, blinded to the experimental groups, evaluate the radiographs for:
- Length: Distance of the filling from the radiographic apex.
- Density: Presence or absence of voids within the filling material.[6]
- Taper: Conformity of the filling to the prepared canal shape.
- The radiopacity of the filling material can be quantified by comparing its optical density to the aluminum step wedge.

5. Histological Correlation (Optional but Recommended):

- Following radiographic evaluation, section the teeth to histologically confirm the presence and size of any voids or the extent of material extrusion.

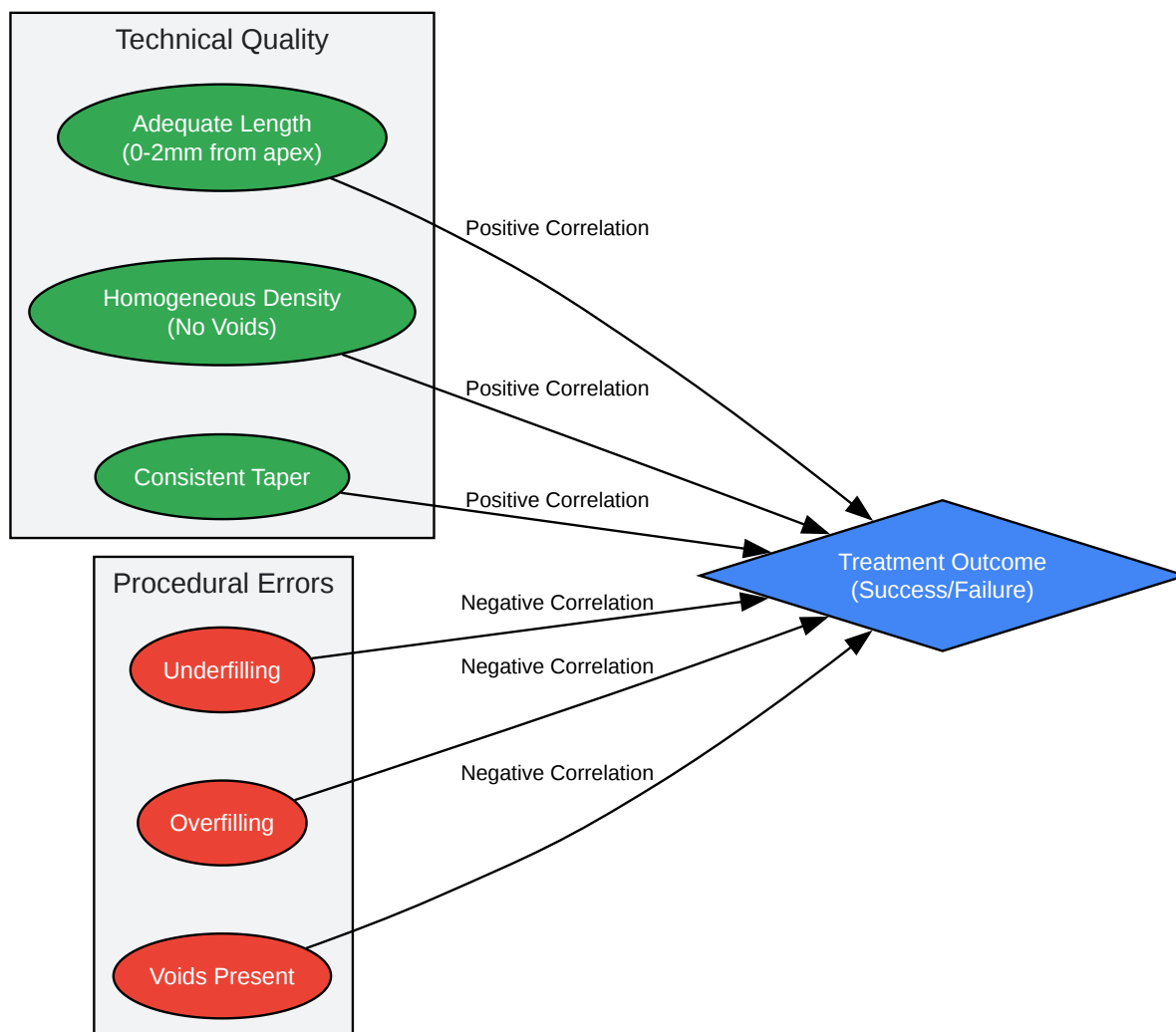
Mandatory Visualizations

Workflow for Radiographic Evaluation of Root Canal Fillings

[Click to download full resolution via product page](#)

Caption: Experimental workflow for in vivo radiographic evaluation.

Logical Relationship of Radiographic Criteria to Treatment Outcome



[Click to download full resolution via product page](#)

Caption: Relationship between radiographic quality and outcome.

Need Custom Synthesis?

BenchChem offers custom synthesis for rare earth carbides and specific isotopic labeling.

Email: info@benchchem.com or [Request Quote Online](#).

References

- 1. Influence of root canal sealer on the radiographic appearance of filling voids in maxillary single-rooted teeth - PMC [pmc.ncbi.nlm.nih.gov]
- 2. files.core.ac.uk [files.core.ac.uk]
- 3. Clinical and radiographic assessment of root canal treatments performed by dental students [revodonto.bvsalud.org]
- 4. Clinical and Radiographic Evaluation of a Resin-Based Root Canal Sealer: 10-Year Recall Data - PMC [pmc.ncbi.nlm.nih.gov]
- 5. Clinical and radiographic evaluation of root-canal obturation with obtura II - PubMed [pubmed.ncbi.nlm.nih.gov]
- 6. Radiographic Assessment of the Quality of Root Canal Fillings Performed by Senior Dental Students - PMC [pmc.ncbi.nlm.nih.gov]
- 7. Radiographic study of the problems and failures of endodontic treatment - PMC [pmc.ncbi.nlm.nih.gov]
- 8. researchgate.net [researchgate.net]
- 9. suffolkrootcanal.co.uk [suffolkrootcanal.co.uk]
- 10. Radiographic evaluation of periapical healing after obturation of infected root canals: an in vivo study - PubMed [pubmed.ncbi.nlm.nih.gov]
- 11. mdpi.com [mdpi.com]
- 12. Radiographic characteristics in the periapical healing post endodontic treatment in patients of the Autonomous University of Yucatan, School of Dentistry [scielo.org.mx]
- 13. Clinical and Radiographic Outcomes of Root Canal Obturation with Hydraulic Condensation and Tricalcium Silicate Bioceramic Sealer: A 12-Month Observational Study on Periapical Healing - PMC [pmc.ncbi.nlm.nih.gov]
- 14. Evaluation of the radiopacity of different root canal sealers - PubMed [pubmed.ncbi.nlm.nih.gov]
- 15. actaodontologicalat.com [actaodontologicalat.com]
- To cite this document: BenchChem. [Application Notes and Protocols for Radiographic Evaluation of Sargentol Root Canal Fillings]. BenchChem, [2025]. [Online PDF]. Available at: [https://www.benchchem.com/product/b15596442#radiographic-evaluation-of-sargentol-root-canal-fillings]

Disclaimer & Data Validity:

The information provided in this document is for Research Use Only (RUO) and is strictly not intended for diagnostic or therapeutic procedures. While BenchChem strives to provide accurate protocols, we make no warranties, express or implied, regarding the fitness of this product for every specific experimental setup.

Technical Support: The protocols provided are for reference purposes. Unsure if this reagent suits your experiment? [[Contact our Ph.D. Support Team for a compatibility check](#)]

Need Industrial/Bulk Grade? [Request Custom Synthesis Quote](#)

BenchChem

Our mission is to be the trusted global source of essential and advanced chemicals, empowering scientists and researchers to drive progress in science and industry.

Contact

Address: 3281 E Guasti Rd
Ontario, CA 91761, United States
Phone: (601) 213-4426
Email: info@benchchem.com