

# Application Notes and Protocols for Histopathological Examination of Indospicine- Induced Liver Damage

**Author:** BenchChem Technical Support Team. **Date:** December 2025

## Compound of Interest

Compound Name: *Indospicine*

Cat. No.: *B103619*

[Get Quote](#)

For Researchers, Scientists, and Drug Development Professionals

## Introduction

**Indospicine** is a non-proteinogenic amino acid and a potent hepatotoxin found in various species of the Indigofera plant genus.[1][2][3] This toxin can accumulate in the tissues of grazing animals and cause liver damage in susceptible species, notably dogs, through consumption of contaminated meat.[2][3] The primary mechanism of **indospicine**'s toxicity is its action as an arginine analogue, leading to competitive inhibition of essential metabolic pathways.[1] Understanding the histopathological consequences of **indospicine** exposure is crucial for diagnostic purposes, mechanistic studies, and the development of potential therapeutic interventions.

These application notes provide a comprehensive overview of the histopathological techniques used to examine and quantify liver damage induced by **indospicine**. Detailed protocols for key staining methods are provided, along with guidelines for quantitative analysis and visualization of the underlying molecular pathways.

## Histopathological Features of Indospicine-Induced Liver Damage

The hallmark of **indospicine** hepatotoxicity is dose-dependent liver damage, with dogs being particularly sensitive. The histopathological presentation can range from acute to chronic, depending on the dose and duration of exposure.

#### Acute and Subacute Changes:

- **Periacinar (Centrilobular) Necrosis:** This is a characteristic feature, often accompanied by hemorrhage and collapse of the reticulin framework in the affected zones.[\[4\]](#)
- **Hepatocellular Swelling and Vacuolation:** Affected hepatocytes often appear swollen with cytoplasmic vacuolation.[\[4\]](#)
- **Cholestasis:** Bile plugs may be observed in canaliculi.[\[4\]](#)

#### Chronic Changes:

- **Fibrosis:** With prolonged exposure, periportal and bridging fibrosis can develop.
- **Nodular Cirrhosis:** In severe, chronic cases, the liver can progress to a state of nodular cirrhosis.

## Experimental Protocols

### Tissue Preparation

Proper tissue fixation and processing are paramount for accurate histopathological assessment.

#### Protocol 1: Formalin Fixation and Paraffin Embedding

- **Tissue Collection:** Immediately following euthanasia, excise the liver and collect tissue samples of approximately 1-2 cm in length and 0.5 cm in thickness.
- **Fixation:** Place the tissue samples in 10% neutral buffered formalin for 24-48 hours at room temperature. The volume of formalin should be at least 10 times the volume of the tissue.
- **Processing:**
  - Dehydrate the fixed tissue through a graded series of ethanol (e.g., 70%, 95%, 100%).

- Clear the tissue with xylene or a xylene substitute.
- Infiltrate and embed the tissue in paraffin wax.
- Sectioning: Cut 4-5  $\mu\text{m}$  thick sections using a microtome and mount them on glass slides.

## Staining Techniques

### Protocol 2: Hematoxylin and Eosin (H&E) Staining

H&E staining is the cornerstone of histopathological examination, providing essential information on the overall liver architecture, cellular morphology, and the presence of necrosis and inflammation.

- Reagents:
  - Mayer's Hematoxylin Solution
  - Eosin Y Solution
  - Acid Alcohol (1% HCl in 70% ethanol)
  - Scott's Tap Water Substitute (or running tap water)
- Procedure:
  - Deparaffinize sections in xylene (2 changes, 5 minutes each).
  - Rehydrate through graded alcohols (100%, 95%, 70%) to distilled water (2 minutes each).
  - Stain in Mayer's Hematoxylin for 5-10 minutes.
  - Wash in running tap water for 5 minutes.
  - Differentiate in 1% acid alcohol for a few seconds.
  - Wash in running tap water.
  - "Blue" the sections in Scott's Tap Water Substitute or running tap water for 1-2 minutes.

- Counterstain in Eosin Y solution for 1-3 minutes.
- Dehydrate through graded alcohols (95%, 100%).
- Clear in xylene.
- Mount with a permanent mounting medium.
- Expected Results:
  - Nuclei: Blue/Purple
  - Cytoplasm: Pink/Red
  - Areas of necrosis will show increased eosinophilia and loss of nuclear staining.

#### Protocol 3: Masson's Trichrome Staining for Fibrosis

This stain is used to differentiate collagen fibers from other tissue components, making it ideal for assessing the degree of fibrosis.[5]

- Reagents:
  - Bouin's Solution (optional, for mordanting)
  - Weigert's Iron Hematoxylin
  - Biebrich Scarlet-Acid Fuchsin Solution
  - Phosphomolybdic/Phosphotungstic Acid Solution
  - Aniline Blue Solution
  - 1% Acetic Acid Solution
- Procedure:
  - Deparaffinize and rehydrate sections to distilled water.

- (Optional) Mordant in Bouin's solution at 56°C for 1 hour for improved staining quality, then wash thoroughly in running water to remove the yellow color.
- Stain nuclei with Weigert's hematoxylin for 10 minutes, then wash.
- Stain in Biebrich Scarlet-Acid Fuchsin for 5 minutes.
- Rinse in distilled water.
- Differentiate in Phosphomolybdic/Phosphotungstic Acid solution for 5 minutes.
- Stain in Aniline Blue solution for 5 minutes.
- Differentiate in 1% acetic acid for 1 minute.
- Dehydrate quickly through 95% and absolute ethanol.
- Clear in xylene and mount.
- Expected Results:
  - Collagen: Blue
  - Nuclei: Black
  - Cytoplasm, muscle, erythrocytes: Red

#### Protocol 4: Picro-Sirius Red Staining for Collagen

Picro-Sirius Red is a highly specific stain for collagen and, when viewed under polarized light, can help differentiate between collagen types.[6] It is considered more accurate for the quantification of collagen than Masson's Trichrome.[6]

- Reagents:
  - Picro-Sirius Red Solution (0.1% Sirius Red in saturated picric acid)
- Procedure:

- Deparaffinize and rehydrate sections to distilled water.
- Stain in Picro-Sirius Red solution for 1 hour.
- Wash in two changes of acidified water (0.5% acetic acid in water).
- Dehydrate rapidly in absolute ethanol.
- Clear in xylene and mount.
- Expected Results:
  - Bright-field microscopy: Collagen appears red on a yellow background.
  - Polarized light microscopy: Type I collagen (thick fibers) appears yellow-orange, while Type III collagen (thin fibers) appears green.<sup>[6]</sup>

#### Protocol 5: Immunohistochemistry (IHC) for $\alpha$ -Smooth Muscle Actin ( $\alpha$ -SMA) and Cleaved Caspase-3

IHC allows for the detection of specific proteins to identify cellular processes like apoptosis and fibrogenesis.

- $\alpha$ -Smooth Muscle Actin ( $\alpha$ -SMA): A marker for activated hepatic stellate cells, which are the primary producers of collagen during liver fibrosis.<sup>[7][8][9]</sup>
- Cleaved Caspase-3: A key executioner caspase, its presence is a reliable indicator of apoptosis.<sup>[10][11][12]</sup>
- General Procedure:
  - Antigen Retrieval: Perform heat-induced epitope retrieval (HIER) using a citrate buffer (pH 6.0) or Tris-EDTA buffer (pH 9.0).
  - Blocking: Block endogenous peroxidase activity with 3% hydrogen peroxide and non-specific binding with a protein block (e.g., normal goat serum).

- Primary Antibody Incubation: Incubate with the primary antibody (anti- $\alpha$ -SMA or anti-cleaved caspase-3) at an optimized dilution overnight at 4°C.
- Secondary Antibody and Detection: Use an appropriate HRP-conjugated secondary antibody followed by a DAB substrate-chromogen system.
- Counterstaining: Lightly counterstain with hematoxylin.
- Dehydration and Mounting: Dehydrate, clear, and mount the sections.
- Expected Results:
  - $\alpha$ -SMA: Brown staining in activated stellate cells, particularly in areas of fibrosis.
  - Cleaved Caspase-3: Brown staining in the cytoplasm and/or nucleus of apoptotic cells.[\[10\]](#)

#### Protocol 6: TUNEL (Terminal deoxynucleotidyl transferase dUTP Nick End Labeling) Assay

The TUNEL assay is used to detect DNA fragmentation, a hallmark of late-stage apoptosis. However, it's important to note that it can also stain necrotic cells, so results should be interpreted in conjunction with morphology.[\[13\]](#)[\[14\]](#)[\[15\]](#)

- Procedure: Follow the manufacturer's instructions for the specific TUNEL assay kit being used. The general steps include:
  - Deparaffinization and rehydration of tissue sections.
  - Permeabilization with proteinase K.
  - Incubation with the TdT reaction mixture containing labeled dUTPs.
  - Detection of the incorporated label (e.g., with an anti-label antibody conjugated to a reporter enzyme or a fluorescent molecule).
  - Counterstaining and mounting.
- Expected Results: Labeled nuclei (typically brown or fluorescent, depending on the detection method) in apoptotic and some necrotic cells.

## Data Presentation and Quantitative Analysis

Summarizing histopathological data in a quantitative manner is essential for objective comparison between experimental groups.

Table 1: Histological Scoring Systems for **Indospicine**-Induced Liver Damage

Several established scoring systems can be adapted to quantify the necroinflammatory changes and fibrosis observed in **indospicine**-induced liver injury.[\[16\]](#)[\[17\]](#)[\[18\]](#)[\[19\]](#)

Scoring System	Components Assessed	Scoring Range (Typical)	Application for Indospicine Damage
Knodell Histology Activity Index (HAI)	Periportal/bridging necrosis, intralobular degeneration, portal inflammation, fibrosis.	0-22	Comprehensive assessment of necroinflammation and fibrosis.
Ishak Score	Necroinflammation and fibrosis (staged separately).	Grade: 0-18, Stage: 0-6	Provides a more detailed staging of fibrosis. <a href="#">[20]</a>
METAVIR Score	Activity (inflammation) and fibrosis (staged separately).	Activity: A0-A3, Fibrosis: F0-F4	Commonly used in clinical trials, good for assessing fibrosis progression.
Batts-Ludwig System	Grading of necroinflammation and staging of fibrosis.	Grade: 0-4, Stage: 0-4	A widely used and relatively simple system.

Table 2: Quantitative Analysis of Fibrosis using Image Analysis

Digital image analysis of stained slides provides an objective measure of fibrosis.



Staining Method	Parameter Measured	Description
Masson's Trichrome or Picro-Sirius Red	Collagen Proportional Area (CPA)	The percentage of the total tissue area that is stained blue (Trichrome) or red (Sirius Red).[20]

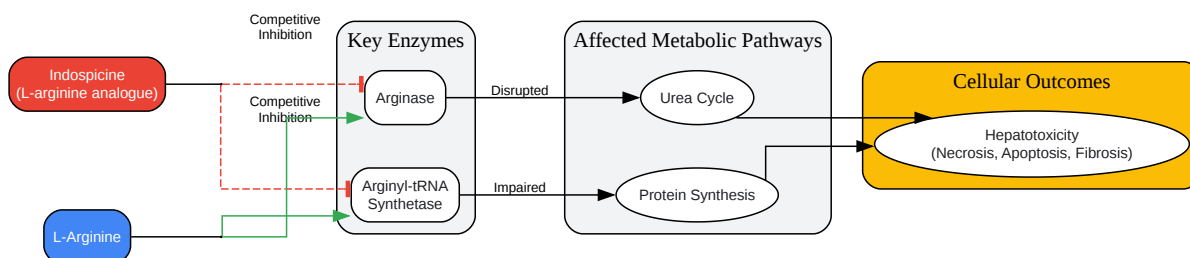
Table 3: Quantitative Analysis of Apoptosis and Cell Proliferation

Assay	Parameter Measured	Description
Cleaved Caspase-3 IHC	Apoptotic Index (%)	(Number of cleaved caspase-3 positive hepatocytes / Total number of hepatocytes) x 100.
TUNEL Assay	TUNEL-positive cells/area	The number of TUNEL-positive cells per high-power field or as a percentage of total cells.

## Signaling Pathways and Experimental Workflows

### Mechanism of **Indospicine** Hepatotoxicity

**Indospicine** acts as a competitive antagonist of the amino acid L-arginine. This interference disrupts several critical cellular processes, leading to hepatocyte injury and death.

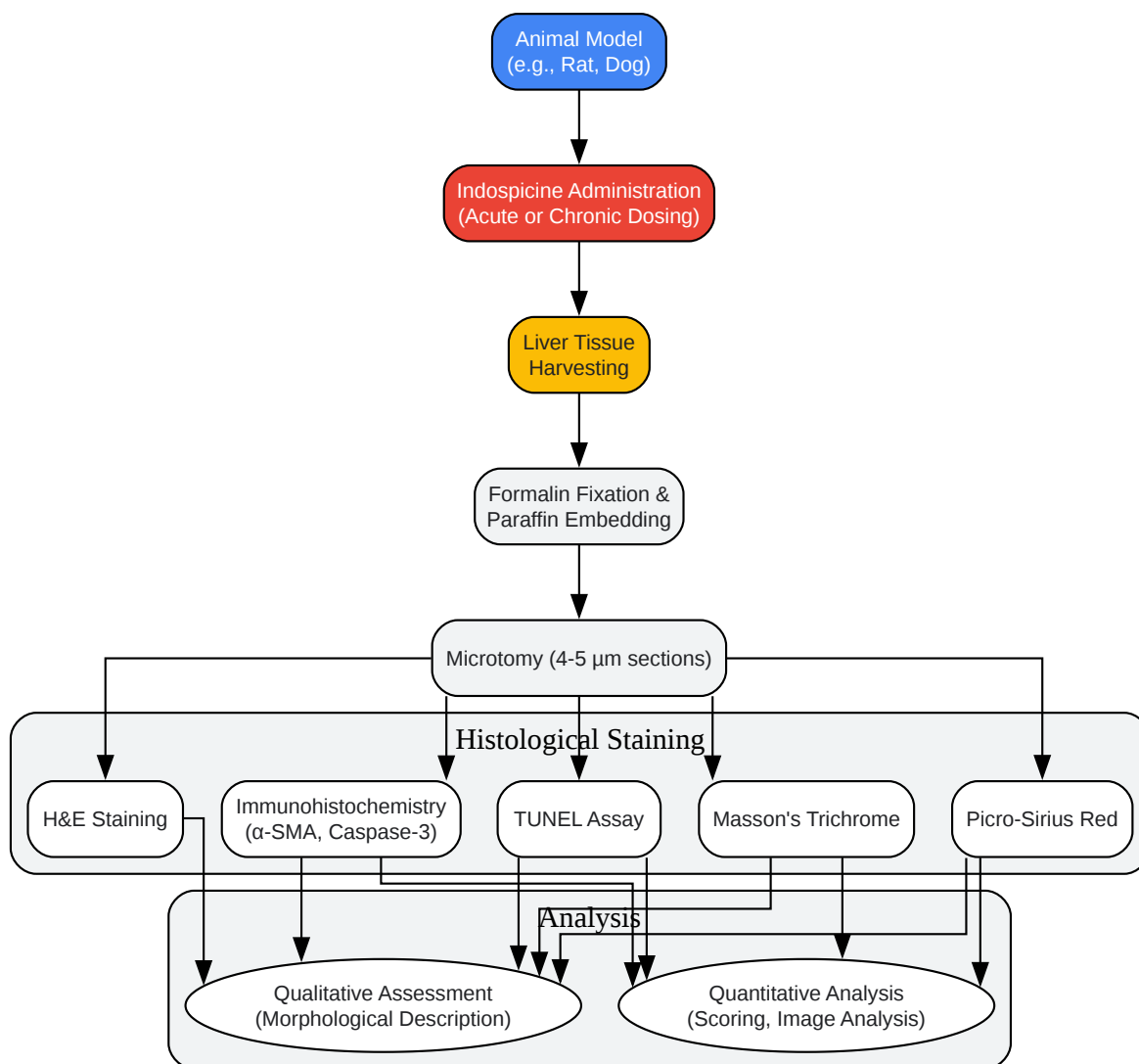


[Click to download full resolution via product page](#)

Caption: **Indospicine** competitively inhibits key enzymes in arginine metabolism.

### Experimental Workflow

The following diagram outlines a typical workflow for the histopathological assessment of **indospicine**-induced liver damage in an animal model.



[Click to download full resolution via product page](#)

### Need Custom Synthesis?

BenchChem offers custom synthesis for rare earth carbides and specific isotopic labeling.

Email: [info@benchchem.com](mailto:info@benchchem.com) or [Request Quote Online](#).

## References

- 1. The Occurrence and Toxicity of Indospicine to Grazing Animals - DPI eResearch Archive (eRA) [[era.dpi.qld.gov.au](http://era.dpi.qld.gov.au)]
- 2. [agriculture.vic.gov.au](http://agriculture.vic.gov.au) [[agriculture.vic.gov.au](http://agriculture.vic.gov.au)]
- 3. [gwic.nsw.gov.au](http://gwic.nsw.gov.au) [[gwic.nsw.gov.au](http://gwic.nsw.gov.au)]
- 4. Hepatotoxicity to dogs of horse meat contaminated with indospicine - PubMed [[pubmed.ncbi.nlm.nih.gov](http://pubmed.ncbi.nlm.nih.gov)]
- 5. Role of special stains in diagnostic liver pathology - PMC [[pmc.ncbi.nlm.nih.gov](http://pmc.ncbi.nlm.nih.gov)]
- 6. [fibrosis-inflammation.com](http://fibrosis-inflammation.com) [[fibrosis-inflammation.com](http://fibrosis-inflammation.com)]
- 7. The value of alpha-SMA in the evaluation of hepatic fibrosis severity in hepatitis B infection and cirrhosis development: a histopathological and immunohistochemical study - PubMed [[pubmed.ncbi.nlm.nih.gov](http://pubmed.ncbi.nlm.nih.gov)]
- 8. [Immunohistochemical analysis of alpha-SMA and GFAP expression in liver stellate cells] - PubMed [[pubmed.ncbi.nlm.nih.gov](http://pubmed.ncbi.nlm.nih.gov)]
- 9. Alpha-SMA expression in hepatic stellate cells and quantitative analysis of hepatic fibrosis in cirrhosis and in recurrent chronic hepatitis after liver transplantation - PubMed [[pubmed.ncbi.nlm.nih.gov](http://pubmed.ncbi.nlm.nih.gov)]
- 10. Immunohistochemical detection of activated caspases in apoptotic hepatocytes in rat liver - PubMed [[pubmed.ncbi.nlm.nih.gov](http://pubmed.ncbi.nlm.nih.gov)]
- 11. [researchgate.net](http://researchgate.net) [[researchgate.net](http://researchgate.net)]
- 12. Caspase 3 role and immunohistochemical expression in assessment of apoptosis as a feature of H1N1 vaccine-caused Drug-Induced Liver Injury (DILI) - PMC [[pmc.ncbi.nlm.nih.gov](http://pmc.ncbi.nlm.nih.gov)]
- 13. In situ detection of fragmented DNA (TUNEL assay) fails to discriminate among apoptosis, necrosis, and autolytic cell death: a cautionary note - PubMed [[pubmed.ncbi.nlm.nih.gov](http://pubmed.ncbi.nlm.nih.gov)]

- 14. False positive staining in the TUNEL assay to detect apoptosis in liver and intestine is caused by endogenous nucleases and inhibited by diethyl pyrocarbonate - PubMed [pubmed.ncbi.nlm.nih.gov]
- 15. researchgate.net [researchgate.net]
- 16. UpToDate 2018 [doctorabad.com]
- 17. A Comparative Evaluation of Scoring Systems for Assessing Necro-Inflammatory Activity and Fibrosis in Liver Biopsies of Patients with Chronic Viral Hepatitis - PMC [pmc.ncbi.nlm.nih.gov]
- 18. Comparison of four histological scoring systems for autoimmune hepatitis to improve diagnostic sensitivity - PMC [pmc.ncbi.nlm.nih.gov]
- 19. ageb.be [ageb.be]
- 20. mdpi.com [mdpi.com]
- To cite this document: BenchChem. [Application Notes and Protocols for Histopathological Examination of Indospicine-Induced Liver Damage]. BenchChem, [2025]. [Online PDF]. Available at: [https://www.benchchem.com/product/b103619#histopathological-techniques-for-examining-indospicine-induced-liver-damage]

---

#### Disclaimer & Data Validity:

The information provided in this document is for Research Use Only (RUO) and is strictly not intended for diagnostic or therapeutic procedures. While BenchChem strives to provide accurate protocols, we make no warranties, express or implied, regarding the fitness of this product for every specific experimental setup.

**Technical Support:** The protocols provided are for reference purposes. Unsure if this reagent suits your experiment? [[Contact our Ph.D. Support Team for a compatibility check](#)]

**Need Industrial/Bulk Grade?** [Request Custom Synthesis Quote](#)

# BenchChem

Our mission is to be the trusted global source of essential and advanced chemicals, empowering scientists and researchers to drive progress in science and industry.

## Contact

Address: 3281 E Guasti Rd

Ontario, CA 91761, United States

Phone: (601) 213-4426

Email: [info@benchchem.com](mailto:info@benchchem.com)