

Application Notes and Protocols for EHIDA Imaging in Congenital Biliary Abnormalities

Author: BenchChem Technical Support Team. **Date:** December 2025

Compound of Interest

Compound Name: *Ehida*

Cat. No.: *B1195364*

[Get Quote](#)

For Researchers, Scientists, and Drug Development Professionals

Introduction

Congenital biliary abnormalities encompass a range of disorders affecting the bile ducts, with biliary atresia (BA) being the most critical. Biliary atresia is a congenital disorder characterized by the absence or severe deficiency of the extrahepatic biliary tree, leading to cholestasis and rapidly progressing to cirrhosis if not treated.[1] Prompt and accurate diagnosis is crucial, as the success of surgical intervention, the Kasai portoenterostomy, is significantly higher when performed within the first 60-90 days of life.[2]

Hepatobiliary Iminodiacetic Acid (HIDA) scan, also known as cholescintigraphy or **EHIDA** (Excretory Hepatobiliary Iminodiacetic Acid) imaging, is a non-invasive functional imaging modality that plays a pivotal role in the diagnostic workup of these conditions.[2][3] It evaluates the function of hepatocytes and the patency of the biliary system by tracking the flow of a radioactive tracer from the liver through the bile ducts and into the small intestine.[4][5][6] This document provides detailed protocols and data for the application of **EHIDA** imaging in the investigation of congenital biliary abnormalities.

Principle of the Technique

EHIDA imaging is a nuclear medicine procedure that utilizes a radioactive tracer, typically Technetium-99m (Tc-99m) complexed with an iminodiacetic acid (IDA) derivative like Mebrofenin or Disofenin.[1][3]

The core principle involves several steps:

- **Intravenous Injection:** The radiotracer is injected into the patient's bloodstream.[4]
- **Hepatic Uptake:** The tracer is bound to albumin in the blood, transported to the liver, and taken up by hepatocytes, following a similar metabolic pathway to bilirubin.[3]
- **Biliary Excretion:** The liver then excretes the tracer into the bile.
- **Visualization:** The tracer's path is tracked using a gamma camera. In a healthy system, the tracer flows from the liver into the intrahepatic and extrahepatic bile ducts, fills the gallbladder, and then empties into the small intestine (duodenum).[4][5]

The presence or absence of the tracer in the small intestine at specific time points is the key diagnostic indicator for conditions like biliary atresia.[1][3]

Key Applications

The primary application of **EHIDA** imaging in neonates and infants is the differentiation of biliary atresia from other causes of neonatal cholestasis, such as neonatal hepatitis.[1][7]

- **Biliary Atresia (BA):** In BA, the extrahepatic bile ducts are obstructed or absent. An **EHIDA** scan will typically show good uptake of the tracer by the liver but a complete absence of excretion into the small bowel, even on delayed images taken up to 24 hours post-injection. [1][3]
- **Neonatal Hepatitis:** In this condition, severe hepatocellular dysfunction can impair bile secretion, but the biliary tree is patent. An **EHIDA** scan may show delayed excretion, but tracer activity will eventually be visible in the intestines.
- **Other Congenital Anomalies:** **EHIDA** scans can also help identify other rare anomalies such as choledochal cysts by demonstrating communication between the cystic structure and the biliary tree.[8][9]

Data Presentation: Diagnostic Accuracy of EHIDA Imaging

The diagnostic performance of **EHIDA** imaging for biliary atresia has been evaluated in numerous studies. While highly sensitive, its specificity can be affected by severe hepatocellular disease.

Performance Metric	Study 1 (2022) [2]	Study 2 (2021) [7]	Study 3 (Retrospective Cohort)[10]	Study 4 (Review)[11]
Sensitivity	91.2%	90.5%	~95.2% (20/21 cases)	98.7%
Specificity	80.6%	80%	Moderate (8 false positives)	70.4%
Positive Predictive Value (PPV)	88.1%	Not Reported	Not Reported	Not Reported
Negative Predictive Value (NPV)	85.3%	Not Reported	Not Reported	Not Reported
Overall Accuracy	Not Reported	83.6%	Not Reported	Not Reported

Data is synthesized from the cited retrospective studies. Performance can vary based on patient population and protocol variations.

Semi-Quantitative Parameters for Differentiating BA from Neonatal Hepatitis[7]

Parameter	Typical Finding in Biliary Atresia	Significance
Kidney-Liver Ratio (KLR)	Significantly Higher	Indicates poor hepatic excretion and alternative renal clearance of the tracer.
Intestinal-Liver Ratio (ILR)	Significantly Higher	Appears counterintuitive; may reflect background ROI counts in the absence of true intestinal excretion.
Background-Liver Ratio (BLR)	Significantly Higher	Reflects poor clearance of tracer from the blood pool due to impaired hepatic uptake/excretion.
Liver-Kidney Ratio (LKR)	Significantly Lower	Directly reflects reduced tracer concentration in the liver relative to the kidney.

Among these, the Kidney-Liver Ratio (KLR) had the largest area under the curve (AUC), suggesting it may be the most predictive semi-quantitative parameter.[\[7\]](#)

Experimental Protocols

Patient Preparation

- Fasting: Proper fasting is essential to promote gallbladder filling.
 - Infants: Fast for 2-4 hours before the scan. Clear liquids may be permissible if medically necessary.[\[12\]](#)
 - Children: Fast for 4-6 hours.[\[12\]](#)
 - Note: Patients with suspected biliary atresia do not need to fast for extended periods.[\[13\]](#)
- Pharmacologic Pretreatment (Phenobarbital): To enhance biliary excretion and increase the specificity of the test, especially in infants with high bilirubin levels.[\[1\]](#)

- Agent: Phenobarbital.
- Dosage: 5 mg/kg/day, administered orally in two divided doses.
- Duration: For a minimum of 3 to 5 days preceding the **EHIDA** scan.[\[12\]](#)
- Mechanism: Stimulates hepatic enzymes, increasing the secretion of the radiotracer into the biliary system.[\[1\]](#)

Radiopharmaceutical Administration

- Radiotracer: Tc-99m Mebrofenin is preferred over Disofenin in patients with hyperbilirubinemia due to its higher hepatic extraction efficiency.[\[1\]](#)[\[12\]](#)
- Dosage: Administered intravenously. The dose is calculated based on the patient's body weight, with a typical minimum dose for pediatric patients.
- Administration: An intravenous (IV) line is established for tracer injection.[\[13\]](#)

Image Acquisition Protocol

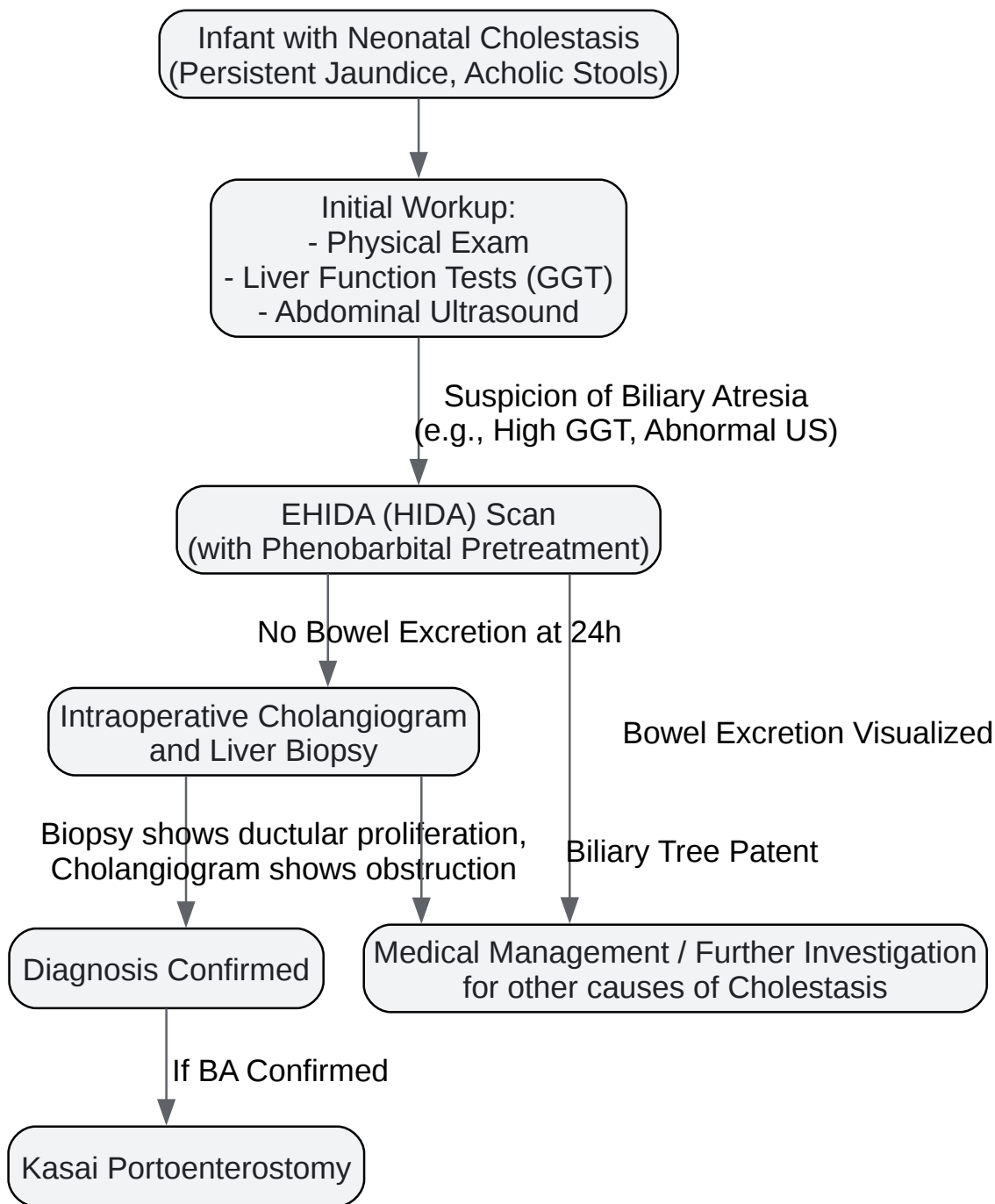
- Equipment: A large field-of-view gamma camera equipped with a low-energy, all-purpose collimator.
- Patient Positioning: The patient is placed in a supine position on the imaging table.[\[13\]](#) Immobilization may be necessary for infants to prevent motion artifacts.[\[13\]](#)
- Dynamic Imaging:
 - Begin image acquisition immediately upon injection of the radiotracer.
 - Acquire images continuously for 60 minutes.
 - This initial phase assesses hepatic perfusion, uptake, and early excretion.
- Static Imaging:
 - Acquire anterior views of the abdomen, including the liver, biliary tract, and small bowel.

- Additional views (e.g., right lateral, oblique) can be obtained to better separate the gallbladder and bile duct from the liver and duodenum.[\[12\]](#)
- Delayed Imaging:
 - If the radiotracer is not visualized in the small bowel by 60 minutes, delayed imaging is mandatory.
 - Acquire static images at 2 to 4 hours and, if necessary, up to 24 hours post-injection.[\[1\]](#)
[\[12\]](#) The 24-hour image is critical for the diagnosis of biliary atresia.[\[1\]](#)

Interpretation of Results

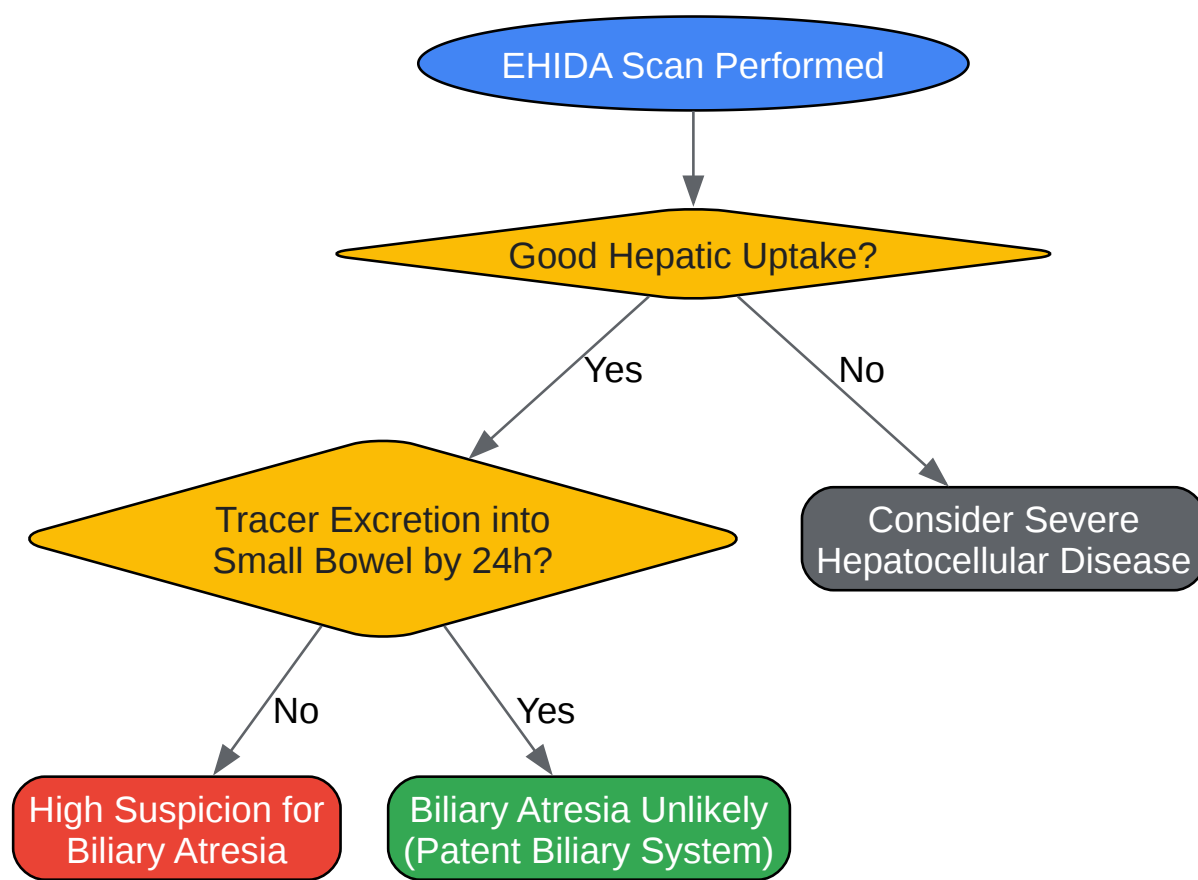
- Normal Study: Prompt hepatic uptake of the tracer with visualization of the gallbladder, common bile duct, and tracer activity in the small intestine within one hour.[\[4\]](#)
- Biliary Atresia: Good hepatic uptake and concentration of the tracer, but complete absence of tracer excretion into the bowel, even on 24-hour delayed images.[\[1\]](#)[\[3\]](#) The gallbladder is typically not visualized.
- Severe Neonatal Hepatitis or Hepatocellular Dysfunction: Poor hepatic uptake, slow blood clearance of the tracer, and significantly delayed (but eventual) excretion of small amounts of tracer into the bowel.[\[11\]](#)
- Partial Biliary Obstruction: Delayed biliary-to-bowel transit time.[\[3\]](#)[\[4\]](#)

Visualizations: Workflows and Logic Diagrams



[Click to download full resolution via product page](#)

Caption: Diagnostic workflow for suspected biliary atresia.



[Click to download full resolution via product page](#)

Caption: Interpretation logic for **EHIDA** scan results.

Conclusion and Limitations

EHIDA imaging is an indispensable, non-invasive tool for the functional assessment of the biliary system in infants with suspected congenital biliary abnormalities. Its high sensitivity for biliary atresia makes it excellent for screening and guiding decisions for more invasive diagnostic procedures.[2]

However, researchers and clinicians must be aware of its limitations. The specificity is moderate, and false-positive results (non-excretion of tracer in the absence of BA) can occur in patients with severe hepatocellular disease, leading to unnecessary surgical exploration.[2][11] Therefore, **EHIDA** scan results should always be interpreted in the context of clinical findings, laboratory tests (such as GGT levels), and abdominal ultrasound results.[10][14] The gold

standard for the definitive diagnosis of biliary atresia remains a liver biopsy combined with an intraoperative cholangiogram.[2]

Need Custom Synthesis?

BenchChem offers custom synthesis for rare earth carbides and specific isotopic labeling.

Email: info@benchchem.com or [Request Quote Online](#).

References

- 1. radiopaedia.org [radiopaedia.org]
- 2. Frontiers | The Value of Hepatic Scintigraphy in the Diagnosis of Biliary Atresia [frontiersin.org]
- 3. Hepatobiliary Scintigraphy - StatPearls - NCBI Bookshelf [ncbi.nlm.nih.gov]
- 4. HIDA scan - Mayo Clinic [mayoclinic.org]
- 5. HIDA Scan: Preparation, Results, Side Effects, and Cost [healthline.com]
- 6. my.clevelandclinic.org [my.clevelandclinic.org]
- 7. researchgate.net [researchgate.net]
- 8. digitalrepository.unm.edu [digitalrepository.unm.edu]
- 9. Congenital Hepatobiliary Anomalies | Radiology Key [radiologykey.com]
- 10. Hepatobiliary Iminodiacetic Acid (HIDA) Scan in the Evaluation of Biliary Atresia: A Retrospective Cohort Study - PMC [pmc.ncbi.nlm.nih.gov]
- 11. researchgate.net [researchgate.net]
- 12. snmmi.org [snmmi.org]
- 13. texaschildrens.org [texaschildrens.org]
- 14. researchgate.net [researchgate.net]
- To cite this document: BenchChem. [Application Notes and Protocols for EHIDA Imaging in Congenital Biliary Abnormalities]. BenchChem, [2025]. [Online PDF]. Available at: [https://www.benchchem.com/product/b1195364#ehida-imaging-for-congenital-biliary-abnormalities]

Disclaimer & Data Validity:

The information provided in this document is for Research Use Only (RUO) and is strictly not intended for diagnostic or therapeutic procedures. While BenchChem strives to provide accurate protocols, we make no warranties, express or implied, regarding the fitness of this product for every specific experimental setup.

Technical Support: The protocols provided are for reference purposes. Unsure if this reagent suits your experiment? [[Contact our Ph.D. Support Team for a compatibility check](#)]

Need Industrial/Bulk Grade? [Request Custom Synthesis Quote](#)

BenchChem

Our mission is to be the trusted global source of essential and advanced chemicals, empowering scientists and researchers to drive progress in science and industry.

Contact

Address: 3281 E Guasti Rd
Ontario, CA 91761, United States
Phone: (601) 213-4426
Email: info@benchchem.com