

Application Notes and Protocols for Disofenin Imaging in Acute Cholecystitis Animal Models

Author: BenchChem Technical Support Team. **Date:** December 2025

Compound of Interest

Compound Name: *Disofenin*

Cat. No.: *B014549*

[Get Quote](#)

For Researchers, Scientists, and Drug Development Professionals

Introduction

Acute cholecystitis, an inflammation of the gallbladder, is a common clinical condition often necessitating medical intervention. Animal models are indispensable for studying the pathophysiology of this disease and for the preclinical evaluation of novel diagnostic and therapeutic agents. Hepatobiliary iminodiacetic acid (HIDA) scanning, utilizing technetium-99m (99mTc) labeled agents like **Disofenin**, is a cornerstone in the clinical diagnosis of acute cholecystitis. This imaging modality provides functional information about the patency of the cystic duct, a critical factor in the onset of the disease. These application notes provide detailed protocols for inducing acute cholecystitis in animal models and for performing subsequent **Disofenin** imaging to assess the disease state.

Key Applications

- **Evaluating Gallbladder Function:** Non-invasively assess the filling and emptying of the gallbladder.
- **Confirming Cystic Duct Obstruction:** A key diagnostic marker for acute cholecystitis.
- **Monitoring Disease Progression:** Track the severity of inflammation and the effects of therapeutic interventions over time.

- Preclinical Drug Efficacy Studies: Evaluate the impact of novel therapeutics on restoring biliary function and reducing inflammation.

Experimental Protocols

I. Induction of Acute Cholecystitis in Animal Models

The most common and reproducible method for inducing acute cholecystitis in animal models is the surgical ligation of the cystic duct or the common bile duct.[\[1\]](#)[\[2\]](#)[\[3\]](#)

A. Canine Model of Acute Cholecystitis

This model has been successfully used in imaging studies with HIDA agents.[\[1\]](#)[\[4\]](#)[\[5\]](#)

Materials:

- Adult mongrel dogs
- General anesthesia (e.g., isoflurane)
- Surgical instruments for laparotomy
- Suture material

Protocol:

- Anesthetize the animal and prepare the abdominal area for sterile surgery.
- Perform a midline laparotomy to expose the abdominal organs.
- Gently retract the liver to visualize the gallbladder and the cystic duct.
- Carefully dissect the cystic duct, avoiding damage to the common bile duct and surrounding vasculature.
- Ligate the cystic duct using non-absorbable suture material.
- For control animals, perform a sham surgery involving laparotomy and mobilization of the gallbladder without duct ligation.[\[1\]](#)[\[4\]](#)[\[5\]](#)

- Close the abdominal incision in layers.
- Provide appropriate post-operative care, including analgesics and monitoring for any signs of distress.
- Acute cholecystitis will develop over the following 1-5 days.[\[1\]](#)[\[4\]](#)[\[5\]](#)

B. Rodent (Rabbit/Mouse) Model of Acute Cholecystitis

Rodent models offer the advantages of lower cost and easier handling.

Materials:

- Rabbits or mice
- General anesthesia
- Surgical instruments
- Suture material

Protocol:

- Anesthetize the animal and perform sterile preparation of the surgical site.
- Make a midline abdominal incision to expose the liver and gallbladder.
- In rabbits, the common bile duct can be ligated to induce cholecystitis.[\[2\]](#) In mice, the cystic duct can be ligated.
- Carefully isolate the target duct and ligate it with a suture.
- Close the abdomen in layers.
- Provide post-operative care as required.

II. ^{99m}Tc-Disofenin Imaging Protocol

This protocol is adapted from studies using similar HIDA agents in canine models and general guidelines for small animal scintigraphy.[\[1\]](#)[\[4\]](#)[\[5\]](#)[\[6\]](#)

Materials:

- 99mTc-**Disofenin** (or 99mTc-Mebrofenin)
- Gamma camera/SPECT system equipped with a low-energy, high-resolution collimator
- Anesthesia (e.g., isoflurane) for animal immobilization during imaging
- Saline for injection

Protocol:

- Animal Preparation: Fast the animal for at least 4-6 hours prior to imaging to ensure gallbladder relaxation and promote filling.
- Radiotracer Administration:
 - Anesthetize the animal.
 - Administer 99mTc-**Disofenin** intravenously. A typical dose for a canine model is approximately 2 mCi (74 MBq).[\[1\]](#)[\[4\]](#)[\[5\]](#) For smaller animals like rabbits or mice, the dose should be adjusted based on weight.
- Image Acquisition:
 - Position the animal supine under the gamma camera immediately after injection.
 - Acquire dynamic images for the first 60 minutes. This allows for the visualization of hepatic uptake, biliary excretion, and gallbladder filling.
 - Obtain static images at later time points (e.g., 90 minutes, 2 hours, 4 hours) if the gallbladder is not visualized within the first hour.
- Image Analysis (Qualitative):

- Normal: Prompt hepatic uptake of the radiotracer with visualization of the gallbladder and common bile duct within 60 minutes, followed by passage of the tracer into the small intestine.
- Acute Cholecystitis: Good hepatic uptake and excretion into the common bile duct and small intestine, but persistent non-visualization of the gallbladder even on delayed imaging (up to 4 hours). This indicates cystic duct obstruction.^[7]

Data Presentation: Quantitative Analysis

Quantitative analysis of **Disofenin** scans can provide objective measures of hepatobiliary function. This involves generating time-activity curves (TACs) from regions of interest (ROIs) drawn around the liver and gallbladder.^[8]

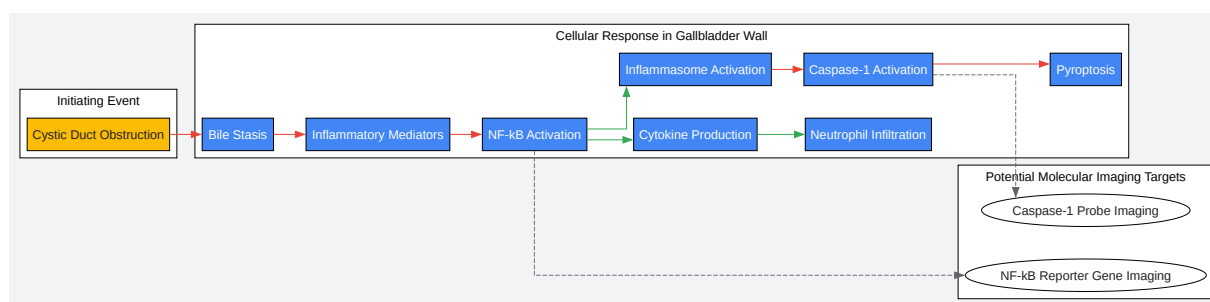
Parameter	Description	Expected Finding in Acute Cholecystitis Model
Time to Peak Hepatic Activity (Tmax)	Time taken for the liver to reach its maximum radioactivity.	Generally normal, unless there is concurrent liver dysfunction.
Hepatic Excretion Half-Time (T1/2)	Time taken for the radioactivity in the liver to decrease by half from its peak.	May be normal or slightly delayed.
Gallbladder Filling (%)	Percentage of tracer that enters the gallbladder relative to the total hepatic uptake.	Significantly reduced or absent.
Gallbladder Ejection Fraction (GBEF)	Percentage of tracer expelled from the gallbladder after stimulation with cholecystokinin (CCK).	Not applicable if the gallbladder is not visualized. If there is delayed filling, GBEF is expected to be low. ^{[9][10]}

Software such as the HEPATIQ® software or custom-developed programs can be used for quantitative analysis of hepatobiliary scintigraphy.^{[11][12]}

Visualization of Signaling Pathways and Experimental Workflow

Signaling Pathways in Acute Cholecystitis

Acute cholecystitis is characterized by a robust inflammatory response. Key signaling pathways involved include the activation of NF- κ B and the inflammasome, leading to the production of pro-inflammatory cytokines and eventual cell death. Molecular imaging techniques can be employed to visualize these pathways in vivo.



[Click to download full resolution via product page](#)

Caption: Inflammatory signaling cascade in acute cholecystitis.

Note on Molecular Imaging:

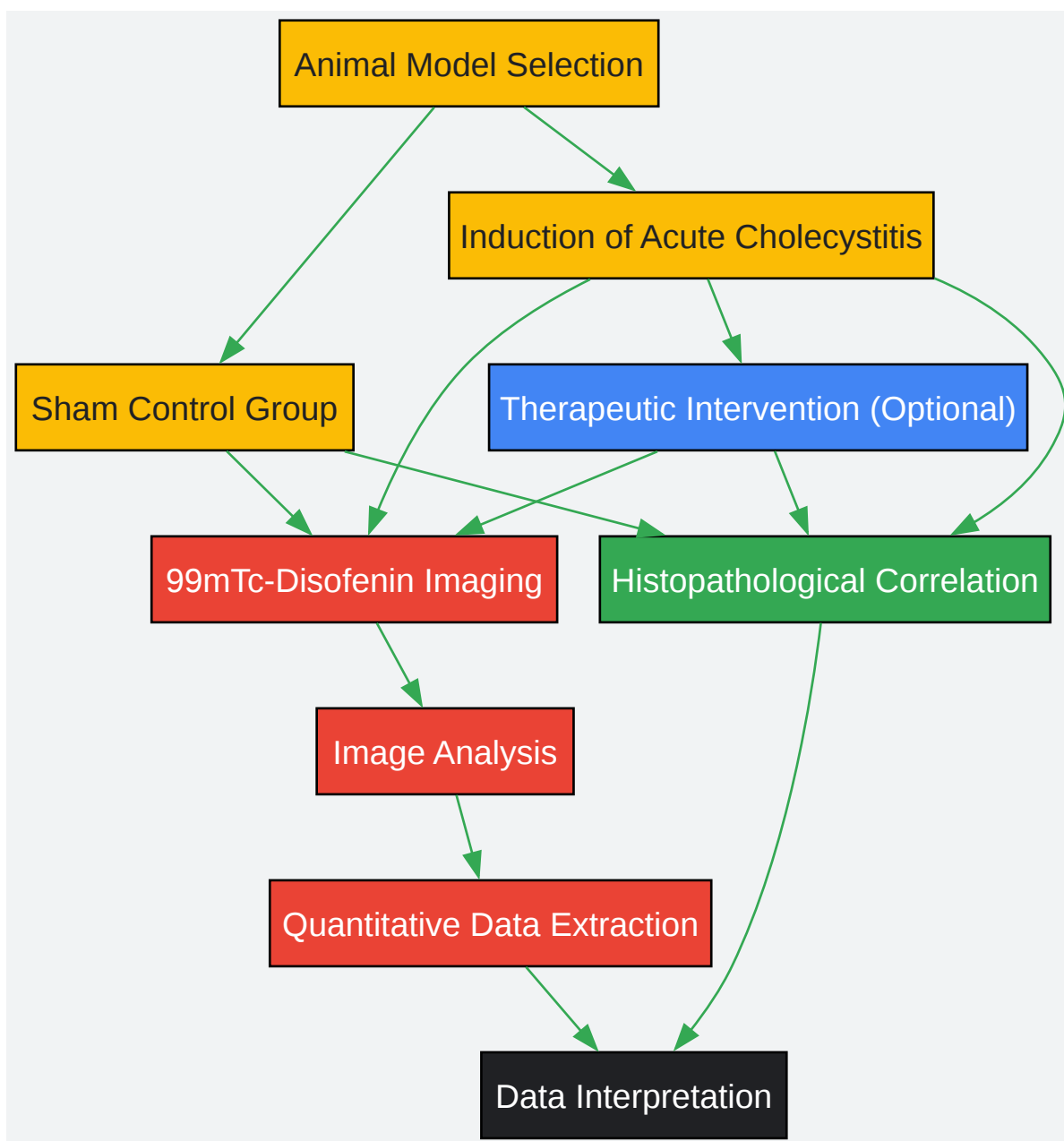
- **NF- κ B Activation:** Transgenic animals expressing a luciferase reporter gene under the control of NF- κ B can be used. Upon NF- κ B activation, luciferase is produced, which can be

imaged in vivo using a sensitive camera after the injection of luciferin.[2][13][14]

- Caspase-1 Activation: Near-infrared fluorescent (NIRF) probes that are specifically cleaved by active caspase-1 can be administered. Cleavage of the probe results in a fluorescent signal that can be detected at the site of inflammation.[1][15][16][17]

Experimental Workflow

The following diagram outlines the typical workflow for using **Disofenin** imaging in an acute cholecystitis animal model study.



[Click to download full resolution via product page](#)

Caption: Workflow for **Disofenin** imaging in animal models.

Histopathological Correlation

At the end of the imaging studies, it is crucial to euthanize the animals and collect the gallbladder and liver for histopathological analysis. This allows for the correlation of imaging findings with the actual degree of inflammation, necrosis, and edema in the tissues, thereby validating the imaging data.[18][19]

Conclusion

Disofenin imaging is a powerful and clinically relevant tool for the preclinical evaluation of acute cholecystitis in animal models. The protocols and guidelines presented here provide a framework for researchers to effectively utilize this technology to gain deeper insights into the pathophysiology of the disease and to accelerate the development of new therapeutic strategies. The integration of quantitative analysis and molecular imaging of specific inflammatory pathways can further enhance the utility of these models in drug discovery and development.

Need Custom Synthesis?

BenchChem offers custom synthesis for rare earth carbides and specific isotopic labeling.

Email: info@benchchem.com or [Request Quote Online](#).

References

- 1. A novel method for imaging apoptosis using a caspase-1 near-infrared fluorescent probe - PubMed [pubmed.ncbi.nlm.nih.gov]
- 2. db.cngb.org [db.cngb.org]
- 3. publications.ersnet.org [publications.ersnet.org]
- 4. Acute cholecystitis in an animal model: findings on color Doppler sonography - PubMed [pubmed.ncbi.nlm.nih.gov]
- 5. ajronline.org [ajronline.org]

- 6. Transsplenic portal scintigraphy using 99mTc-mebrofenin in normal dogs - PubMed [pubmed.ncbi.nlm.nih.gov]
- 7. Cholecystitis | Radiology Key [radiologykey.com]
- 8. researchgate.net [researchgate.net]
- 9. Cholecystokinin Test - StatPearls - NCBI Bookshelf [ncbi.nlm.nih.gov]
- 10. radiopaedia.org [radiopaedia.org]
- 11. discovery.researcher.life [discovery.researcher.life]
- 12. Hepatiq, Inc. [hepatiq.com]
- 13. In vivo imaging of NF-kappa B activity - PubMed [pubmed.ncbi.nlm.nih.gov]
- 14. In Vivo Bioluminescence Imaging of Nuclear Factor kappaB Activation: A Valuable Model for Studying Inflammatory and Oxidative Stress in Live Mice - PMC [pmc.ncbi.nlm.nih.gov]
- 15. pubs.acs.org [pubs.acs.org]
- 16. Non-invasive in vivo imaging of caspase-1 activation enables rapid and spatiotemporal detection of acute and chronic inflammatory disorders - PubMed [pubmed.ncbi.nlm.nih.gov]
- 17. researchgate.net [researchgate.net]
- 18. Clinical And Imaging Study of Acute Cholecystitis and Correlation with Biochemical and Pathological Markers | JCCP (Journal of Contemporary Clinical Practice) [jccpractice.com]
- 19. A Retrospective Study Comparing Radiological to Histopathological Diagnosis After Laparoscopic Cholecystectomy for Suspected Cholecystitis - PMC [pmc.ncbi.nlm.nih.gov]
- To cite this document: BenchChem. [Application Notes and Protocols for Disofenin Imaging in Acute Cholecystitis Animal Models]. BenchChem, [2025]. [Online PDF]. Available at: [https://www.benchchem.com/product/b014549#using-disofenin-imaging-for-acute-cholecystitis-animal-models]

Disclaimer & Data Validity:

The information provided in this document is for Research Use Only (RUO) and is strictly not intended for diagnostic or therapeutic procedures. While BenchChem strives to provide accurate protocols, we make no warranties, express or implied, regarding the fitness of this product for every specific experimental setup.

Technical Support: The protocols provided are for reference purposes. Unsure if this reagent suits your experiment? [[Contact our Ph.D. Support Team for a compatibility check](#)]

Need Industrial/Bulk Grade? [Request Custom Synthesis Quote](#)

BenchChem

Our mission is to be the trusted global source of essential and advanced chemicals, empowering scientists and researchers to drive progress in science and industry.

Contact

Address: 3281 E Guasti Rd
Ontario, CA 91761, United States
Phone: (601) 213-4426
Email: info@benchchem.com