

Application Notes and Protocols for ^{99m}Tc-Sestamibi SPECT in Parathyroid Adenoma Localization

Author: BenchChem Technical Support Team. **Date:** December 2025

Compound of Interest

Compound Name: ^{99m}Tc-Sestamibi

Cat. No.: B1243785

[Get Quote](#)

Audience: Researchers, scientists, and drug development professionals.

Introduction: Primary hyperparathyroidism is most commonly caused by a single parathyroid adenoma.[1] Preoperative localization of these adenomas is crucial for guiding minimally invasive parathyroidectomy.[1][2] Technetium-99m Sestamibi (**^{99m}Tc-Sestamibi**) Single Photon Emission Computed Tomography (SPECT) is a widely utilized nuclear medicine imaging technique for this purpose.[3] This document provides detailed protocols for **^{99m}Tc-Sestamibi** SPECT, including dual-phase and subtraction techniques, often integrated with Computed Tomography (SPECT/CT) for improved anatomical localization.[2][4] **^{99m}Tc-Sestamibi** is taken up by both thyroid and parathyroid tissue but exhibits differential washout, with prolonged retention in hyperfunctioning parathyroid tissue compared to the thyroid.[5][6]

I. Core Principles and Methodologies

Two primary protocols are employed for parathyroid scintigraphy using **^{99m}Tc-Sestamibi**: the dual-phase technique and the subtraction technique.[5][7] The addition of SPECT/CT is now a common practice to enhance diagnostic accuracy by providing anatomical correlation to functional findings.[2][4]

- **Dual-Phase Technique:** This method relies on the differential washout kinetics of **^{99m}Tc-Sestamibi** from the thyroid and parathyroid glands.[8][9] Early images show uptake in both

tissues, while delayed images demonstrate clearance from the thyroid and retention in the parathyroid adenoma.[5][6]

- Subtraction Technique: This approach involves the administration of a second radiopharmaceutical that is specifically taken up by the thyroid gland, such as 99mTc-pertechnetate or Iodine-123 (123I).[5][9] The image of the thyroid gland is then digitally subtracted from the **99mTc-Sestamibi** image, isolating the activity in the parathyroid adenoma.[5][7]

II. Experimental Protocols

A. Patient Preparation

Generally, no special preparation such as fasting is required for the patient.[7][10] However, it is important to:

- Explain the procedure to the patient, emphasizing the need to remain still during image acquisition, especially for subtraction and SPECT/CT imaging.[5][7]
- Document any history of thyroid disease, previous neck surgery, and recent administration of iodine-containing contrast media or thyroid medications, as these can interfere with the scan, particularly if a subtraction technique with a thyroid-specific agent is planned.[5][7][11]
- Ensure the patient is well-hydrated.[11]

B. Radiopharmaceuticals and Dosimetry

The following table summarizes the commonly used radiopharmaceuticals and their typical adult dosages.

| Radiopharmaceutical | Purpose | Typical Adult Dose (Intravenous) | Notes |
|---------------------|-----------------------------------|------------------------------------|---|
| 99mTc-Sestamibi | Parathyroid and Thyroid Imaging | 740–1,110 MBq (20–30 mCi)[5][7] | Washes out more slowly from adenomatous parathyroid tissue than from thyroid tissue.[5] |
| 99mTc-Pertechnetate | Thyroid Imaging (for subtraction) | 74–370 MBq (2–10 mCi)[5] | Trapped by functioning thyroid tissue.[5] |
| Iodine-123 (123I) | Thyroid Imaging (for subtraction) | 7.5–22 MBq (200–600 µCi) (Oral)[5] | Trapped and organified by functioning thyroid tissue.[5] |

C. Protocol 1: Dual-Phase 99mTc-Sestamibi SPECT/CT

This is a widely used protocol that leverages the differential washout of **99mTc-Sestamibi**.

Methodology:

- Radiopharmaceutical Administration: Administer 740–1,110 MBq (20–30 mCi) of **99mTc-Sestamibi** intravenously.[5][7]
- Early Phase Imaging (15-20 minutes post-injection):
 - Acquire planar images of the neck and mediastinum.[3]
 - An initial SPECT or SPECT/CT of the neck and upper chest may also be performed at this stage.[2][10]
- Delayed Phase Imaging (2-3 hours post-injection):
 - Repeat the planar imaging of the neck and mediastinum.[3][10]

- Acquire a SPECT/CT of the neck and upper chest. Late SPECT/CT has been shown to be superior to early SPECT/CT for adenoma identification.[\[2\]](#)[\[12\]](#)

Image Acquisition Parameters (Example):

| Parameter | Planar Imaging | SPECT/CT |
|---------------------------|--|---|
| Collimator | Low-Energy, High-Resolution (LEHR) Parallel-Hole or Pinhole [5] | LEHR Parallel-Hole [13] |
| Energy Window | 140 keV with a 12-15% window [13] | 140 keV with a 12% window [13] |
| Matrix | 128 x 128 or 256 x 256 [5] [9] | 128 x 128 |
| Acquisition Time (Planar) | 5-10 minutes per view [14] | N/A |
| SPECT Acquisition | 360° rotation, 64 views, 20-30 seconds per view [13] | 180° (for dual-head cameras), 32 stops, 30 seconds per projection [13] |
| CT Parameters | Low-dose CT for localization and attenuation correction (e.g., 110-130 kVp, 30-110 mAs) [13] | Low-dose CT for localization and attenuation correction (e.g., 110 kVp, 110 mAs) [13] |

D. Protocol 2: ^{99m}Tc-Sestamibi / ¹²³I Subtraction SPECT/CT

This protocol offers high sensitivity, particularly in complex cases.[\[9\]](#)

Methodology:

- ¹²³I Administration: Administer 7.5–22 MBq (200–600 µCi) of ¹²³I orally.[\[5\]](#)
- Thyroid Imaging (4 hours post-¹²³I): Acquire a high-count (e.g., 10-minute) planar image of the thyroid.[\[7\]](#)

- **99mTc-Sestamibi Administration:** Administer 740–1,110 MBq (20–30 mCi) of **99mTc-Sestamibi** intravenously.[\[5\]](#)[\[7\]](#)
- Sestamibi and Subtraction Imaging (10-20 minutes post-Sestamibi):
 - Perform simultaneous acquisition of **99mTc-Sestamibi** and 123I data using dual energy windows.[\[8\]](#)[\[13\]](#)
 - Acquire planar and SPECT/CT images.
- Image Processing:
 - Normalize the 123I and **99mTc-Sestamibi** images.[\[7\]](#)
 - Subtract the normalized 123I image from the **99mTc-Sestamibi** image to isolate parathyroid activity.[\[7\]](#)

Image Acquisition Parameters (Example for Simultaneous Acquisition):

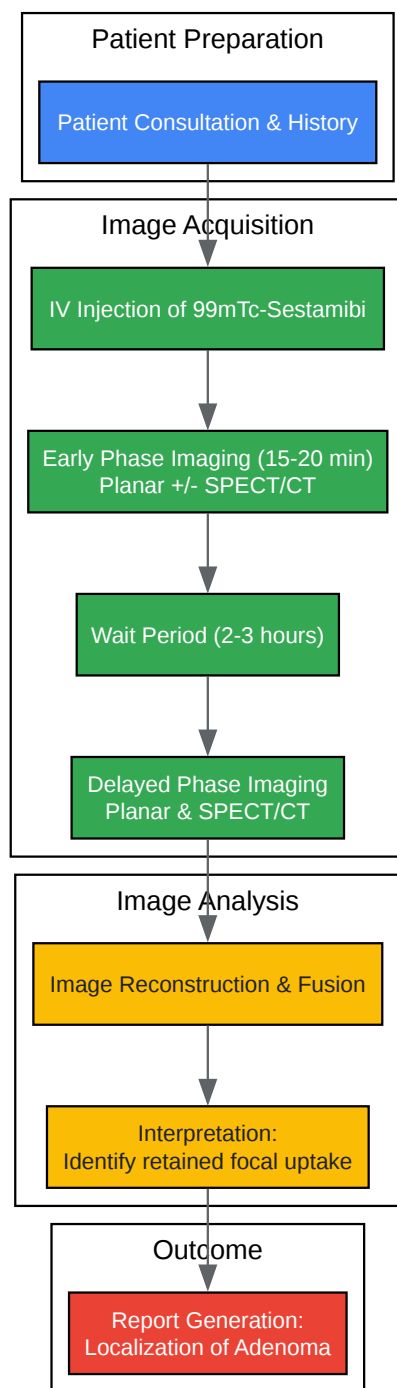
| Parameter | Value |
|---------------------|--|
| 99mTc Energy Window | 140 keV with a 12% window [13] |
| 123I Energy Window | 159 keV with an 8% symmetric window [13] |
| Collimator | Low-Energy, High-Resolution (LEHR) |
| SPECT Acquisition | 360° rotation, 64 views, 20-30 seconds per view |

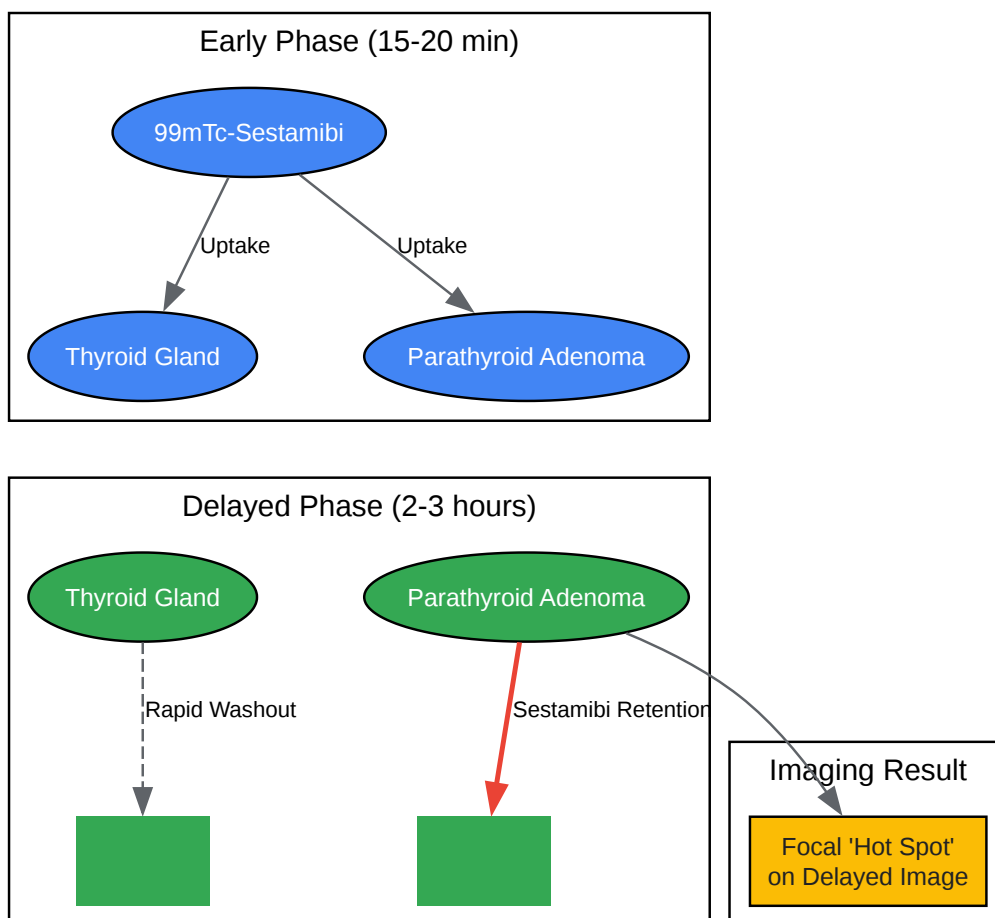
III. Image Interpretation

- Dual-Phase: A parathyroid adenoma is typically identified as a focus of increased tracer uptake that persists or becomes more prominent on the delayed images relative to the surrounding thyroid tissue.[\[5\]](#)
- Subtraction: An adenoma appears as a focus of residual activity on the subtraction images after the thyroid image has been removed.[\[5\]](#)

- SPECT/CT: The fused images provide precise anatomical localization of the hyperfunctioning parathyroid tissue, which is critical for surgical planning.[\[2\]](#)[\[4\]](#)

IV. Visualizations

Workflow for Dual-Phase ^{99m}Tc -Sestamibi SPECT/CT[Click to download full resolution via product page](#)Caption: Workflow of the Dual-Phase ^{99m}Tc -Sestamibi SPECT/CT Protocol.

Principle of ^{99m}Tc -Sestamibi Localization in Parathyroid Adenoma

[Click to download full resolution via product page](#)

Caption: Differential washout principle for parathyroid adenoma localization.

Need Custom Synthesis?

BenchChem offers custom synthesis for rare earth carbides and specific isotopic labeling.

Email: info@benchchem.com or [Request Quote Online](#).

References

- 1. Solitary Parathyroid Adenoma Localization in Technetium Tc99m Sestamibi SPECT and Multiphase Multidetector 4D CT - PMC [pmc.ncbi.nlm.nih.gov]
- 2. Optimal timing of SPECT/CT to demonstrate parathyroid adenomas in 99mTc-sestamibi scintigraphy | Hunter | Nuclear Medicine Review [journals.viamedica.pl]
- 3. radiopaedia.org [radiopaedia.org]
- 4. Parathyroid adenoma localization with 99mTc-sestamibi SPECT/CT: a meta-analysis - PubMed [pubmed.ncbi.nlm.nih.gov]
- 5. tech.snmjournals.org [tech.snmjournals.org]
- 6. pubs.rsna.org [pubs.rsna.org]
- 7. snmmi.org [snmmi.org]
- 8. 99mTc-Sestamibi/123I Subtraction SPECT/CT in Parathyroid Scintigraphy: Is Additional Pinhole Imaging Useful? - PMC [pmc.ncbi.nlm.nih.gov]
- 9. Comparison of Five Parathyroid Scintigraphic Protocols - PMC [pmc.ncbi.nlm.nih.gov]
- 10. nghs.com [nghs.com]
- 11. materprivate.ie [materprivate.ie]
- 12. journals.viamedica.pl [journals.viamedica.pl]
- 13. tech.snmjournals.org [tech.snmjournals.org]
- 14. jnm.snmjournals.org [jnm.snmjournals.org]
- To cite this document: BenchChem. [Application Notes and Protocols for 99mTc-Sestamibi SPECT in Parathyroid Adenoma Localization]. BenchChem, [2025]. [Online PDF]. Available at: [https://www.benchchem.com/product/b1243785#99mtc-sestamibi-spect-protocol-for-parathyroid-adenoma-localization]

Disclaimer & Data Validity:

The information provided in this document is for Research Use Only (RUO) and is strictly not intended for diagnostic or therapeutic procedures. While BenchChem strives to provide accurate protocols, we make no warranties, express or implied, regarding the fitness of this product for every specific experimental setup.

Technical Support: The protocols provided are for reference purposes. Unsure if this reagent suits your experiment? [[Contact our Ph.D. Support Team for a compatibility check](#)]

Need Industrial/Bulk Grade? [Request Custom Synthesis Quote](#)

BenchChem

Our mission is to be the trusted global source of essential and advanced chemicals, empowering scientists and researchers to drive progress in science and industry.

Contact

Address: 3281 E Guasti Rd

Ontario, CA 91761, United States

Phone: (601) 213-4426

Email: info@benchchem.com