

Application Notes and Protocols: Thallium-201 Scintigraphy for Diagnosing Pulmonary Kaposi Sarcoma

Author: BenchChem Technical Support Team. **Date:** December 2025

Compound of Interest

Compound Name: *Thallium-201*

Cat. No.: *B079191*

[Get Quote](#)

For Researchers, Scientists, and Drug Development Professionals

Introduction

Thallium-201 (Tl-201) scintigraphy is a nuclear medicine imaging technique that can be a valuable tool in the differential diagnosis of pulmonary lesions, particularly in immunocompromised patients such as those with Acquired Immunodeficiency Syndrome (AIDS). In this population, differentiating pulmonary Kaposi sarcoma (KS) from opportunistic infections and lymphoma is a common diagnostic challenge. **Thallium-201**, a potassium analog, is actively taken up by viable tumor cells, making it a useful agent for tumor imaging. This document provides detailed application notes and protocols for the use of Tl-201 scintigraphy in the diagnosis of pulmonary Kaposi sarcoma.

Kaposi sarcoma is a vascular tumor and its pulmonary involvement can be difficult to diagnose based on clinical and radiographic findings alone. Tl-201 scintigraphy, particularly when used in sequence with Gallium-67 (Ga-67) scintigraphy, offers a non-invasive method to increase diagnostic specificity. The characteristic finding for pulmonary KS is increased Tl-201 uptake in the absence of significant Ga-67 uptake.^{[1][2]}

Principle of the Method

Thallium-201 is a metallic radionuclide that functions as a potassium (K⁺) analog. Its cellular uptake is primarily mediated by the Na⁺/K⁺-ATPase pump, which is highly active in viable tumor cells.[3] This active transport mechanism allows for the accumulation of Tl-201 in neoplastic tissues like Kaposi sarcoma. In contrast, inflammatory and infectious lesions typically show less avid or transient Tl-201 uptake.

Gallium-67 citrate, on the other hand, accumulates in areas of inflammation and infection, as well as in some tumors like lymphoma. Therefore, the sequential use of Tl-201 and Ga-67 can effectively differentiate these pathologies.

Quantitative Data Presentation

The diagnostic accuracy of **Thallium-201** scintigraphy, particularly when combined with Gallium-67 scanning, has been evaluated in several studies. The hallmark of pulmonary Kaposi sarcoma is a "Thallium-positive, Gallium-negative" pattern.

Study Parameter	Value (%)	Population	Reference
Thallium-Positive, Gallium-Negative Pattern for KS			
Sensitivity (without concurrent infection)	89	AIDS patients with pulmonary KS	[4][5]
Sensitivity (with concurrent infection)	37	AIDS patients with pulmonary KS and opportunistic infections	[4]
Specificity	96	AIDS patients with opportunistic infections without KS	[4]
Positive Predictive Value (PPV)	92	AIDS patients with various pulmonary lesions	[4][5]
Negative Predictive Value (NPV)	75	AIDS patients with various pulmonary lesions	[4][5]
Accuracy	81	AIDS patients with various pulmonary lesions	[4][5]
Thallium-201 Alone for Tumor Detection			
Sensitivity	94.12	Patients with various tumors	[6]
Specificity	87.5	Patients with various tumors	[6]
Positive Predictive Value (PPV)	94.12	Patients with various tumors	[6]

Negative Predictive Value (NPV)	87.50	Patients with various tumors	[6]
Accuracy	92	Patients with various tumors	[6]

Experimental Protocols

Protocol 1: Thallium-201 SPECT/CT for Pulmonary Imaging

This protocol outlines the procedure for performing a Single Photon Emission Computed Tomography (SPECT) scan combined with a low-dose Computed Tomography (CT) for anatomical localization.

1. Patient Preparation:

- No specific dietary restrictions are typically required. Patients can eat and drink as usual.
- Ensure the patient is well-hydrated.
- Obtain informed consent.
- Instruct the patient to remove any metal objects from the chest area to prevent artifacts.[\[7\]](#)

2. Radiopharmaceutical:

- Agent: **Thallium-201** (Tl-201) Chloride
- Dose: 3.0 mCi (111 MBq), administered intravenously.
- Administration: Inject into a peripheral vein followed by a saline flush.

3. Imaging Acquisition:

- Timing: Imaging is typically performed at 15-30 minutes (early) and 3-4 hours (delayed) post-injection.[\[1\]](#) The delayed imaging is crucial for differentiating tumor from inflammatory lesions, as tumors tend to retain Tl-201 while inflammatory lesions often show washout.[\[2\]](#)

- **Imaging System:** A dual-head SPECT/CT gamma camera equipped with a low-energy, high-resolution (LEHR) collimator.
- **Patient Positioning:** The patient should be positioned supine on the imaging table with their arms raised above their head to minimize attenuation artifacts in the chest region.
- **SPECT Acquisition Parameters:**
 - **Energy Window:** 20% window centered on the 70 keV and 167 keV photopeaks of Tl-201.
 - **Matrix Size:** 128 x 128
 - **Zoom:** 1.2-1.5 (to optimize resolution on the chest area)
 - **Rotation:** 360° (180° for each detector)
 - **Projections:** 64 projections at 20-30 seconds per projection.
- **Low-Dose CT Acquisition:**
 - A low-dose CT scan is acquired immediately after the SPECT acquisition for attenuation correction and anatomical localization.
 - Typical parameters: 120 kVp, 30-50 mAs.

4. Image Processing and Interpretation:

- SPECT images are reconstructed using an iterative reconstruction algorithm (e.g., OSEM) with CT-based attenuation correction.
- The reconstructed SPECT and CT images are fused to localize areas of abnormal Tl-201 uptake within the pulmonary parenchyma, pleura, or mediastinum.
- Increased focal or diffuse Tl-201 uptake on delayed images is considered positive for malignancy, including Kaposi sarcoma.

Protocol 2: Sequential Thallium-201 and Gallium-67 Scintigraphy

This protocol is the gold standard for differentiating pulmonary Kaposi sarcoma from opportunistic infections and lymphoma in AIDS patients.

1. Thallium-201 Scan:

- Follow the **Thallium-201** SPECT/CT protocol as described above, including early and delayed imaging.

2. Gallium-67 Scan:

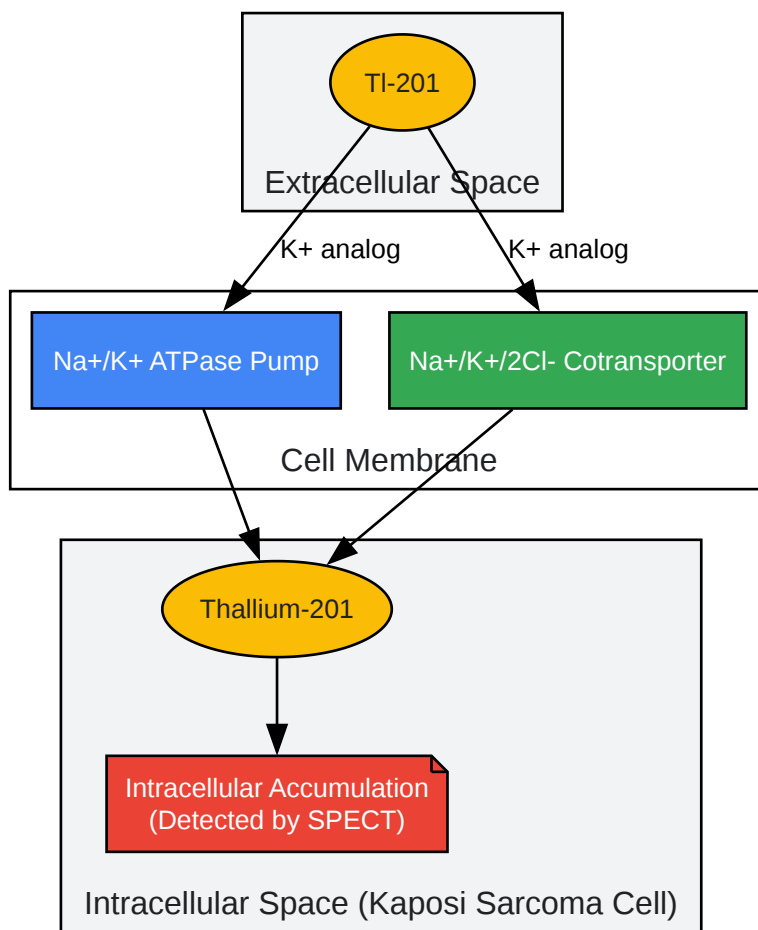
- Timing: The Ga-67 scan is typically performed 24-48 hours after the Tl-201 scan to allow for the decay of Tl-201 and to minimize interference.
- Radiopharmaceutical:
 - Agent: Gallium-67 (Ga-67) Citrate
 - Dose: 5-10 mCi (185-370 MBq), administered intravenously.
- Imaging Acquisition:
 - Timing: Imaging is performed at 48-72 hours post-injection.[\[1\]](#)
 - Imaging System: A gamma camera equipped with a medium-energy collimator.
 - Acquisition: Planar whole-body images and/or SPECT/CT of the chest are acquired.
 - Energy Windows: Multiple energy windows are used for the various Ga-67 photopeaks (93, 184, 300, and 394 keV).

3. Interpretation of Sequential Scans:

- Kaposi Sarcoma: Positive Tl-201 uptake with negative or minimal Ga-67 uptake.[\[1\]](#)[\[2\]](#)
- Lymphoma: Positive uptake on both Tl-201 and Ga-67 scans.[\[8\]](#)

- Infection/Inflammation: Typically negative or faint Tl-201 uptake with positive Ga-67 uptake. [8]

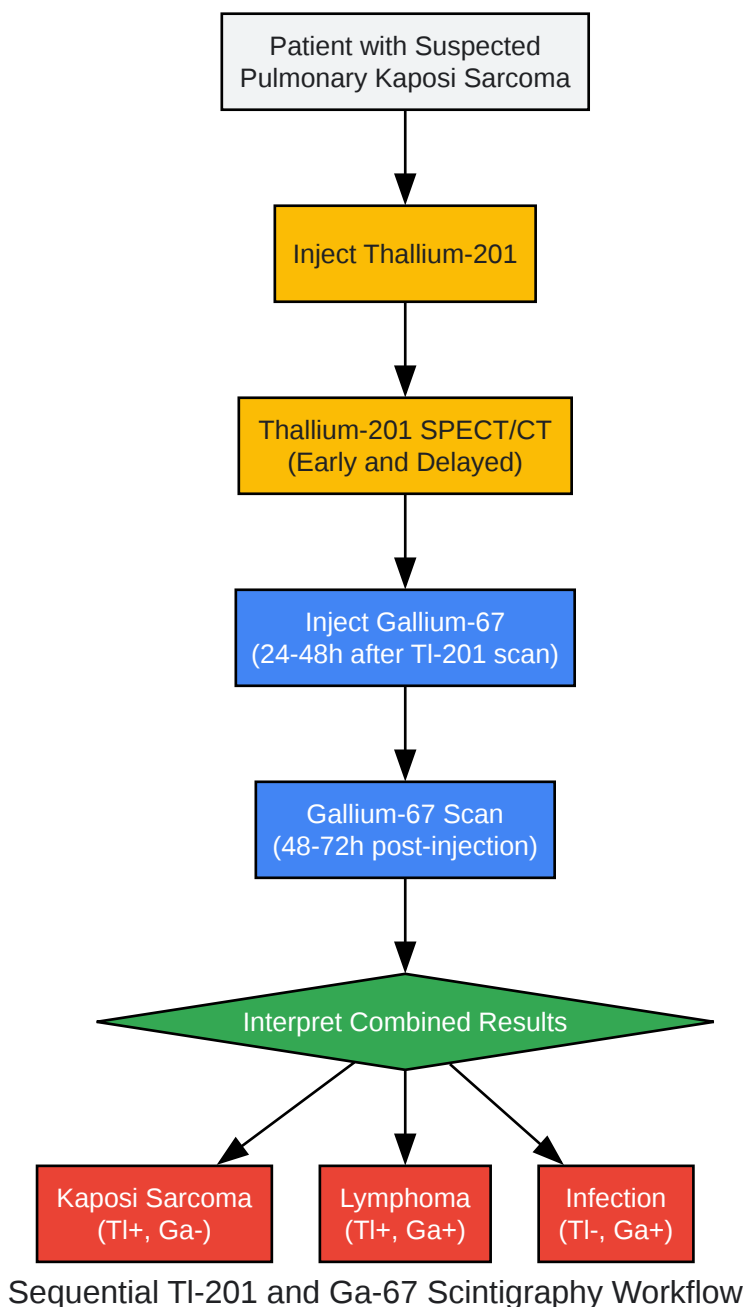
Mandatory Visualizations



Thallium-201 Cellular Uptake Mechanism

[Click to download full resolution via product page](#)

Caption: **Thallium-201** uptake is mediated by active transport into tumor cells.



[Click to download full resolution via product page](#)

Caption: Workflow for differential diagnosis using sequential scintigraphy.

Limitations and Considerations

- **Concurrent Infections:** The sensitivity of the Thallium-positive, Gallium-negative pattern for Kaposi sarcoma is significantly reduced in the presence of concurrent opportunistic infections.[4]

- Resolution: **Thallium-201** has a relatively low photon energy, which can result in lower resolution images compared to other radionuclides like Technetium-99m.
- Radiation Dose: **Thallium-201** has a longer half-life than some other commonly used isotopes, which can result in a higher radiation dose to the patient.[9]
- False Positives: Inflammatory processes can sometimes show **Thallium-201** uptake, although this is typically less intense and washes out on delayed imaging.
- Availability: The use of **Thallium-201** has declined in favor of PET/CT with FDG in many centers for oncologic imaging. However, it remains a valuable tool in specific clinical scenarios like the one described.

Conclusion

Thallium-201 scintigraphy, especially when performed sequentially with Gallium-67 scintigraphy, is a clinically useful, non-invasive imaging modality for the diagnosis of pulmonary Kaposi sarcoma in immunocompromised patients. The distinct "Thallium-positive, Gallium-negative" imaging pattern provides high specificity for Kaposi sarcoma, aiding in the differentiation from other common pulmonary pathologies in this patient population. Adherence to standardized protocols is essential for obtaining high-quality, interpretable images.

Need Custom Synthesis?

BenchChem offers custom synthesis for rare earth carbides and specific isotopic labeling.

Email: info@benchchem.com or [Request Quote Online](#).

References

1. Roentgen Ray Reader: Sequential Thallium and Gallium Scanning in AIDS Patients with Pulmonary Lesions [roentgenrayreader.blogspot.com]
2. Pulmonary Kaposi Sarcoma without Mucocutaneous Involvement: The Role of Sequential Thallium and Gallium Scintigraphy - Journal of Clinical Imaging Science [clinicalimagingscience.org]
3. Mechanism of ²⁰¹thallium-chloride uptake in tumor cells and its relationship to potassium channels - PubMed [pubmed.ncbi.nlm.nih.gov]

- 4. Evaluation of sequential thallium and gallium scans of the chest in AIDS patients - PubMed [pubmed.ncbi.nlm.nih.gov]
- 5. researchgate.net [researchgate.net]
- 6. To study the efficacy of thallium-201 as tumor seeking agent and to study its role in therapeutic response - PMC [pmc.ncbi.nlm.nih.gov]
- 7. Adenosine SPECT Thallium Imaging - StatPearls - NCBI Bookshelf [ncbi.nlm.nih.gov]
- 8. Pulmonary Kaposi sarcoma in patients with AIDS: scintigraphic diagnosis with sequential thallium and gallium scanning - PubMed [pubmed.ncbi.nlm.nih.gov]
- 9. Thallium-201 - StatPearls - NCBI Bookshelf [ncbi.nlm.nih.gov]
- To cite this document: BenchChem. [Application Notes and Protocols: Thallium-201 Scintigraphy for Diagnosing Pulmonary Kaposi Sarcoma]. BenchChem, [2025]. [Online PDF]. Available at: [https://www.benchchem.com/product/b079191#thallium-201-scintigraphy-for-diagnosing-pulmonary-kaposi-sarcoma]

Disclaimer & Data Validity:

The information provided in this document is for Research Use Only (RUO) and is strictly not intended for diagnostic or therapeutic procedures. While BenchChem strives to provide accurate protocols, we make no warranties, express or implied, regarding the fitness of this product for every specific experimental setup.

Technical Support: The protocols provided are for reference purposes. Unsure if this reagent suits your experiment? [[Contact our Ph.D. Support Team for a compatibility check](#)]

Need Industrial/Bulk Grade? [Request Custom Synthesis Quote](#)

BenchChem

Our mission is to be the trusted global source of essential and advanced chemicals, empowering scientists and researchers to drive progress in science and industry.

Contact

Address: 3281 E Guasti Rd
Ontario, CA 91761, United States
Phone: (601) 213-4426
Email: info@benchchem.com