

# Application Notes and Protocols: Pharmacologic Augmentation of Disofenin Scans with Morphine

**Author:** BenchChem Technical Support Team. **Date:** December 2025

## Compound of Interest

Compound Name: *Disofenin*

Cat. No.: *B014549*

[Get Quote](#)

For Researchers, Scientists, and Drug Development Professionals

## Introduction

Hepatobiliary scintigraphy, specifically using Technetium-99m (Tc-99m) **Disofenin**, is a cornerstone in the diagnosis of acute cholecystitis. The core principle of this imaging technique lies in the intravenous administration of a radiotracer that is taken up by hepatocytes and subsequently excreted into the biliary system. Visualization of the radiotracer in the common bile duct, gallbladder, and small intestine indicates a patent biliary system. However, non-visualization of the gallbladder with excretion into the small intestine can be indicative of cystic duct obstruction, a hallmark of acute cholecystitis, but can also be seen in other conditions.

To enhance the specificity of this diagnostic test and to shorten the imaging time, pharmacologic augmentation with morphine is employed.<sup>[1][2]</sup> Morphine administration helps to differentiate between true cystic duct obstruction and functional states that can mimic obstruction.<sup>[1]</sup> This document provides detailed application notes and protocols for the use of morphine in conjunction with **Disofenin** scans.

## Principle of Morphine Augmentation

Morphine is an opioid agonist that, among its many effects, causes contraction of the sphincter of Oddi.<sup>[1][3][4]</sup> This sphincter is a muscular valve that controls the flow of bile and pancreatic juice into the duodenum. By constricting the sphincter of Oddi, morphine increases pressure within the common bile duct.<sup>[1][3]</sup> This elevated pressure facilitates the flow of the radiotracer-

laden bile into the gallbladder, provided the cystic duct is patent.[1][3] Therefore, if the gallbladder visualizes after morphine administration, it rules out acute cholecystitis. Conversely, persistent non-visualization of the gallbladder after morphine is highly suggestive of a cystic duct obstruction and, consequently, acute cholecystitis.[5][6]

## Data Presentation: Diagnostic Accuracy

The use of morphine augmentation significantly improves the diagnostic accuracy of **Disofenin** scans for acute cholecystitis. The following table summarizes quantitative data from various studies.

Study Cohort	Sensitivity	Specificity	Positive Predictive Value (PPV)	Negative Predictive Value (NPV)	Accuracy
Morphine-Augmented Group[7]	93%	95%	81%	98%	95%
Conventional (Delayed Imaging)[7]	93%	83%	45%	99%	84%
Morphine-Augmented Group[5]	94.6%	99.1%	97.2%	98.3%	Not Reported
Morphine-Augmented Group[8]	96%	100%	Not Reported	Not Reported	98%
Conventional (Delayed Imaging)[8]	96%	83%	Not Reported	Not Reported	88%
Morphine-Augmented Group[9]	100%	85%	Not Reported	Not Reported	Not Reported
Morphine-Augmented Group[10]	100%	17%	70%	100%	72%

Note: The study by Chen et al. (2014) reported a high false-positive rate, which is important to consider in the interpretation of results.[10]

## Experimental Protocols

### Patient Preparation

- Fasting: The patient must be fasting for a minimum of 4 to 6 hours prior to the administration of Tc-99m **Disofenin**.[\[2\]](#)[\[6\]](#) This ensures a baseline state of gallbladder filling.
- Prolonged Fasting: If the patient has been fasting for more than 24 hours, premedication with sincalide (a cholecystokinin analog) may be considered to empty the gallbladder of viscous bile that could impair filling.[\[3\]](#) If sincalide is administered, a waiting period of at least 20 minutes should be observed before injecting the radiotracer.[\[3\]](#)
- Opioid Use: A thorough patient history should be taken to document any recent use of opioids, as these medications can interfere with the test results by causing premature contraction of the sphincter of Oddi.[\[6\]](#)[\[11\]](#) If the patient is on opioids, consultation with the referring clinician is necessary.[\[11\]](#)
- Allergies: Confirm that the patient has no known allergy to morphine.[\[11\]](#)
- Informed Consent: Obtain informed consent from the patient after explaining the procedure, including the administration of a radioactive tracer and morphine.

## Imaging Protocol

- Radiopharmaceutical Administration:
  - Administer approximately 185 MBq (5 mCi) of Tc-99m **Disofenin** intravenously.[\[2\]](#)[\[5\]](#) The dose may be adjusted based on the patient's total bilirubin level.[\[3\]](#)
- Initial Imaging:
  - Begin dynamic imaging immediately after injection using a large-field-of-view gamma camera fitted with a low-energy, parallel-hole collimator.[\[2\]](#)
  - Acquire anterior view dynamic images for the first 30-60 minutes.[\[2\]](#)
  - Follow with static anterior images at regular intervals until 60 minutes post-injection.[\[2\]](#)
- Morphine Augmentation (if required):
  - Indication: If the gallbladder is not visualized by 40-60 minutes, but there is visualization of the common bile duct and radiotracer activity in the small bowel, morphine augmentation

is indicated.[5][6]

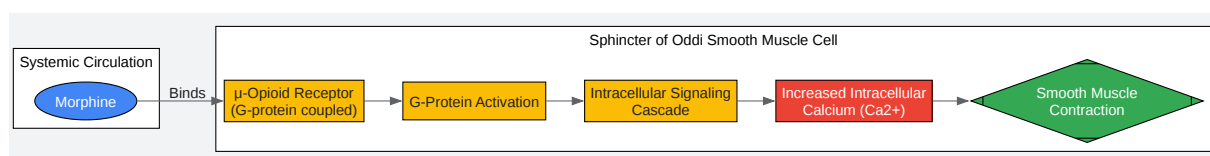
- Dosage: Administer morphine sulfate intravenously at a dose of 0.04 mg/kg.[5][6][11] A common practice is a slow push over 2-3 minutes.[2][11]
- Booster Dose: In cases of rapid biliary-to-bowel transit, a booster dose of 74–111 MBq (2–3 mCi) of Tc-99m **Disofenin** may be administered just before the morphine injection to ensure sufficient radiotracer activity in the liver.[2]
- Post-Morphine Imaging:
  - Continue imaging for an additional 30 minutes after morphine administration.[5][6]

## Image Interpretation

- Normal Study: Visualization of the gallbladder within 60 minutes of radiotracer injection.
- Acute Cholecystitis: Non-visualization of the gallbladder up to 30 minutes after morphine administration.[5][6]
- Chronic Cholecystitis or Other Biliary Pathology: Delayed visualization of the gallbladder (i.e., visualization only after morphine administration).[6]

## Visualizations

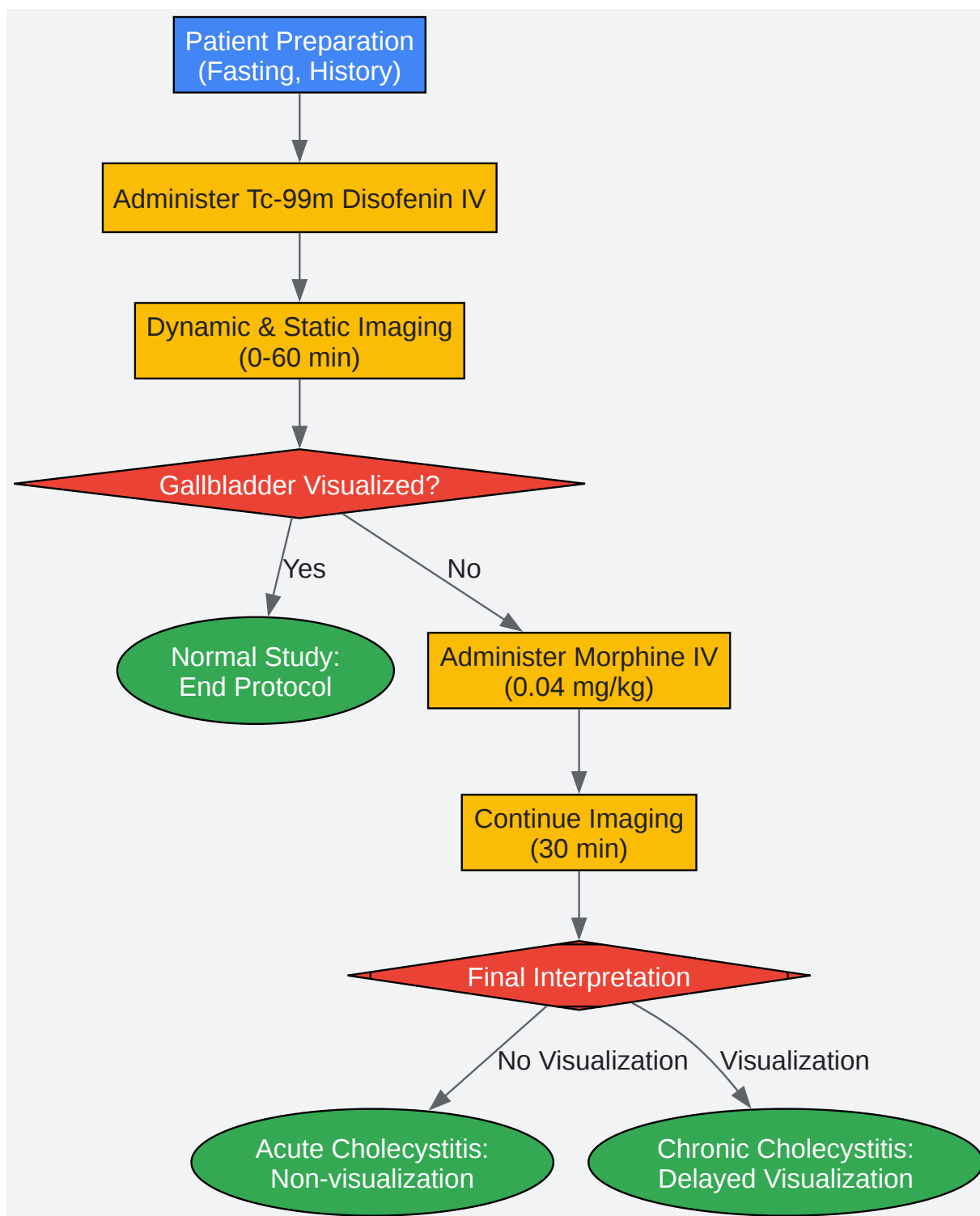
### Signaling Pathway of Morphine on the Sphincter of Oddi



[Click to download full resolution via product page](#)

Caption: Morphine's mechanism of action on the sphincter of Oddi.

## Experimental Workflow for Morphine-Augmented Disofenin Scan



[Click to download full resolution via product page](#)

Caption: Workflow of a morphine-augmented **Disofenin** scan.

#### Need Custom Synthesis?

BenchChem offers custom synthesis for rare earth carbides and specific isotopic labeling.

Email: [info@benchchem.com](mailto:info@benchchem.com) or [Request Quote Online](#).

## References

- 1. [tech.snmjournals.org](http://tech.snmjournals.org) [[tech.snmjournals.org](http://tech.snmjournals.org)]
- 2. Revisiting morphine-augmented hepatobiliary imaging for diagnosing acute cholecystitis: the potential pitfall of high false positive rate - PMC [[pmc.ncbi.nlm.nih.gov](http://pmc.ncbi.nlm.nih.gov)]
- 3. [jnm.snmjournals.org](http://jnm.snmjournals.org) [[jnm.snmjournals.org](http://jnm.snmjournals.org)]
- 4. Effects of narcotic analgesic drugs on human Oddi's sphincter motility - PMC [[pmc.ncbi.nlm.nih.gov](http://pmc.ncbi.nlm.nih.gov)]
- 5. Morphine-augmented cholescintigraphy: its efficacy in detecting acute cholecystitis - PubMed [[pubmed.ncbi.nlm.nih.gov](http://pubmed.ncbi.nlm.nih.gov)]
- 6. Cholecystokinin and morphine pharmacological intervention during 99mTc-HIDA cholescintigraphy: a rational approach - PubMed [[pubmed.ncbi.nlm.nih.gov](http://pubmed.ncbi.nlm.nih.gov)]
- 7. Morphine-Modified Hepatobiliary Scanning Protocol for the Diagnosis of Acute Cholecystitis - PubMed [[pubmed.ncbi.nlm.nih.gov](http://pubmed.ncbi.nlm.nih.gov)]
- 8. [pubs.rsna.org](http://pubs.rsna.org) [[pubs.rsna.org](http://pubs.rsna.org)]
- 9. Clinical efficacy of intravenous morphine administration in hepatobiliary imaging for acute cholecystitis - PubMed [[pubmed.ncbi.nlm.nih.gov](http://pubmed.ncbi.nlm.nih.gov)]
- 10. Revisiting morphine-augmented hepatobiliary imaging for diagnosing acute cholecystitis: the potential pitfall of high false positive rate | [springermedizin.de](http://springermedizin.de) [[springermedizin.de](http://springermedizin.de)]
- 11. [radiology.wisc.edu](http://radiology.wisc.edu) [[radiology.wisc.edu](http://radiology.wisc.edu)]
- To cite this document: BenchChem. [Application Notes and Protocols: Pharmacologic Augmentation of Disofenin Scans with Morphine]. BenchChem, [2025]. [Online PDF]. Available at: [<https://www.benchchem.com/product/b014549#pharmacologic-augmentation-of-disofenin-scans-with-morphine>]

**Disclaimer & Data Validity:**

The information provided in this document is for Research Use Only (RUO) and is strictly not intended for diagnostic or therapeutic procedures. While BenchChem strives to provide accurate protocols, we make no warranties, express or implied, regarding the fitness of this product for every specific experimental setup.

**Technical Support:** The protocols provided are for reference purposes. Unsure if this reagent suits your experiment? [[Contact our Ph.D. Support Team for a compatibility check](#)]

**Need Industrial/Bulk Grade?** [Request Custom Synthesis Quote](#)

## BenchChem

Our mission is to be the trusted global source of essential and advanced chemicals, empowering scientists and researchers to drive progress in science and industry.

### Contact

Address: 3281 E Guasti Rd  
Ontario, CA 91761, United States  
Phone: (601) 213-4426  
Email: [info@benchchem.com](mailto:info@benchchem.com)