

# Application Notes and Protocols: Histopathological Examination of Intestinal Lesions After Toltrazuril Treatment

**Author:** BenchChem Technical Support Team. **Date:** December 2025

## Compound of Interest

Compound Name: Toltrazuril

Cat. No.: B1682979

[Get Quote](#)

For Researchers, Scientists, and Drug Development Professionals

These application notes provide a comprehensive overview of the histopathological examination of intestinal lesions following treatment with **Toltrazuril**, a broad-spectrum anticoccidial agent. The protocols and data presented are intended to guide researchers in evaluating the efficacy of **Toltrazuril** and understanding its impact on intestinal pathology in various animal models of coccidiosis.

## Introduction

Coccidiosis, a parasitic disease of the intestinal tract caused by protozoa of the phylum Apicomplexa (primarily Eimeria and Isospora species), poses a significant threat to the health and productivity of livestock, particularly poultry.[1][2] **Toltrazuril** is a triazinetrione derivative widely used for the treatment and control of coccidiosis.[3] It is effective against all intracellular stages of coccidia, including both schizonts and gamonts, leading to a reduction in oocyst excretion and amelioration of clinical signs.[4][5] Histopathological examination is a critical tool for assessing the extent of intestinal damage caused by coccidial infections and for evaluating the therapeutic efficacy of anticoccidial drugs like **Toltrazuril**. [6][7] This document outlines standardized protocols for the histopathological assessment of intestinal lesions and presents quantitative data from relevant studies.

## Quantitative Data Summary

The following tables summarize quantitative data related to the efficacy of **Toltrazuril** treatment on intestinal lesions and other relevant parameters.

Table 1: Effect of **Toltrazuril** on Intestinal Lesion Scores in Broiler Chickens

Treatment Group	Eimeria Species	Gross Lesion Score (Mean)	Microscopic Lesion Score (Mean)	Oocyst Excretion (oocysts/gr of feces)	Reference
Infected, Untreated	E. tenella, E. brunetti	Significantly higher	Significantly higher	High	<a href="#">[8]</a>
Infected, Toltrazuril-treated	E. tenella, E. brunetti	Significantly lower	Significantly lower	Dramatically reduced	<a href="#">[8]</a> <a href="#">[9]</a>
Uninfected Control	N/A	0	0	0	<a href="#">[8]</a>

Table 2: Histopathological Changes in Japanese Quails with Coccidiosis Following **Toltrazuril** Treatment

Treatment Group	Dose of Toltrazuril	Key Histopathological Findings in the Cecum	Reference
Control (Infected, Untreated)	0 mg/kg	Large number of multiplying merozoites in mucosa; destruction of mucosa.	[6]
Group I (Infected, Treated)	7 mg/kg	Destruction of the folds, with presence of merozoites in crypts.	[6]
Group II (Infected, Treated)	14 mg/kg	Total atrophy of the mucosa (crypts and folds) with parchment-like membrane.	[6]
Group III (Infected, Treated)	24.5 mg/kg	Regeneration of mucosa; hyperplasia of epithelial cells and crypts.	[6]

## Experimental Protocols

### Animal Model and Toltrazuril Administration

A common model for studying coccidiosis involves the experimental infection of broiler chickens.

#### Protocol 1: Induction of Coccidiosis and **Toltrazuril** Treatment in Broiler Chickens

- **Animal Housing:** House one-day-old broiler chicks in a clean, disinfected environment with *ad libitum* access to feed and water.
- **Infection:** At 14 days of age, orally inoculate each chick with a suspension of sporulated *Eimeria* oocysts (e.g., a mixed culture of *E. acervulina*, *E. maxima*, and *E. tenella*).[\[7\]](#)[\[10\]](#)

- Treatment Groups: Divide the birds into the following groups:
  - Group A (Negative Control): Uninfected and untreated.
  - Group B (Positive Control): Infected and untreated.
  - Group C (**Toltrazuril** Treatment): Infected and treated with **Toltrazuril**.
- **Toltrazuril** Administration: Administer **Toltrazuril** (e.g., Baycox® 2.5% solution) in the drinking water at a concentration of 7 mg/kg body weight for two consecutive days.<sup>[3][10]</sup> Treatment can be initiated at a predetermined time post-infection (e.g., 2 days post-infection).<sup>[7]</sup>
- Monitoring: Observe the birds daily for clinical signs of coccidiosis (e.g., bloody diarrhea, ruffled feathers, depression).<sup>[7]</sup>

## Sample Collection and Histopathological Processing

### Protocol 2: Intestinal Tissue Collection and Processing

- Euthanasia and Necropsy: At a predetermined time point (e.g., 7 days post-infection), euthanize a subset of birds from each group.
- Gross Examination: Perform a necropsy and grossly examine the intestines for lesions such as thickening of the intestinal wall, presence of blood and mucus, and white or red spots on the serosal surface.<sup>[11]</sup>
- Tissue Sampling: Collect tissue samples (approximately 2 cm in length) from the duodenum, jejunum, and cecum.<sup>[12]</sup>
- Fixation: Immediately fix the tissue samples in 10% neutral buffered formalin for at least 24 hours.<sup>[6]</sup>
- Processing and Embedding: Dehydrate the fixed tissues through a graded series of ethanol, clear in xylene, and embed in paraffin wax.
- Sectioning: Cut 5 µm thick sections from the paraffin blocks using a microtome.

- **Staining:** Mount the sections on glass slides and stain with Hematoxylin and Eosin (H&E) for routine histopathological evaluation.[\[6\]](#)

## Histopathological Lesion Scoring

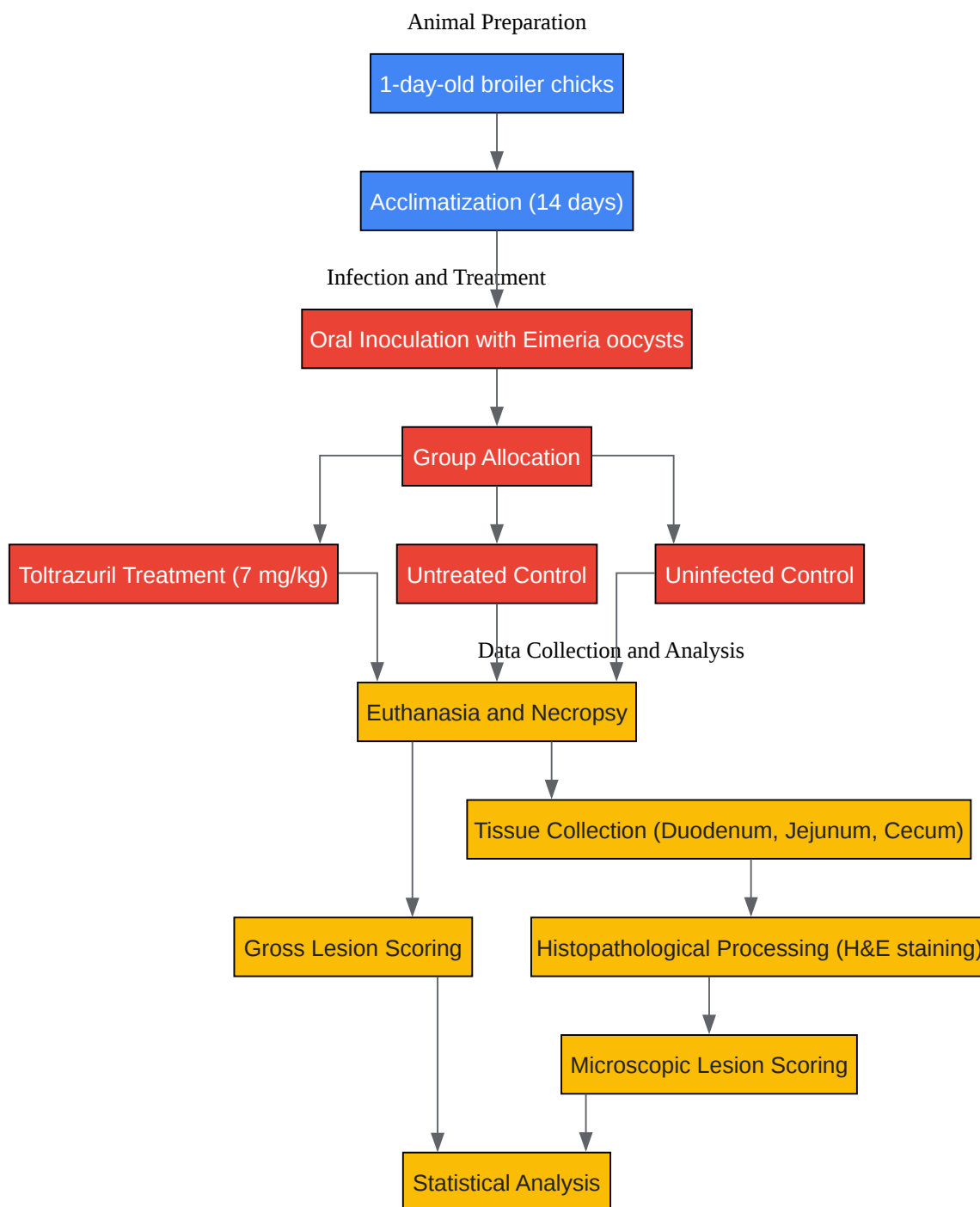
### Protocol 3: Microscopic Lesion Scoring

The severity of microscopic lesions can be graded using a scoring system adapted from Johnson and Reid (1970).

- **Examine Slides:** Examine the H&E stained slides under a light microscope in a blinded fashion.
- **Scoring Criteria:** Assign a score from 0 to 4 for each intestinal section based on the following criteria:
  - **Score 0:** Normal intestinal architecture with no evidence of parasites or inflammation.
  - **Score 1:** Mild infiltration of inflammatory cells in the lamina propria; a few scattered parasites may be present.
  - **Score 2:** Moderate inflammation with some villous atrophy and crypt hyperplasia; parasites are more numerous.
  - **Score 3:** Severe inflammation, marked villous atrophy, and crypt necrosis; large numbers of parasites are present.
  - **Score 4:** Extensive necrosis and hemorrhage of the intestinal mucosa, with sloughing of the epithelium; numerous parasites are visible.
- **Data Analysis:** Calculate the mean lesion score for each treatment group and compare them statistically.

## Visualizations

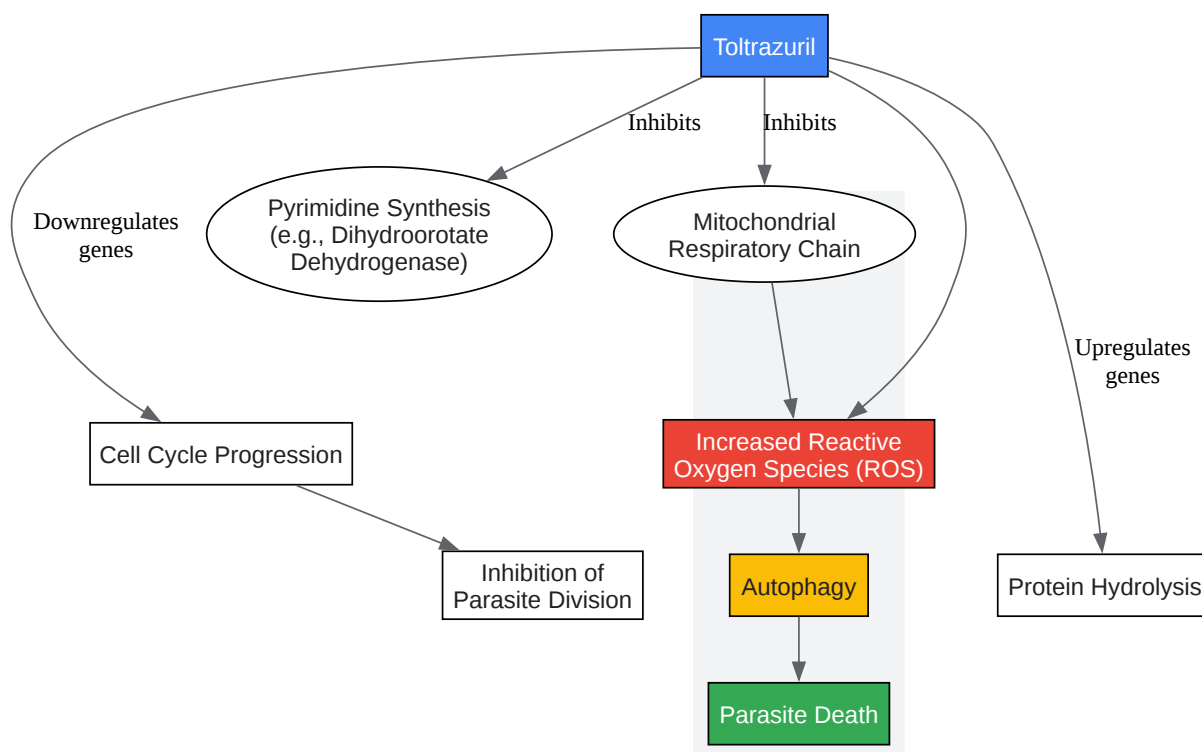
## Experimental Workflow



[Click to download full resolution via product page](#)

Caption: Experimental workflow for evaluating **Toltrazuril** efficacy.

## Proposed Signaling Pathway of Toltrazuril's Action



[Click to download full resolution via product page](#)

### Need Custom Synthesis?

BenchChem offers custom synthesis for rare earth carbides and specific isotopic labeling.

Email: [info@benchchem.com](mailto:info@benchchem.com) or [Request Quote Online](#).

## References

- 1. In Vitro Transcriptional Response of Eimeria tenella to Toltrazuril Reveals That Oxidative Stress and Autophagy Contribute to Its Anticoccidial Effect - PMC [pmc.ncbi.nlm.nih.gov]
- 2. toltrazurilshop.com [toltrazurilshop.com]
- 3. Toltrazuril - referral | European Medicines Agency (EMA) [ema.europa.eu]
- 4. toltrazurilshop.com [toltrazurilshop.com]
- 5. Immunity to coccidiosis after treatment with toltrazuril - PubMed [pubmed.ncbi.nlm.nih.gov]
- 6. researchgate.net [researchgate.net]
- 7. Field Evaluation of Toltrazuril and Garlic for Treatment of Coccidiosis in Broiler Chickens | Journal of Advanced Veterinary Research [advetresearch.com]
- 8. researchgate.net [researchgate.net]
- 9. researchgate.net [researchgate.net]
- 10. researchgate.net [researchgate.net]
- 11. eliasnutri.wordpress.com [eliasnutri.wordpress.com]
- 12. tandfonline.com [tandfonline.com]
- To cite this document: BenchChem. [Application Notes and Protocols: Histopathological Examination of Intestinal Lesions After Toltrazuril Treatment]. BenchChem, [2025]. [Online PDF]. Available at: [https://www.benchchem.com/product/b1682979#histopathological-examination-of-intestinal-lesions-after-toltrazuril-treatment]

---

### Disclaimer & Data Validity:

The information provided in this document is for Research Use Only (RUO) and is strictly not intended for diagnostic or therapeutic procedures. While BenchChem strives to provide accurate protocols, we make no warranties, express or implied, regarding the fitness of this product for every specific experimental setup.

**Technical Support:** The protocols provided are for reference purposes. Unsure if this reagent suits your experiment? [[Contact our Ph.D. Support Team for a compatibility check](#)]

**Need Industrial/Bulk Grade?** [Request Custom Synthesis Quote](#)



# BenchChem

Our mission is to be the trusted global source of essential and advanced chemicals, empowering scientists and researchers to drive progress in science and industry.

## Contact

Address: 3281 E Guasti Rd

Ontario, CA 91761, United States

Phone: (601) 213-4426

Email: [info@benchchem.com](mailto:info@benchchem.com)