

Application Notes and Protocols: Gadoxetic Acid in Pediatric Liver Imaging

Author: BenchChem Technical Support Team. **Date:** December 2025

Compound of Interest

Compound Name: *Gadoxetic acid*

Cat. No.: *B1262754*

[Get Quote](#)

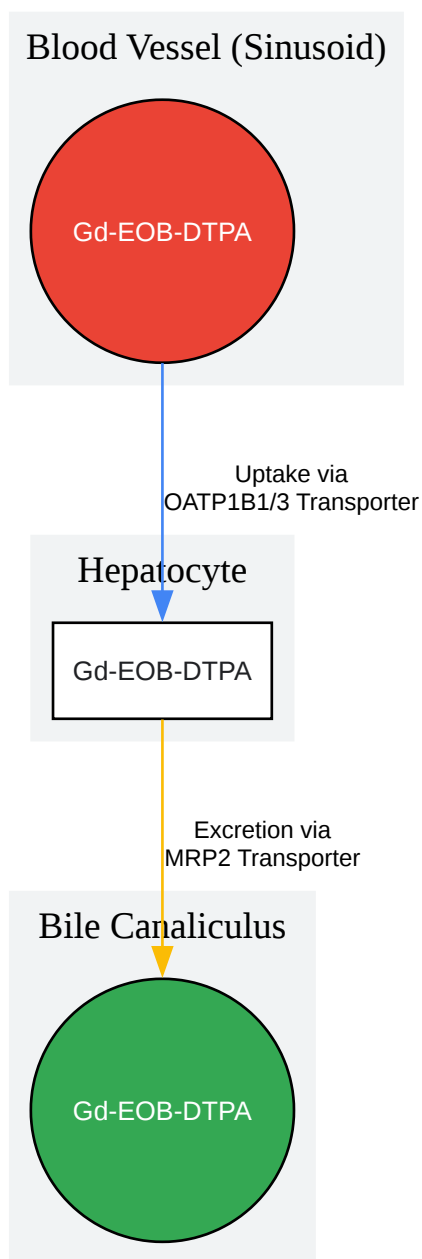
For Researchers, Scientists, and Drug Development Professionals

Introduction

Gadoxetic acid (Gd-EOB-DTPA) is a gadolinium-based, liver-specific magnetic resonance imaging (MRI) contrast agent.[1] Its unique properties allow for a comprehensive evaluation of the liver, combining the benefits of dynamic, perfusion-based imaging with a hepatocyte-specific phase.[2] Approximately 50% of the injected dose is taken up by functional hepatocytes and subsequently excreted into the biliary system, providing both morphological and functional information about the liver and biliary tree.[3] While its use in adults is well-established, its application in the pediatric population is growing for the characterization of liver lesions, assessment of biliary diseases, and evaluation of liver function.[4][5]

Mechanism of Action

Gadoxetic acid exhibits a dual mechanism. Initially, it distributes in the extracellular fluid space, similar to conventional extracellular gadolinium agents, allowing for dynamic assessment of vascularity during the arterial, portal venous, and transitional phases. Subsequently, it is actively transported into hepatocytes by organic anion transporting polypeptides (OATP1B1/3) on the sinusoidal membrane.[3] It is then excreted into the bile canaliculi via the multidrug resistance-associated protein 2 (MRP2).[3] This hepatocyte-specific uptake and excretion pathway is the basis for the hepatobiliary phase (HBP), which is typically acquired 20 minutes post-injection.[6]



[Click to download full resolution via product page](#)

Caption: Cellular mechanism of **gadoxetic acid** uptake and excretion.

Safety and Administration in Pediatrics

The off-label use of **gadoxetic acid** in patients under 18 is increasingly common.[6] Studies have shown that it is generally safe and well-tolerated in the pediatric population.

3.1 Adverse Events A multicenter retrospective study found no statistically significant difference in the incidence of acute adverse events between **gadoxetic acid** and extracellular contrast agents (ECAs) in children.[\[7\]](#)[\[8\]](#)

Table 1: Incidence of Acute Adverse Events with **Gadoxetic Acid** in Pediatrics

Study Population	Gadoxetic Acid Group (Incidence)	Extracellular Agent Group (Incidence)	Odds Ratio (95% CI)	P-value	Severity of Events (Gadoxetic Acid)	Citation
------------------	----------------------------------	---------------------------------------	---------------------	---------	-------------------------------------	----------

| 1629 MRI exams in patients ≤18 years | 1.3% (5 of 373 exams) | 0.9% (11 of 1256 exams) | 1.55 (0.54, 4.46) | 0.42 | 4 mild, 1 moderate | [\[7\]](#)[\[8\]](#) |

3.2 Administration Protocol

- Dosage: A single intravenous bolus injection of 0.1 mL/kg body weight (equivalent to 0.025 mmol/kg body weight).[\[9\]](#)
- Injection Rate: Typically 1-2 mL/sec followed by a saline flush.[\[7\]](#)
- Patient Preparation: Standard MRI safety screening. For young children unable to cooperate, sedation or general anesthesia may be required, which should be managed by a pediatric anesthesiologist.[\[10\]](#)

Application 1: Characterization of Focal Liver Lesions (FLLs)

Gadoxetic acid-enhanced MRI is highly valuable for the non-invasive diagnosis of pediatric FLLs, particularly in differentiating focal nodular hyperplasia (FNH) from hepatocellular adenoma (HCA) and other lesions.[\[4\]](#)[\[11\]](#)[\[12\]](#)

4.1 Experimental Protocol: FLL Characterization

- Patient Preparation: Fasting for 4-6 hours is recommended to promote gallbladder filling and reduce bowel peristalsis.
- Pre-Contrast Imaging:
 - T2-weighted single-shot fast spin-echo (SSFSE) axial and coronal.
 - T2-weighted fat-suppressed fast spin-echo (FSE) axial.
 - In-phase and out-of-phase T1-weighted gradient-echo (GRE) axial to detect fat.
 - Diffusion-weighted imaging (DWI) with ADC map.
 - 3D T1-weighted GRE with fat suppression (e.g., VIBE, LAVA) for dynamic series baseline.
- Contrast Administration: Administer 0.025 mmol/kg of **gadoteric acid** IV.[9]
- Post-Contrast Dynamic Imaging: Acquire images using a 3D T1-weighted GRE sequence with fat suppression at the following phases:
 - Late Arterial Phase: ~20-30 seconds post-injection.
 - Portal Venous Phase: ~60-80 seconds post-injection.
 - Transitional Phase: ~3-5 minutes post-injection.
- Hepatobiliary Phase (HBP) Imaging:
 - Acquire images 20 minutes post-injection using the same 3D T1-weighted GRE sequence. [6] This phase is critical for assessing hepatocyte function within lesions.

4.2 Data Presentation: Diagnostic Performance

The key differentiator for many lesions is their appearance on the HBP. Lesions with functional hepatocytes (like FNH) will retain the contrast agent, while lesions without (like most HCAs, metastases, and cysts) will appear hypointense relative to the enhanced liver parenchyma.[11] [13]

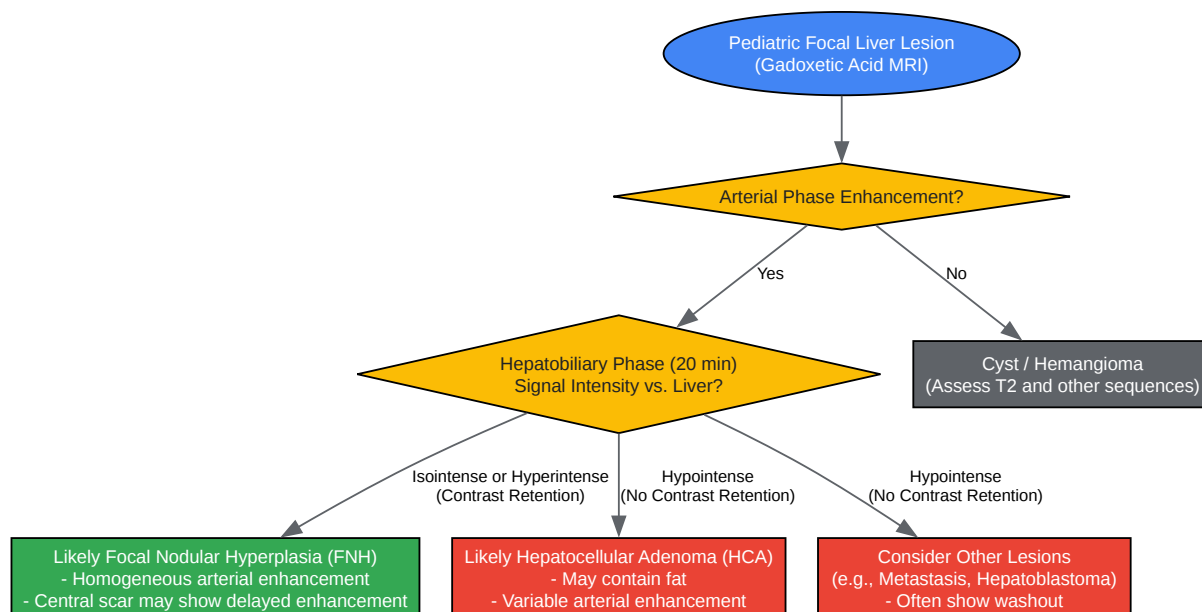
Table 2: Diagnostic Performance of **Gadoxetic Acid** MRI for Differentiating FNH and HCA in Children

MRI Feature / Metric	Sensitivity	Specificity	Key Finding	Citation
Qualitative HBP Appearance			FNHs are typically iso- or hyperintense on HBP; most HCAs are hypointense.	[11] [12]
Quantitative (SIRpost-pre)	100%	100%	Signal Intensity Ratio (post-contrast HBP vs. pre-contrast) significantly differs between FNH and HCA.	[11] [12]

| Quantitative (LLCER) | 100% | 100% | Liver-to-Lesion Contrast Enhancement Ratio significantly differs between FNH and HCA. [\[11\]](#)[\[12\]](#) |

SIRpost-pre and LLCER are calculated quantitative metrics that enhance diagnostic accuracy. [\[11\]](#)

4.3 Visualization: Diagnostic Workflow for Pediatric FLLs



[Click to download full resolution via product page](#)

Caption: Simplified diagnostic workflow for pediatric focal liver lesions.

Application 2: Assessment of Biliary Anatomy and Function

Gadoxetic acid is excreted into the biliary system, making it an excellent tool for evaluating biliary anatomy and patency, which is crucial in conditions like biliary atresia.[14][15]

5.1 Experimental Protocol: Biliary Imaging

- Standard Protocol: Follow the FLL characterization protocol (Section 4.1) through the 20-minute HBP.
- Delayed Biliary Imaging (Optional): If biliary excretion is not clearly visualized at 20 minutes, delayed imaging can be performed up to 120 minutes or longer post-injection.[6]

- Sequences: Heavily T2-weighted sequences (MRCP) should be performed pre-contrast to delineate the biliary tree anatomy. HBP T1-weighted images provide functional information on contrast excretion into the ducts.

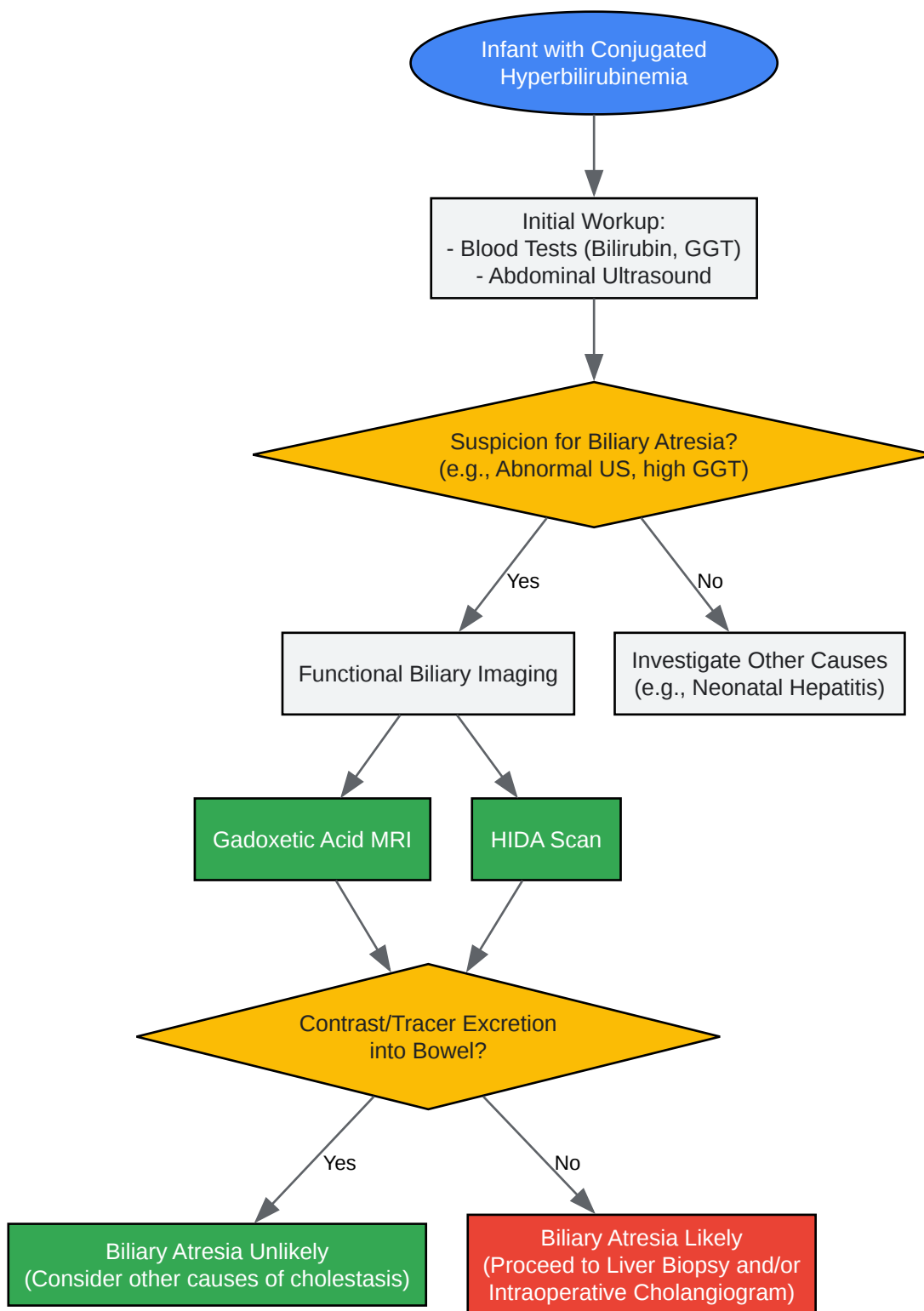
5.2 Data Presentation: Biliary Atresia Diagnosis The primary role of **gadoxetic acid** MRI in suspected biliary atresia is to demonstrate or exclude communication between the intrahepatic biliary system and the bowel. While hepatobiliary scintigraphy (HIDA scan) is a common tool, MRI offers superior anatomical detail without radiation exposure.[\[6\]](#)[\[14\]](#)

Table 3: Imaging Findings in the Evaluation of Biliary Atresia

Imaging Modality	Key Finding Suggesting Biliary Atresia	Key Finding Arguing Against Biliary Atresia	Citation
Ultrasound	Small or absent gallbladder; "triangular cord" sign.	Normal gallbladder and common bile duct.	[14] [16]
Hepatobiliary Scintigraphy (HIDA)	No excretion of radiotracer into the small intestine.	Visualization of tracer in the small intestine.	[14] [17]

| **Gadoxetic Acid** MRI (HBP) | Lack of contrast material excretion into the biliary tree and duodenum on delayed images. | Presence of contrast material within the biliary ducts and duodenum. [\[6\]](#) |

5.3 Visualization: Biliary Atresia Diagnostic Pathway



[Click to download full resolution via product page](#)

Caption: Role of functional imaging in the diagnostic pathway for biliary atresia.

Application 3: Quantitative Liver Function Assessment

The degree of liver enhancement in the HBP is proportional to hepatocyte function, allowing for non-invasive, quantitative assessment of liver function.[3] This has applications in diffuse liver diseases like non-alcoholic fatty liver disease (NAFLD) and in assessing liver transplant grafts. [6][9]

6.1 Experimental Protocol: Quantitative Analysis

- Image Acquisition: Follow the standard protocol (Section 4.1) to acquire pre-contrast and 20-minute HBP T1-weighted images.
- Region of Interest (ROI) Placement:
 - Draw ROIs in representative areas of the liver parenchyma, avoiding major vessels and artifacts.
 - Draw a corresponding ROI in a reference muscle (e.g., paraspinal muscle) or the spleen for calculating enhancement ratios.
- Calculation of Metrics: Various quantitative parameters can be derived.[18][19]
 - Relative Enhancement (RE): $(SI_{\text{hbp}} - SI_{\text{pre}}) / SI_{\text{pre}}$
 - Liver-to-Spleen Contrast Ratio: $(SI_{\text{liver_hbp}} / SI_{\text{spleen_hbp}})$
 - Liver-to-Muscle Ratio (LMR): $(SI_{\text{liver_hbp}} / SI_{\text{muscle_hbp}})$

6.2 Data Presentation: Correlation with Liver Disease

Quantitative **gadoteric acid** MRI parameters correlate with biochemical markers of liver function and histological severity of liver disease.

Table 4: Quantitative **Gadoteric Acid** Metrics in Pediatric Liver Disease

Metric	Disease Context	Key Finding	Citation
Relative Enhancement (RE)	NAFLD	RE can differentiate simple steatosis from nonalcoholic steatohepatitis (NASH). An RE cutoff of 1.24 showed high sensitivity for NASH in one adult study.	[3]
Relative Enhancement (RE)	Pediatric Obesity / NAFLD	RE was found to be a useful imaging biomarker for screening NAFLD in pediatric obesity.	[9]
Functional Liver Imaging Score (FLIS)	Chronic Liver Disease	A score based on HBP features (parenchymal enhancement, biliary excretion) that correlates with liver function and patient outcomes.	[3]

| Liver-to-Muscle Ratio (LMR) | Chronic Liver Disease | LMR is a simple, easy-to-use parameter that correlates strongly with Child-Pugh and MELD scores. |[18][19] |

Considerations and Limitations

- Transient Severe Motion (TSM): Some patients, particularly older children and adolescents, may experience transient dyspnea or motion artifacts during the arterial phase.[10][20] This phenomenon is less common in children under 10 years of age.[20]

- Impaired Liver Function: In patients with severe hepatocellular dysfunction, uptake of **gadoteric acid** may be poor, leading to suboptimal parenchymal enhancement in the HBP and limiting its diagnostic utility.[21]
- Renal Function: As with all gadolinium-based contrast agents, caution should be exercised in patients with severe renal impairment.[22]

Need Custom Synthesis?

BenchChem offers custom synthesis for rare earth carbides and specific isotopic labeling.

Email: info@benchchem.com or [Request Quote Online](#).

References

- 1. Characterization of pediatric liver lesions with gadoterate disodium - PubMed [pubmed.ncbi.nlm.nih.gov]
- 2. [PDF] Gadoterate disodium-enhanced MRI of the liver: part 1, protocol optimization and lesion appearance in the noncirrhotic liver. | Semantic Scholar [semanticscholar.org]
- 3. Quantification of liver function using gadoteric acid-enhanced MRI - PMC [pmc.ncbi.nlm.nih.gov]
- 4. Characterization of pediatric liver lesions with gadoterate disodium | Semantic Scholar [semanticscholar.org]
- 5. ajronline.org [ajronline.org]
- 6. austinpublishinggroup.com [austinpublishinggroup.com]
- 7. pubs.rsna.org [pubs.rsna.org]
- 8. snu.elsevierpure.com [snu.elsevierpure.com]
- 9. mdpi.com [mdpi.com]
- 10. Influence of age on gadoteric acid disodium-induced transient respiratory motion artifacts in pediatric liver MRI - PMC [pmc.ncbi.nlm.nih.gov]
- 11. academic.oup.com [academic.oup.com]
- 12. Gadoteric acid-enhanced MRI in differentiating focal nodular hyperplasia from hepatocellular adenoma in children - PubMed [pubmed.ncbi.nlm.nih.gov]

- 13. Safety and Efficacy of Gadoxetate Disodium—Enhanced Liver MRI in Pediatric Patients Aged >2 Months to <18 Years—Results of a Retrospective, Multicenter Study - PMC [pmc.ncbi.nlm.nih.gov]
- 14. Biliary atresia - Diagnosis and treatment - Mayo Clinic [mayoclinic.org]
- 15. Diagnosing Biliary Atresia in Children | NYU Langone Health [nyulangone.org]
- 16. Biliary Atresia in Children: Update on disease mechanism, therapies, and patient outcomes - PMC [pmc.ncbi.nlm.nih.gov]
- 17. Pediatric Biliary Atresia Workup: Laboratory Studies, Imaging Studies, Other Tests [emedicine.medscape.com]
- 18. tandfonline.com [tandfonline.com]
- 19. Quantitative evaluation of liver function with gadoxetic acid enhanced MRI: Comparison among signal intensity-, T1-relaxometry-, and dynamic-hepatocyte-specific-contrast-enhanced MRI- derived parameters - PubMed [pubmed.ncbi.nlm.nih.gov]
- 20. Influence of age on gadoxetic acid disodium-induced transient respiratory motion artifacts in pediatric liver MRI - PubMed [pubmed.ncbi.nlm.nih.gov]
- 21. pubs.rsna.org [pubs.rsna.org]
- 22. Best practices for pediatric liver MRI: guidelines from members of the Society for Pediatric Radiology Magnetic Resonance and Abdominal Imaging Committees - PMC [pmc.ncbi.nlm.nih.gov]
- To cite this document: BenchChem. [Application Notes and Protocols: Gadoxetic Acid in Pediatric Liver Imaging]. BenchChem, [2025]. [Online PDF]. Available at: [https://www.benchchem.com/product/b1262754#application-of-gadoxetic-acid-in-pediatric-liver-imaging]

Disclaimer & Data Validity:

The information provided in this document is for Research Use Only (RUO) and is strictly not intended for diagnostic or therapeutic procedures. While BenchChem strives to provide accurate protocols, we make no warranties, express or implied, regarding the fitness of this product for every specific experimental setup.

Technical Support: The protocols provided are for reference purposes. Unsure if this reagent suits your experiment? [[Contact our Ph.D. Support Team for a compatibility check](#)]

Need Industrial/Bulk Grade? [Request Custom Synthesis Quote](#)

BenchChem

Our mission is to be the trusted global source of essential and advanced chemicals, empowering scientists and researchers to drive progress in science and industry.

Contact

Address: 3281 E Guasti Rd

Ontario, CA 91761, United States

Phone: (601) 213-4426

Email: info@benchchem.com