

Application Notes: Ultrasound-Guided Aspiration of Pyomyositis Abscesses

Author: BenchChem Technical Support Team. **Date:** December 2025

Compound of Interest

Compound Name: *Piomy*

Cat. No.: *B1172056*

[Get Quote](#)

Introduction

Pyomyositis is a primary bacterial infection of skeletal muscle, which can lead to the formation of a localized, pus-filled abscess. Once considered a disease of tropical climates, its incidence is increasing in temperate regions, often associated with immunocompromised states. The infection typically progresses through three stages: an initial invasive stage with diffuse muscle inflammation, a suppurative stage where a distinct abscess forms (the stage at which most diagnoses occur), and a late stage characterized by systemic sepsis if left untreated.

Staphylococcus aureus is the most common causative pathogen, responsible for up to 90% of cases.

Ultrasound-guided aspiration serves as a critical, minimally invasive procedure for both the diagnosis and treatment of pyomyositis abscesses. It allows for the definitive identification of a purulent collection, facilitates the collection of fluid for microbiological analysis to guide targeted antibiotic therapy, and can serve as a primary therapeutic intervention to drain the abscess. This technique offers a safe and effective alternative to open surgical drainage, particularly for accessible abscesses.

Sonographic Features of Pyomyositis

Ultrasound is a highly effective initial imaging modality for pyomyositis, especially in the extremities. The sonographic appearance evolves with the stage of the infection:

- **Early/Invasive Stage:** Findings can be subtle, showing diffuse muscle edema and a loss of the normal, striated muscle architecture. The affected muscle may appear hypoechoic (darker) compared to surrounding healthy tissue.
- **Late/Suppurative Stage:** The hallmark finding is a well-defined, hypoechoic or anechoic fluid collection, consistent with an abscess. The collection will be non-compressible, may contain internal debris, and will not demonstrate internal blood flow on color Doppler imaging.

Data Presentation

Table 1: Common Causative Pathogens in Pyomyositis

Pathogen Category	Organism	Prevalence / Notes
Most Common	Staphylococcus aureus	Accounts for 60-90% of cases. Both Methicillin-sensitive (MSSA) and Methicillin-resistant (MRSA) strains are prevalent.
Common	Streptococcus species	Group A Streptococcus is a notable pathogen.
Less Common	Gram-negative enteric bacteria	Includes Escherichia coli, Klebsiella, Pseudomonas.
Anaerobes	Bacteroides fragilis	Can be involved, particularly in polymicrobial infections.

Table 2: Procedural and Outcome Data

Parameter	Finding	Source / Notes
Diagnostic Confirmation	Aspiration of pus from the muscle confirms the diagnosis.	Blood cultures are only positive in 5-30% of patients.
Treatment Success Rate	84% overall successful outcomes in a study of 61 patients managed with drainage and antibiotics.	Drainage is required in 40-70% of cases where an abscess has formed.
Aspirated Volume (Example)	15 cc of fluid was aspirated from an obturator internus abscess.	Volume varies significantly based on abscess size and location.
Abscess Size (Example)	A 5.3 x 2.2 cm abscess was identified via CT prior to drainage.	MRI is considered the gold standard for assessing abscess size and extent.

Protocols

Protocol 1: Ultrasound-Guided Needle Aspiration of a Pyomyositis Abscess

This protocol outlines the procedure for the diagnostic and therapeutic aspiration of a muscle abscess under real-time ultrasound guidance.

1. Materials and Equipment

- Ultrasound machine with a high-frequency linear transducer (5-12 MHz) for superficial muscles or a curvilinear transducer for deeper muscles.
- Sterile transducer cover and sterile ultrasound gel.
- Skin preparation solution (e.g., chlorhexidine or povidone-iodine).
- Sterile drapes, gloves, and gown.
- Local anesthetic (e.g., 1% lidocaine) with a small gauge needle (25-27G) and syringe.

- Aspiration needle/catheter assembly (e.g., 18-22G needle for diagnosis, or a larger 8-14 French drainage catheter for therapy).
- Connecting tubing and collection syringes (10-60 mL).
- Sterile specimen containers for microbiology and cytology.
- Sterile dressing.

2. Patient Preparation

- Obtain informed consent from the patient.
- Position the patient to provide optimal access to the target muscle and for patient comfort.
- Perform a preliminary ultrasound scan to confirm the presence, location, size, and depth of the abscess. Identify any adjacent neurovascular structures to avoid.

3. Procedure

- Prepare the skin over the target area with an antiseptic solution and allow it to dry.
- Drape the area with sterile drapes.
- Apply the sterile transducer cover and sterile gel.
- Administer local anesthetic into the skin and subcutaneous tissues overlying the planned needle entry site.
- Using real-time ultrasound guidance, visualize the abscess collection. The "in-plane" technique, where the entire needle shaft and tip are visible, is preferred.
- Advance the aspiration needle through the skin and muscle tissue directly into the abscess cavity.
- Once the needle tip is confirmed to be within the abscess, aspirate the purulent fluid using a syringe. If the collection is large, multiple syringes may be needed.

- Collect samples of the aspirate into sterile containers for Gram stain, aerobic and anaerobic bacterial cultures, and any other indicated tests.
- If therapeutic drainage is the goal, completely evacuate the abscess cavity. If a drainage catheter is to be placed, it can be inserted over a guidewire (Seldinger technique).
- Once aspiration is complete, withdraw the needle.
- Clean the skin and apply a sterile dressing.

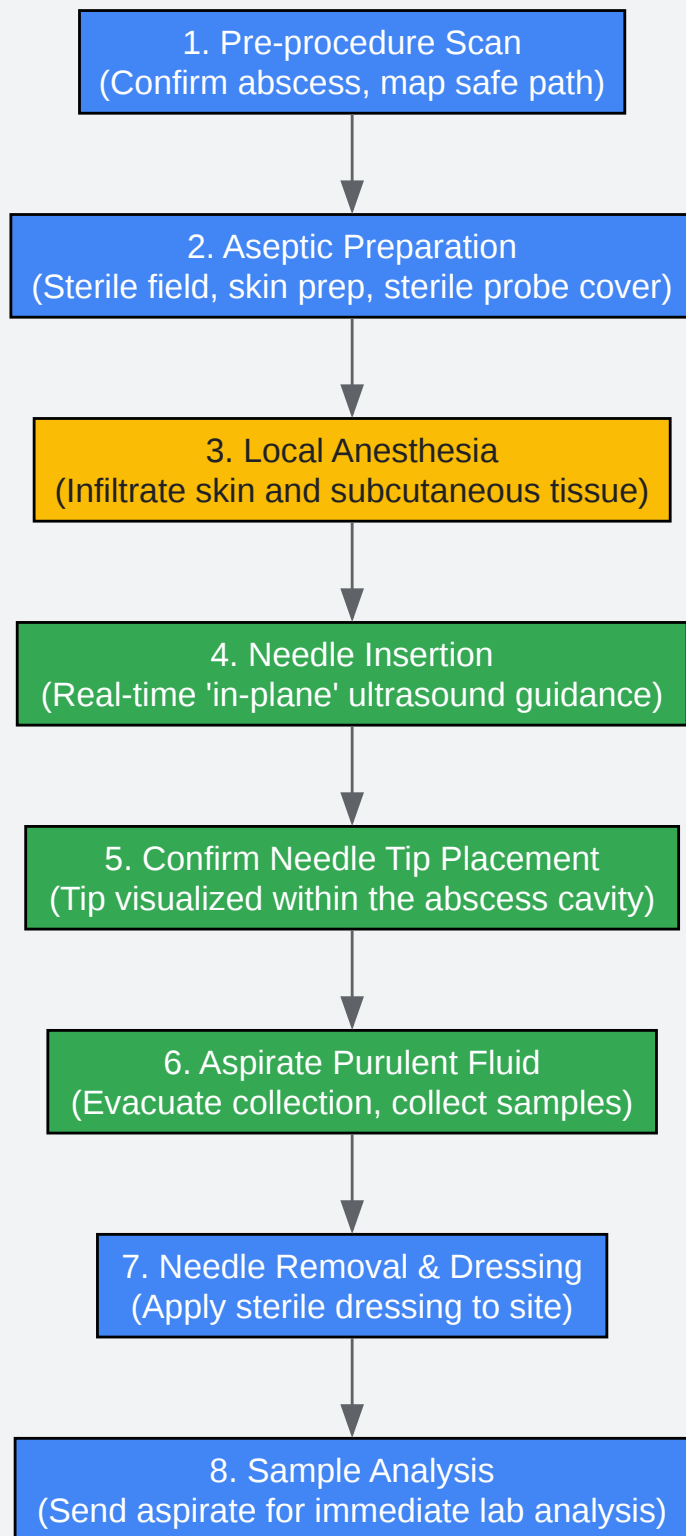
4. Post-Procedure Analysis

- Send the aspirated fluid to the microbiology laboratory immediately for analysis.
- Initiate or adjust antibiotic therapy based on Gram stain results, pending final culture and sensitivity data. Vancomycin is often recommended as initial empirical therapy to cover for MRSA.

Visualizations

Caption: Logical workflow for the diagnosis and management of pyomyositis.

Ultrasound-Guided Aspiration: Step-by-Step Workflow



[Click to download full resolution via product page](#)

Caption: A sequential workflow for the pyomyositis abscess aspiration procedure.

- To cite this document: BenchChem. [Application Notes: Ultrasound-Guided Aspiration of Pyomyositis Abscesses]. BenchChem, [2025]. [Online PDF]. Available at: [https://www.benchchem.com/product/b1172056#ultrasound-guided-aspiration-of-pyomyositis-abscesses]

Disclaimer & Data Validity:

The information provided in this document is for Research Use Only (RUO) and is strictly not intended for diagnostic or therapeutic procedures. While BenchChem strives to provide accurate protocols, we make no warranties, express or implied, regarding the fitness of this product for every specific experimental setup.

Technical Support: The protocols provided are for reference purposes. Unsure if this reagent suits your experiment? [[Contact our Ph.D. Support Team for a compatibility check](#)]

Need Industrial/Bulk Grade? [Request Custom Synthesis Quote](#)

BenchChem

Our mission is to be the trusted global source of essential and advanced chemicals, empowering scientists and researchers to drive progress in science and industry.

Contact

Address: 3281 E Guasti Rd
Ontario, CA 91761, United States
Phone: (601) 213-4426
Email: info@benchchem.com