

# Application Notes: MRI Protocols for the Early Detection of Pyomyositis

**Author:** BenchChem Technical Support Team. **Date:** December 2025

## Compound of Interest

Compound Name: *Piomy*

Cat. No.: *B1172056*

[Get Quote](#)

## Introduction

Pyomyositis is a primary bacterial infection of skeletal muscle, which can lead to abscess formation and significant morbidity if not diagnosed and treated promptly. Magnetic Resonance Imaging (MRI) is the imaging modality of choice for the early detection and characterization of pyomyositis due to its superior soft-tissue contrast and ability to detect early inflammatory changes within the muscle.[1][2] These application notes provide detailed MRI protocols and diagnostic guidance for researchers, scientists, and drug development professionals involved in the study and management of infectious myositis.

## Pathophysiology and Staging

The progression of pyomyositis is typically categorized into three stages, each with characteristic MRI findings:

- **Stage 1 (Invasive Stage):** This early stage is characterized by muscle edema and inflammation without a discrete, drainable abscess. Patients may present with nonspecific symptoms such as fever, myalgia, and localized tenderness. Early MRI is crucial at this stage for timely diagnosis and initiation of antibiotic therapy, which can prevent progression to more severe stages.
- **Stage 2 (Purulent Stage):** If left untreated, the infection progresses to form a liquid abscess within the muscle. MRI is highly sensitive in identifying these fluid collections.[3]

- **Stage 3 (Late Stage):** This stage involves the spread of infection to adjacent structures, including fascia, bone, and joints, and can lead to systemic complications such as sepsis.

## MRI for Early Detection of Pyomyositis

MRI is highly sensitive for detecting the early signs of pyomyositis, primarily muscle edema.<sup>[4]</sup>

### Key MRI Findings in Early Pyomyositis

In the initial invasive stage, MRI findings may be subtle and primarily reflect muscle inflammation. Key indicators include:

- **Muscle Enlargement:** The affected muscle may appear swollen and enlarged compared to contralateral healthy muscle.<sup>[3]</sup>
- **Increased T2 Signal:** The most prominent and earliest finding is increased signal intensity on T2-weighted and fluid-sensitive sequences like Short Tau Inversion Recovery (STIR).<sup>[5][6]</sup> This hyperintensity represents muscle edema and inflammation.
- **Preserved Muscle Architecture:** In the very early stages, the overall architecture of the muscle fibers is typically maintained.
- **Contrast Enhancement:** After the administration of a gadolinium-based contrast agent, there is often diffuse, heterogeneous, or homogeneous enhancement in the affected muscle on T1-weighted fat-suppressed images.<sup>[6]</sup>

As the infection progresses towards the purulent stage, a more organized fluid collection or abscess may become apparent. This is characterized by:

- **Rim Enhancement:** A well-defined, enhancing rim surrounding a central non-enhancing fluid collection is a hallmark of abscess formation.<sup>[6][7]</sup>
- **"Penumbra Sign":** A thin peripheral rim of T1 hyperintensity on pre-contrast images may be seen, representing vascularized granulation tissue.<sup>[8]</sup>

## Quantitative Data Summary

The following table summarizes the typical MRI sequences and their characteristic findings in the early (invasive) and purulent stages of pyomyositis.

MRI Sequence	Early Stage (Invasive) Findings	Purulent Stage (Abscess) Findings
T1-Weighted (T1W)	Isointense to slightly hypointense signal in the affected muscle. Muscle enlargement may be present.	A localized area of hypointensity representing the fluid collection. A subtle hyperintense rim may be visible ("penumbra sign"). <a href="#">[8]</a> <a href="#">[9]</a>
T2-Weighted (T2W) / STIR	Diffuse or patchy high signal intensity (hyperintensity) consistent with muscle edema. <a href="#">[5]</a> <a href="#">[6]</a>	A well-defined, markedly hyperintense fluid collection. A hypointense rim may be seen around the abscess. <a href="#">[9]</a>
Post-Contrast T1W (Fat-Suppressed)	Diffuse, often heterogeneous, enhancement of the inflamed muscle. <a href="#">[6]</a>	A distinct, peripheral rim of enhancement around a central non-enhancing fluid collection. <a href="#">[6]</a> <a href="#">[7]</a>
Diffusion-Weighted Imaging (DWI)	May show restricted diffusion in the inflamed muscle.	Restricted diffusion within the abscess cavity is a common finding. <a href="#">[8]</a>

## Experimental Protocols

### Patient Preparation

- **Informed Consent:** Obtain informed consent from the patient after explaining the procedure, potential risks, and benefits.
- **Screening:** Screen the patient for contraindications to MRI, such as the presence of pacemakers, certain metallic implants, or claustrophobia. Also, screen for contraindications to gadolinium-based contrast agents, including a history of allergic reactions or severe renal impairment.

- **Positioning:** Position the patient comfortably on the MRI table. The specific positioning will depend on the muscle group being imaged. Use coils appropriate for the body part to ensure a high signal-to-noise ratio.

## MRI Protocol for Suspected Pyomyositis

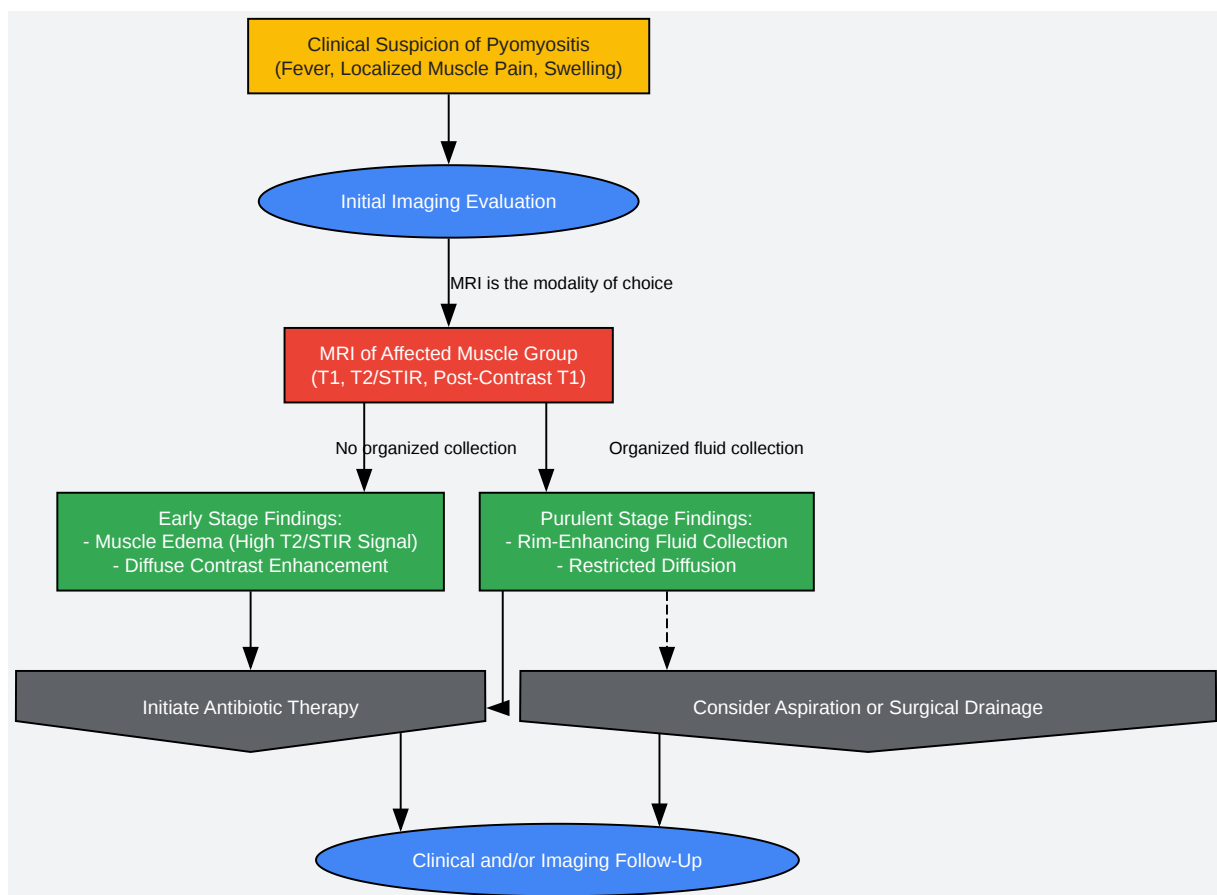
This protocol is designed to maximize the detection of early inflammatory changes and accurately delineate the extent of the infection.

- **Scout Images:** Obtain multi-planar scout images to localize the region of interest.
- **Axial T1-Weighted Sequence:**
  - **Purpose:** To assess the anatomy and identify any subtle signal changes in the muscle or surrounding tissues.
  - **Typical Parameters:** Repetition Time (TR): 400-600 ms; Echo Time (TE): 10-20 ms; Slice Thickness: 4-5 mm.
- **Axial and Coronal T2-Weighted Fat-Suppressed or STIR Sequences:**
  - **Purpose:** These are the most sensitive sequences for detecting muscle edema, which is the hallmark of early pyomyositis.[\[3\]](#)[\[4\]](#)
  - **Typical Parameters (STIR):** TR: 3000-5000 ms; TE: 30-60 ms; Inversion Time (TI): 140-160 ms; Slice Thickness: 4-5 mm.
- **Optional: Diffusion-Weighted Imaging (DWI):**
  - **Purpose:** To assess for restricted diffusion, which can be present in areas of intense inflammation and within abscess cavities.
  - **Typical Parameters:** At least two b-values (e.g., 0 and 800 s/mm<sup>2</sup>).
- **Administration of Gadolinium-Based Contrast Agent:**
  - **Dosage:** Standard weight-based dose (typically 0.1 mmol/kg).

- Administration: Intravenous injection.
- Post-Contrast Axial and Coronal T1-Weighted Fat-Suppressed Sequences:
  - Purpose: To evaluate the pattern of enhancement. Diffuse enhancement is seen in early pyomyositis, while rim enhancement is characteristic of an abscess.<sup>[6][7]</sup>
  - Typical Parameters: TR: 400-600 ms; TE: 10-20 ms; Slice Thickness: 4-5 mm.

## Mandatory Visualizations

### Diagnostic Workflow for Suspected Pyomyositis



[Click to download full resolution via product page](#)

Caption: Diagnostic workflow for suspected pyomyositis using MRI.

#### Need Custom Synthesis?

BenchChem offers custom synthesis for rare earth carbides and specific isotopic labeling.

Email: [info@benchchem.com](mailto:info@benchchem.com) or [Request Quote Online](#).

## References

- 1. [The role of MRI in the early diagnosis of pyomyositis in children] - PubMed [pubmed.ncbi.nlm.nih.gov]
- 2. droracle.ai [droracle.ai]
- 3. MRI of myositis and other urgent muscle-related disorders - PMC [pmc.ncbi.nlm.nih.gov]
- 4. droracle.ai [droracle.ai]
- 5. ajronline.org [ajronline.org]
- 6. Magnetic resonance imaging of pyomyositis in 43 cases - PubMed [pubmed.ncbi.nlm.nih.gov]
- 7. Bacterial pyomyositis: MRI and clinical correlation - PubMed [pubmed.ncbi.nlm.nih.gov]
- 8. ajronline.org [ajronline.org]
- 9. pubs.rsna.org [pubs.rsna.org]
- To cite this document: BenchChem. [Application Notes: MRI Protocols for the Early Detection of Pyomyositis]. BenchChem, [2025]. [Online PDF]. Available at: [https://www.benchchem.com/product/b1172056#mri-protocols-for-early-detection-of-pyomyositis]

### Disclaimer & Data Validity:

The information provided in this document is for Research Use Only (RUO) and is strictly not intended for diagnostic or therapeutic procedures. While BenchChem strives to provide accurate protocols, we make no warranties, express or implied, regarding the fitness of this product for every specific experimental setup.

**Technical Support:** The protocols provided are for reference purposes. Unsure if this reagent suits your experiment? [[Contact our Ph.D. Support Team for a compatibility check](#)]

**Need Industrial/Bulk Grade?** [Request Custom Synthesis Quote](#)

## BenchChem

Our mission is to be the trusted global source of essential and advanced chemicals, empowering scientists and researchers to drive progress in science and industry.

### Contact

Address: 3281 E Guasti Rd  
Ontario, CA 91761, United States  
Phone: (601) 213-4426  
Email: [info@benchchem.com](mailto:info@benchchem.com)