

Application Notes: Histopathological Staining of Pyomyositis Muscle Biopsy

Author: BenchChem Technical Support Team. **Date:** December 2025

Compound of Interest

Compound Name: *Piomy*

Cat. No.: *B1172056*

[Get Quote](#)

For Researchers, Scientists, and Drug Development Professionals

Introduction

Pyomyositis, a primary bacterial infection of skeletal muscle, often culminates in abscess formation. Historically prevalent in tropical climates, its incidence is rising in temperate regions, frequently associated with immunosuppression, though it can also affect healthy individuals. The most common causative agent is *Staphylococcus aureus*, with other bacteria such as *Streptococcus pyogenes* and gram-negative bacilli being less frequent. Muscle biopsy is a crucial tool for the definitive diagnosis of pyomyositis, allowing for the visualization of characteristic pathological changes and the identification of the infectious agent. Histopathological examination helps differentiate pyomyositis from other inflammatory myopathies and non-infectious conditions. This document provides detailed protocols for the essential staining techniques used to evaluate a muscle biopsy for pyomyositis.

Pathological Stages and Corresponding Histology

Pyomyositis typically progresses through three clinical and pathological stages, each with distinct histological features:

- **Stage 1 (Invasive Stage):** This initial phase is characterized by subtle, diffuse inflammation. Histologically, muscle fibers may appear edematous, and there is often a sparse infiltration of lymphocytes.^[1] Abscess formation is absent at this stage.

- **Stage 2 (Purulent/Suppurative Stage):** This is the most common stage at diagnosis and is defined by the formation of a frank abscess.[1][2] Microscopically, there is a dense inflammatory infiltrate dominated by neutrophils, along with significant muscle fiber necrosis and the accumulation of pus.[1] Gram staining of the tissue at this stage can often identify the causative bacteria.
- **Stage 3 (Late Stage):** If left untreated, the infection can become systemic, leading to sepsis. [1][2] Histologically, this stage is characterized by extensive muscle destruction, widespread inflammation, and potentially, evidence of septic dissemination to other tissues.

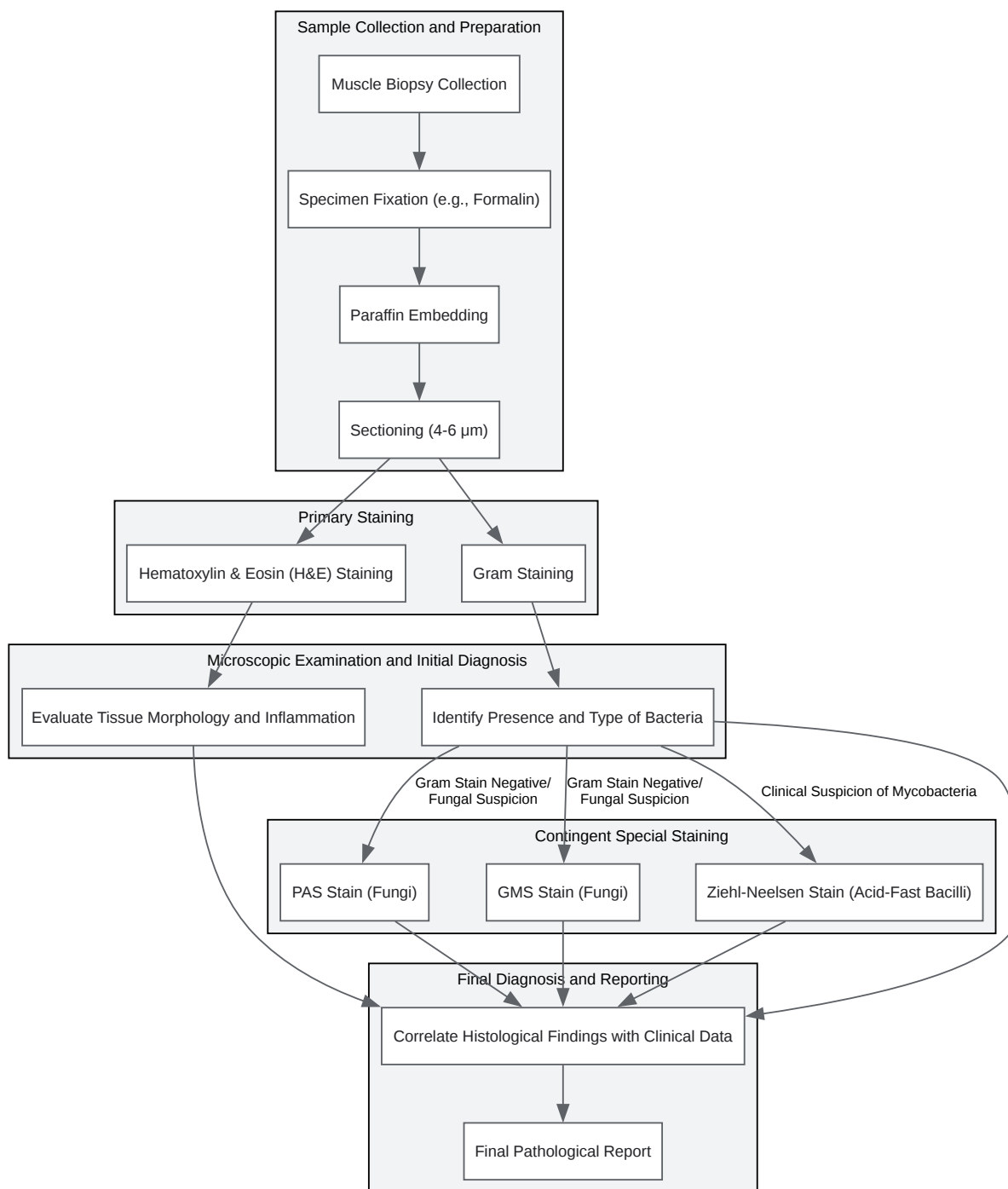
Key Staining Techniques in Pyomyositis Diagnosis

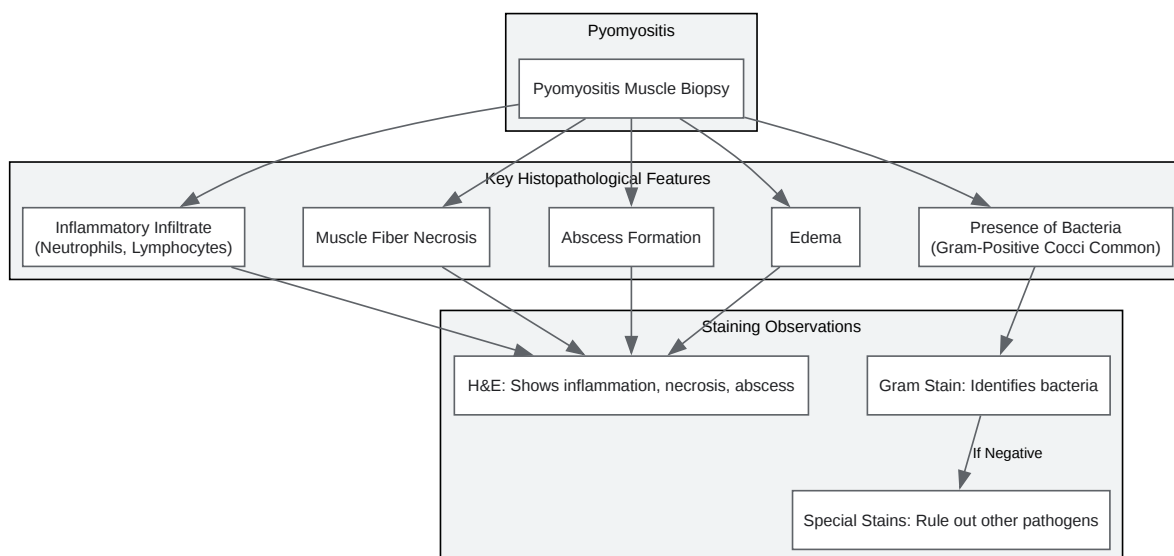
The following staining methods are fundamental in the histopathological assessment of a pyomyositis muscle biopsy:

- **Hematoxylin and Eosin (H&E) Stain:** This is the primary stain used in histology to demonstrate the overall morphology of the tissue. In pyomyositis, H&E staining reveals the inflammatory infiltrate, muscle fiber necrosis, edema, and the presence of abscesses.[3]
- **Gram Stain:** This differential stain is crucial for identifying and broadly classifying bacteria within the tissue section. It distinguishes between Gram-positive (blue/purple) and Gram-negative (red/pink) bacteria, guiding initial antibiotic therapy.[4]
- **Special Stains for Other Pathogens:** In cases where the initial Gram stain is negative or if there is a clinical suspicion of a non-bacterial cause, special stains are employed:
 - **Periodic Acid-Schiff (PAS) Stain:** Useful for detecting fungi, which have carbohydrate-rich cell walls that stain magenta.[5][6]
 - **Gomori's Methenamine Silver (GMS) Stain:** A more sensitive method for detecting fungi and certain other microorganisms, which are stained black against a green background.[7][8]
 - **Ziehl-Neelsen (Acid-Fast) Stain:** This stain is used to identify Mycobacterium species, which are not readily stained by the Gram method due to the high mycolic acid content in their cell walls.[9][10]

Experimental Workflow and Pathological Findings

The following diagrams illustrate the experimental workflow for processing and staining a pyomyositis muscle biopsy and the key histopathological findings.





[Click to download full resolution via product page](#)

Need Custom Synthesis?

BenchChem offers custom synthesis for rare earth carbides and specific isotopic labeling.

Email: info@benchchem.com or [Request Quote Online](#).

References

- 1. Pyomyositis is not only a tropical pathology: a case series - PMC [pmc.ncbi.nlm.nih.gov]
- 2. my.clevelandclinic.org [my.clevelandclinic.org]
- 3. Muscle Biopsy Evaluation | Neupsy Key [neupsykey.com]
- 4. GRAM Micro-Organisms Staining Protocol - IHC WORLD [ihcworld.com]
- 5. neuromuscular.wustl.edu [neuromuscular.wustl.edu]

- 6. microbenotes.com [microbenotes.com]
- 7. stainsfile.com [stainsfile.com]
- 8. microbenotes.com [microbenotes.com]
- 9. microbenotes.com [microbenotes.com]
- 10. Ziehl–Neelsen stain - Wikipedia [en.wikipedia.org]
- To cite this document: BenchChem. [Application Notes: Histopathological Staining of Pyomyositis Muscle Biopsy]. BenchChem, [2025]. [Online PDF]. Available at: [https://www.benchchem.com/product/b1172056#histopathological-staining-of-pyomyositis-muscle-biopsy]

Disclaimer & Data Validity:

The information provided in this document is for Research Use Only (RUO) and is strictly not intended for diagnostic or therapeutic procedures. While BenchChem strives to provide accurate protocols, we make no warranties, express or implied, regarding the fitness of this product for every specific experimental setup.

Technical Support: The protocols provided are for reference purposes. Unsure if this reagent suits your experiment? [[Contact our Ph.D. Support Team for a compatibility check](#)]

Need Industrial/Bulk Grade? [Request Custom Synthesis Quote](#)

BenchChem

Our mission is to be the trusted global source of essential and advanced chemicals, empowering scientists and researchers to drive progress in science and industry.

Contact

Address: 3281 E Guasti Rd

Ontario, CA 91761, United States

Phone: (601) 213-4426

Email: info@benchchem.com