

# An In-depth Technical Guide to Imaging Techniques for the Distal Tibia

**Author:** BenchChem Technical Support Team. **Date:** December 2025

## Compound of Interest

Compound Name: TDBIA

Cat. No.: B055026

[Get Quote](#)

For Researchers, Scientists, and Drug Development Professionals

This guide provides a comprehensive review of established and emerging imaging modalities for the assessment of the distal tibia. It is designed to offer researchers, scientists, and professionals in drug development a detailed technical understanding of these techniques, facilitating their application in preclinical and clinical research.

## Overview of Imaging Modalities

The distal tibia, a critical weight-bearing structure of the ankle joint, is susceptible to a range of pathologies, from acute fractures to chronic degenerative conditions. Accurate and detailed imaging is paramount for diagnosis, treatment planning, and the evaluation of therapeutic interventions. This guide explores the core imaging techniques: X-ray radiography, computed tomography (CT), magnetic resonance imaging (MRI), and ultrasound (US), with a focus on their technical specifications, experimental protocols, and quantitative performance.

## Data Presentation: Quantitative Comparison of Imaging Modalities

The selection of an appropriate imaging modality is contingent on the specific clinical or research question. The following tables summarize the quantitative performance of each technique for different pathologies of the distal tibia.

Pathology	Imaging Modality	Sensitivity	Specificity	Key Advantages	Limitations	Citation(s)
Distal Tibia Fractures	X-ray Radiography	Moderate	Moderate-High	Widely available, low cost, rapid acquisition.	Limited visualization of complex fracture patterns and soft tissues.	[1]
Computed Tomography (CT)	High (yield of 23% for articular fractures in distal third fractures)	High	Excellent for detailed fracture characterization and pre-operative planning.	Ionizing radiation, higher cost than X-ray.	[2][3][4]	
Syndesmotic Injury	Weight-Bearing CT (WBCT)	High (95.8% for volumetric measurement)	High (83.3% for volumetric measurement)	Allows for functional assessment of joint stability under physiological load.	Limited availability, higher radiation dose than conventional CT.	[5][6][7][8]
Soft Tissue & Ligamentous Injury	Ultrasound (US)	High (up to 90% for lateral ankle ligaments)	High	Real-time dynamic imaging, no ionizing radiation, cost-effective.	Operator-dependent, limited visualization of intra-articular structures.	[9][10][11][12][13]

Magnetic Resonance Imaging (MRI)	High	High	Superior soft tissue contrast, excellent for ligament, tendon, and cartilage assessment.	Higher cost, longer acquisition time, contraindications (e.g., pacemakers).	[14][15]
Articular Cartilage Lesions	Magnetic Resonance Imaging (MRI) (3T with 3D-DESS)	Grade I: 8.8%, Grade II: 67.9%, Grade III: 74.1%, Grade IV: 83.3%	High (99.2% - 99.8%)	Non-invasive, detailed assessment of cartilage morphology and some compositional information.	Lower sensitivity for early-stage (Grade I) lesions. [16][17][18]
Weight-Bearing CT Arthrography (WBCTa)	High (serves as a referent standard in some studies)	High	Provides imaging under load, potentially revealing lesions not seen on non-weight-bearing MRI.	Invasive (requires contrast injection), ionizing radiation.	[19]

## Experimental Protocols

Detailed and standardized experimental protocols are crucial for reproducible and comparable research outcomes. This section outlines key protocols for each imaging modality.

### X-ray Radiography for Distal Tibia Fractures

- Standard Views:
  - Anteroposterior (AP)
  - Lateral
  - Mortise (AP with 15-20 degrees of internal rotation)
- Procedure:
  - Position the patient supine on the imaging table.
  - For the AP view, ensure the foot is in a neutral position with the ankle at 90 degrees.
  - For the lateral view, the patient should be turned onto the affected side with the knee slightly flexed.
  - For the mortise view, internally rotate the entire leg and foot approximately 15-20 degrees to bring the intermalleolar plane parallel to the detector.
  - The X-ray beam should be centered on the ankle joint.
- Exposure Parameters:
  - kVp: 60-70
  - mAs: 3-5 (will vary based on patient size and equipment)

### Computed Tomography (CT) for Pilon Fractures

- Patient Positioning: Supine, feet first.

- Scan Range: From the tibial tuberosity to the plantar aspect of the foot.
- Acquisition:
  - Helical acquisition with thin slices ( $\leq 1.0$  mm).
  - Tube voltage: 120 kVp
  - Tube current: Automated dose modulation or a fixed mAs of 150-250.
- Reconstruction:
  - Reconstruct with a bone algorithm.
  - Generate multiplanar reformats (MPR) in the sagittal, coronal, and axial planes.
  - 3D volumetric reconstructions are highly recommended for preoperative planning.[\[2\]](#)[\[20\]](#)

## Magnetic Resonance Imaging (MRI) of the Ankle at 3T

- Patient Positioning: Supine, feet first, with the ankle in a dedicated ankle coil at a 90-degree angle.
- Standard Sequences:
  - Sagittal T1-weighted or Proton Density (PD)-weighted: Provides excellent anatomical detail.
  - Sagittal T2-weighted with fat saturation or STIR: Sensitive for detecting fluid and edema.
  - Axial PD-weighted with and without fat saturation: Useful for assessing tendons and ligaments in cross-section.
  - Coronal PD-weighted with fat saturation: Provides a comprehensive view of the articular surfaces and collateral ligaments.
- Advanced Sequences for Cartilage Assessment:

- 3D Double-Echo Steady-State (3D-DESS): High-resolution imaging for detailed morphological assessment of articular cartilage.[17]
- T2 Mapping: Quantitative assessment of cartilage matrix composition.
- Typical Parameters (3T):
  - Slice thickness: 2-3 mm
  - Field of View (FOV): 14-16 cm
  - Matrix: 256 x 256 or higher
  - Specific TR/TE will vary depending on the sequence and scanner manufacturer.[15][21][22][23]

## Ultrasound (US) for Soft Tissue and Ligamentous Injury

- Transducer: High-frequency linear array transducer (10-18 MHz).
- Patient Positioning:
  - Anterior Talofibular Ligament (ATFL): Patient supine with the foot in slight plantar flexion and internal rotation.
  - Calcaneofibular Ligament (CFL): Patient supine with the foot in dorsiflexion.
  - Posterior Talofibular Ligament (PTFL): Patient prone with the foot hanging off the edge of the examination table.
  - Syndesmosis: Patient supine with the foot in a neutral position. Dynamic assessment with external rotation stress can be performed.
- Imaging Protocol:
  - Begin with a survey scan in both the longitudinal and transverse planes.
  - Perform a systematic evaluation of all relevant ligaments and tendons.

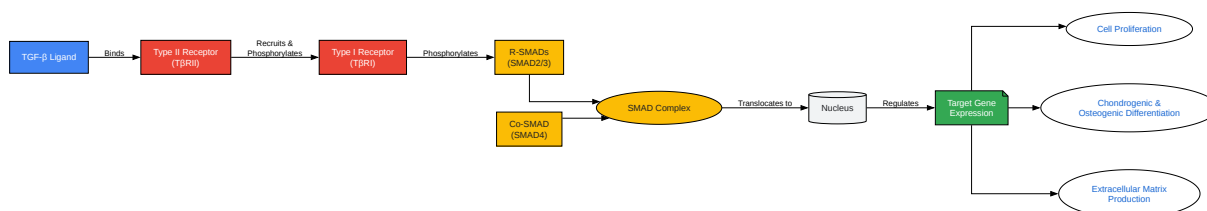
- Dynamic imaging with passive or active range of motion can be used to assess for ligamentous instability and tendon subluxation.
- Compare with the contralateral, asymptomatic side.

## Visualization of Signaling Pathways and Experimental Workflows

The following diagrams, generated using the DOT language, illustrate key biological pathways involved in distal tibia pathology and standardized workflows for imaging-based research.

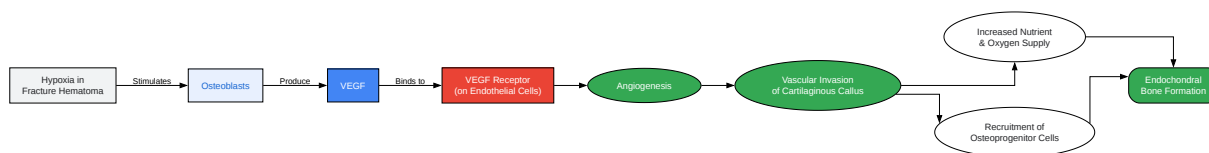
### Signaling Pathways in Bone Fracture Healing

The healing of a distal tibial fracture is a complex biological process involving a cascade of signaling molecules. Two of the most critical pathways are the Transforming Growth Factor-beta (TGF- $\beta$ ) and Vascular Endothelial Growth Factor (VEGF) signaling pathways.



[Click to download full resolution via product page](#)

Caption: TGF- $\beta$  signaling pathway in fracture healing.[24][25][26][27][28][29]



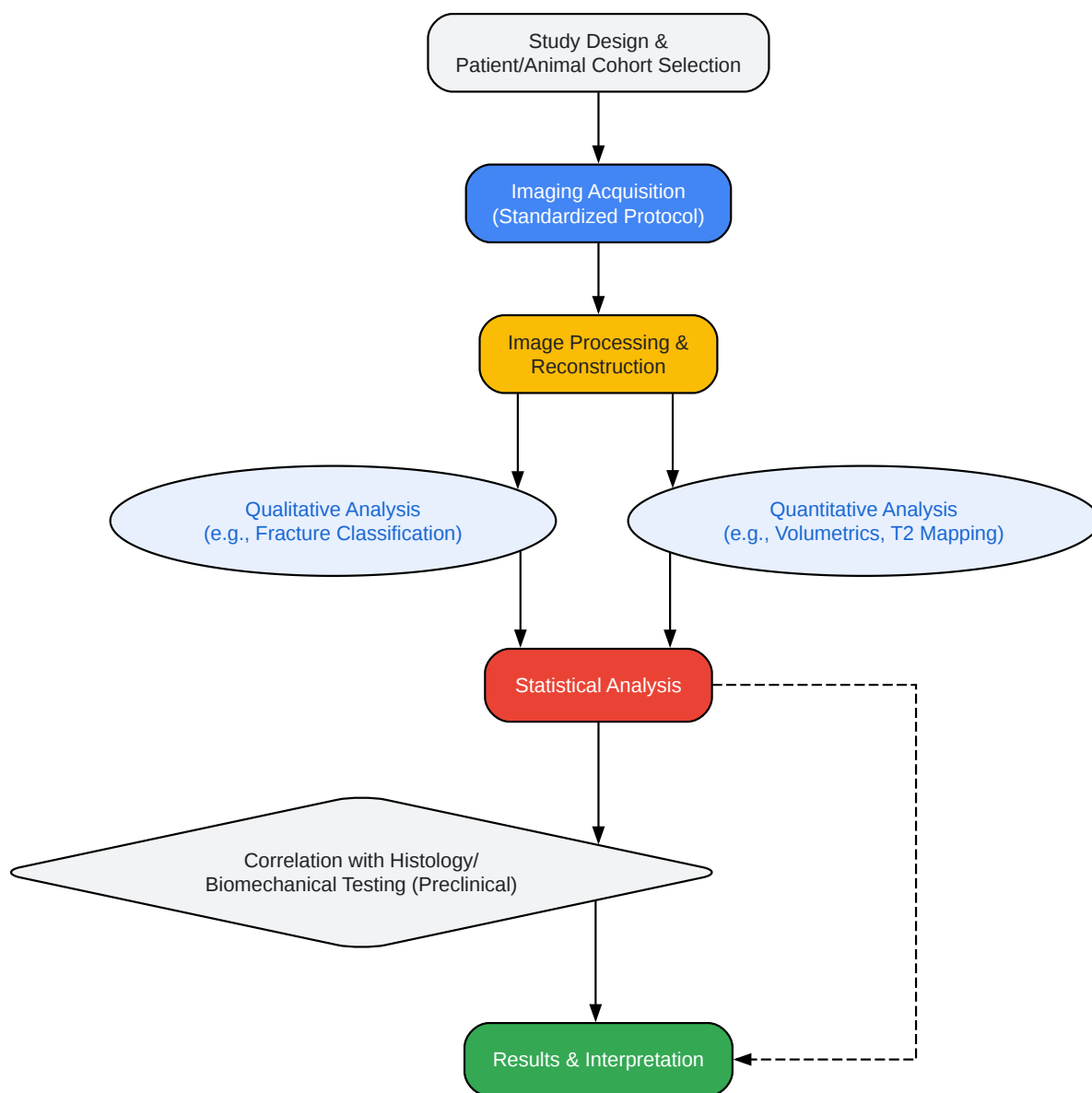
[Click to download full resolution via product page](#)

Caption: VEGF signaling pathway in fracture healing.[30][31][32][33][34]

## Experimental Workflow for Imaging-Based Assessment

A standardized workflow is essential for conducting rigorous imaging-based research on the distal tibia. The following diagram outlines a typical experimental workflow.





[Click to download full resolution via product page](#)

Caption: A standardized experimental workflow for imaging-based research of the distal tibia.

**Need Custom Synthesis?**

BenchChem offers custom synthesis for rare earth carbides and specific isotopic labeling.

Email: [info@benchchem.com](mailto:info@benchchem.com) or [Request Quote Online](#).

## References

- 1. Diagnosis of union of distal tibia fractures: accuracy and interobserver reliability - PubMed [pubmed.ncbi.nlm.nih.gov]
- 2. researchgate.net [researchgate.net]
- 3. Diagnosing Fractures of the Distal Tibial Articular Surface in Tibia Shaft Fractures: Is Computed Tomography Always Necessary? - PubMed [pubmed.ncbi.nlm.nih.gov]
- 4. researchgate.net [researchgate.net]
- 5. Volume Measurements on Weightbearing Computed Tomography Can Detect Subtle Syndesmotic Instability - PMC [pmc.ncbi.nlm.nih.gov]
- 6. Weight-bearing CT Useful for Diagnosis of Subtle Syndesmotic Instability - Mass General Advances in Motion [advances.massgeneral.org]
- 7. Diagnostic Accuracy of Weightbearing CT in Detecting Subtle Chronic Syndesmotic Instability: A Prospective Comparative Study - PMC [pmc.ncbi.nlm.nih.gov]
- 8. Can Weightbearing Cone-beam CT Reliably Differentiate Between Stable and Unstable Syndesmotic Ankle Injuries? A Systematic Review and Meta-analysis - PMC [pmc.ncbi.nlm.nih.gov]
- 9. The accuracy of diagnostic ultrasound imaging for musculoskeletal soft tissue pathology of the extremities: a comprehensive review of the literature - PMC [pmc.ncbi.nlm.nih.gov]
- 10. Ultrasound imaging in musculoskeletal injuries-What the Orthopaedic surgeon needs to know - PMC [pmc.ncbi.nlm.nih.gov]
- 11. How Accurate Is Ultrasound for Diagnosing Soft Tissue Injuries? [ultrasoundphysio.ie]
- 12. What Are the Benefits of Using Ultrasound for Diagnosing Soft Tissue Injuries? | Our Blog [glmi.com]
- 13. Research Portal [researchportal.murdoch.edu.au]
- 14. The value of magnetic resonance imaging in the preoperative diagnosis of tibial plateau fractures: a systematic literature review - PMC [pmc.ncbi.nlm.nih.gov]
- 15. ajronline.org [ajronline.org]

- 16. [mdpi.com](https://mdpi.com) [[mdpi.com](https://mdpi.com)]
- 17. Accuracy of cartilage-specific 3-Tesla 3D-DESS magnetic resonance imaging in the diagnosis of chondral lesions: comparison with knee arthroscopy - PMC [[pubmed.ncbi.nlm.nih.gov](https://pubmed.ncbi.nlm.nih.gov)]
- 18. [radiopaedia.org](https://radiopaedia.org) [[radiopaedia.org](https://radiopaedia.org)]
- 19. Diagnostic value of MRI for detection of knee cartilage lesions vs. weight-bearing CT arthrography (WBCTa) - PubMed [[pubmed.ncbi.nlm.nih.gov](https://pubmed.ncbi.nlm.nih.gov)]
- 20. [ota.org](https://ota.org) [[ota.org](https://ota.org)]
- 21. MR imaging of the ankle at 3 Tesla and 1.5 Tesla: protocol optimization and application to cartilage, ligament and tendon pathology in cadaver specimens - PubMed [[pubmed.ncbi.nlm.nih.gov](https://pubmed.ncbi.nlm.nih.gov)]
- 22. [mrmaster.com](https://mrmaster.com) [[mrmaster.com](https://mrmaster.com)]
- 23. [researchgate.net](https://researchgate.net) [[researchgate.net](https://researchgate.net)]
- 24. Molecular signaling in bone fracture healing and distraction osteogenesis. | Semantic Scholar [[semanticscholar.org](https://semanticscholar.org)]
- 25. [journals.biologists.com](https://journals.biologists.com) [[journals.biologists.com](https://journals.biologists.com)]
- 26. TGF- $\beta$ /Smad2 signalling regulates enchondral bone formation of Gli1+ periosteal cells during fracture healing - PMC [[pubmed.ncbi.nlm.nih.gov](https://pubmed.ncbi.nlm.nih.gov)]
- 27. Transforming Growth Factor Beta Family: Insight into the Role of Growth Factors in Regulation of Fracture Healing Biology and Potential Clinical Applications - PMC [[pubmed.ncbi.nlm.nih.gov](https://pubmed.ncbi.nlm.nih.gov)]
- 28. [academic.oup.com](https://academic.oup.com) [[academic.oup.com](https://academic.oup.com)]
- 29. Imaging transforming growth factor-beta signaling dynamics and therapeutic response in breast cancer bone metastasis - PubMed [[pubmed.ncbi.nlm.nih.gov](https://pubmed.ncbi.nlm.nih.gov)]
- 30. Angiogenesis in Bone Regeneration - PMC [[pubmed.ncbi.nlm.nih.gov](https://pubmed.ncbi.nlm.nih.gov)]
- 31. The roles of vascular endothelial growth factor in bone repair and regeneration - PMC [[pubmed.ncbi.nlm.nih.gov](https://pubmed.ncbi.nlm.nih.gov)]
- 32. JCI - Osteoblast-derived VEGF regulates osteoblast differentiation and bone formation during bone repair [[jci.org](https://jci.org)]
- 33. JCI - Synergistic enhancement of bone formation and healing by stem cell-expressed VEGF and bone morphogenetic protein-4 [[jci.org](https://jci.org)]
- 34. Synergistic Effects of Vascular Endothelial Growth Factor on Bone Morphogenetic Proteins Induced Bone Formation In Vivo: Influencing Factors and Future Research

Directions - PMC [pmc.ncbi.nlm.nih.gov]

- To cite this document: BenchChem. [An In-depth Technical Guide to Imaging Techniques for the Distal Tibia]. BenchChem, [2025]. [Online PDF]. Available at: [https://www.benchchem.com/product/b055026#review-of-imaging-techniques-for-the-distal-tibia]

---

### Disclaimer & Data Validity:

The information provided in this document is for Research Use Only (RUO) and is strictly not intended for diagnostic or therapeutic procedures. While BenchChem strives to provide accurate protocols, we make no warranties, express or implied, regarding the fitness of this product for every specific experimental setup.

**Technical Support:** The protocols provided are for reference purposes. Unsure if this reagent suits your experiment? [[Contact our Ph.D. Support Team for a compatibility check](#)]

**Need Industrial/Bulk Grade?** [Request Custom Synthesis Quote](#)

## BenchChem

Our mission is to be the trusted global source of essential and advanced chemicals, empowering scientists and researchers to drive progress in science and industry.

### Contact

Address: 3281 E Guasti Rd  
Ontario, CA 91761, United States  
Phone: (601) 213-4426  
Email: [info@benchchem.com](mailto:info@benchchem.com)