

An In-depth Technical Guide to Idiopathic Bilateral Vocal Fold Paralysis in Adults

Author: BenchChem Technical Support Team. **Date:** December 2025

Compound of Interest

Compound Name: BVFP

Cat. No.: B5387700

[Get Quote](#)

For Researchers, Scientists, and Drug Development Professionals

Introduction

Bilateral vocal fold paralysis (**BVFP**) is a clinical condition characterized by the immobility of both vocal folds, typically resulting from neurologic dysfunction of the vagus or recurrent laryngeal nerves. This condition can lead to significant airway compromise, presenting as inspiratory stridor and dyspnea, while often preserving a near-normal voice due to the paramedian position of the paralyzed vocal folds. While numerous etiologies for **BVFP** have been identified—ranging from surgical trauma to malignancy and neurological diseases—a significant subset of cases remains classified as idiopathic, meaning a definitive cause cannot be identified despite a thorough diagnostic workup.

This technical guide provides a comprehensive overview of the current understanding of idiopathic **BVFP** in adults. It is designed to serve as a resource for researchers, scientists, and drug development professionals by consolidating etiological data, detailing diagnostic protocols, and visualizing the logical and pathophysiological frameworks associated with this challenging condition. Understanding the diagnostic process of exclusion and the leading hypotheses for its underlying cause is critical for advancing research and developing targeted therapeutic strategies.

Etiology and Demographics of Bilateral Vocal Fold Paralysis

An idiopathic diagnosis is one of exclusion, made only after a comprehensive evaluation fails to identify a specific cause. Surgical trauma, particularly thyroid surgery, is the most common iatrogenic cause of **BVFP**.^[1] Other significant causes include malignancy, endotracheal intubation, and various neurological disorders. The proportion of cases classified as idiopathic varies across studies but represents a crucial area of investigation.

Data Presentation

The following tables summarize the etiological distribution of **BVFP** from cohort studies. It is important to note that detailed demographic data specifically for the adult idiopathic **BVFP** sub-population is not extensively detailed in large-scale studies, representing a gap in the current literature.

Table 1: Etiological Distribution of Bilateral Vocal Fold Immobility/Paralysis in Adults

Etiology	Percentage of Cases (Benninger et al., Series of 117 cases)	Notes
Surgical Trauma	44%	Includes thyroid/parathyroid, esophageal, and cervical spine surgery.
Malignancies	17%	Tumors of the larynx, thyroid, esophagus, or CNS impacting the vagus/RLN.
Endotracheal Intubation	15%	Trauma to the recurrent laryngeal nerves from compression.
Neurologic Disease	12%	Includes stroke, CNS tumors, and other neuromuscular disorders.
Idiopathic	12%	No identifiable cause after comprehensive workup.

Source: Data adapted from Benninger et al., as cited in medical reference materials.

Table 2: Etiology from a Systematic Review of **BVFP** in Adults

Etiology Category	Finding
Iatrogenic (Surgical)	The majority of BVFP cases (76.6%) are iatrogenic.
Requirement for Tracheotomy	36.2% of BVFP cases require immediate tracheotomy.

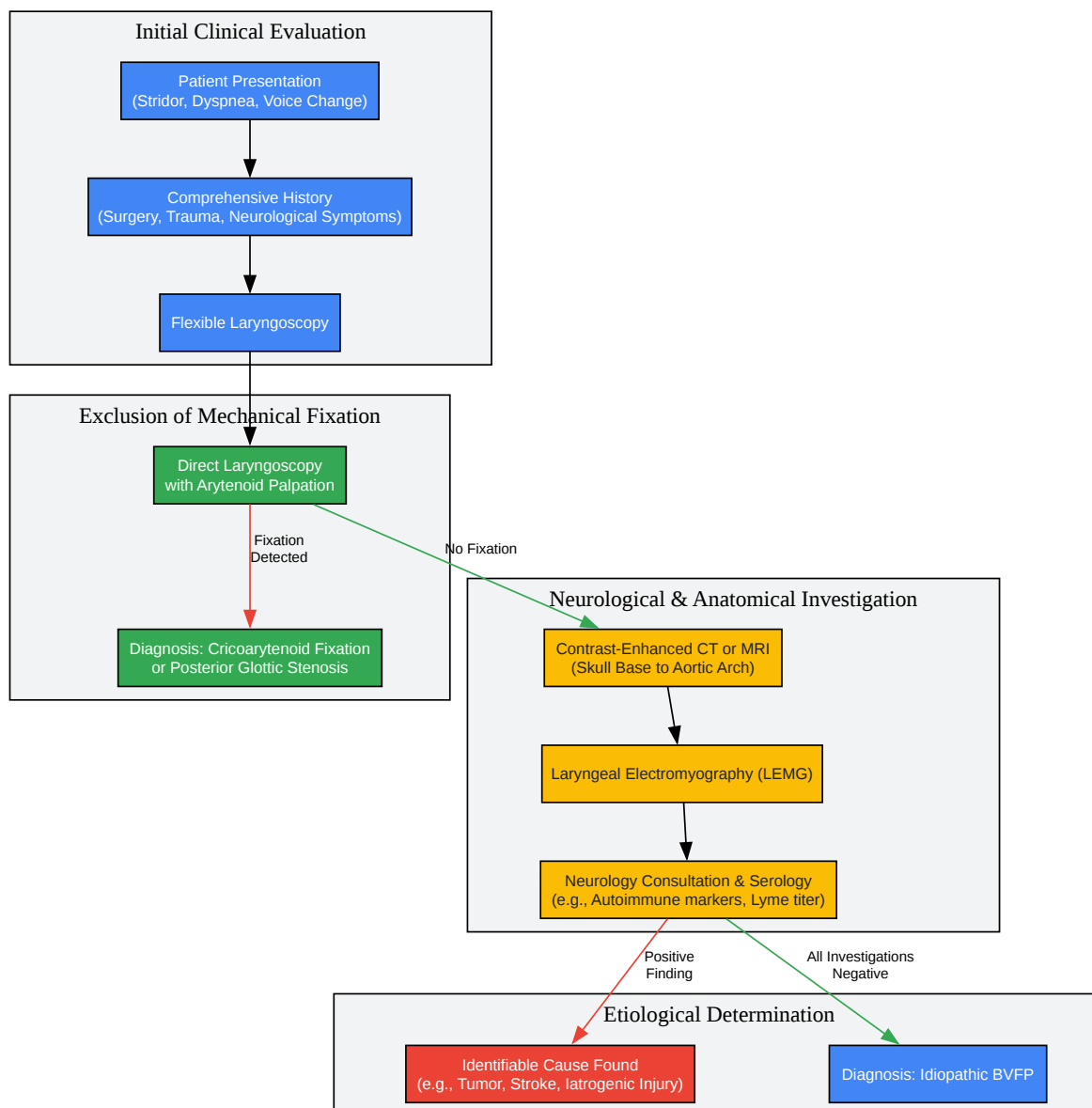
Source: Data from a 2023 systematic review on the management of bilateral vocal fold paralysis.

Diagnostic Workflow and Experimental Protocols

The diagnosis of idiopathic **BVFP** is contingent on a rigorous and systematic process of exclusion. The primary goal is to rule out all potential mechanical and neurological causes of bilateral vocal fold immobility.

Diagnostic Workflow Diagram

The following diagram illustrates the typical workflow for a patient presenting with symptoms suggestive of **BVFP**, leading to a diagnosis of idiopathic paralysis.



[Click to download full resolution via product page](#)

Diagnostic workflow for bilateral vocal fold paralysis.

Key Experimental Protocols

1. Contrast-Enhanced Computed Tomography (CT) of the Recurrent Laryngeal Nerve Pathway

- Objective: To visualize the entire course of the vagus and recurrent laryngeal nerves (RLN) to rule out anatomical abnormalities, compression, or invasion by neoplastic, vascular, or inflammatory lesions.
- Methodology:
 - Patient Preparation: No specific preparation is typically required unless sedation is necessary. Intravenous access is established for contrast administration.
 - Imaging Range: The scan must cover the entire path of the vagus and recurrent laryngeal nerves. This extends from the skull base (including the posterior fossa) down to the aortic arch in the superior mediastinum.[2] For the right RLN, imaging to the level of the clavicle is essential.
 - Contrast Administration: A bolus of iodinated contrast medium is injected intravenously. Imaging is timed to capture the arterial or venous phase, enhancing the visibility of vascular structures and lesions.
 - Acquisition Parameters: Thin axial slices (e.g., 0.625-1.25 mm) are acquired using a multidetector CT (MDCT) scanner. These thin slices allow for high-resolution multiplanar reformations (coronal and sagittal).
 - Image Analysis: Radiologists scrutinize the images for any pathology along the nerve pathways, including tumors (e.g., thyroid, esophageal, lung), lymphadenopathy, aortic aneurysms, and signs of central neurological events like stroke. Specific laryngeal signs of paralysis, such as pyriform sinus dilatation and medialization of the aryepiglottic fold, are also assessed.[3]

2. Laryngeal Electromyography (LEMG)

- Objective: To assess the integrity and function of the laryngeal nerves and muscles, differentiate between neurogenic paralysis and mechanical fixation, and provide prognostic information about the potential for nerve recovery.
- Methodology:

- Patient Preparation: The procedure is typically performed with the patient awake and in a seated or supine position. Local anesthesia may be used at the needle insertion sites.
- Electrode Placement: A monopolar needle electrode is most commonly used.[4] The needle is inserted percutaneously into the target laryngeal muscles under guidance (sometimes with ultrasound or flexible laryngoscopy).
 - Thyroarytenoid (TA) Muscle: To assess the integrity of the RLN, the needle is inserted through the cricothyroid membrane.
 - Cricothyroid (CT) Muscle: To assess the superior laryngeal nerve (SLN), the needle is inserted more superficially in the neck into the CT muscle.
 - Posterior Cricoarytenoid (PCA) Muscle: This is the sole vocal fold abductor, also innervated by the RLN. It is approached percutaneously by rotating the larynx.
- Data Acquisition: Electrical activity is recorded at three stages:
 - Insertional Activity: A brief burst of activity upon needle insertion.
 - Resting Activity: The muscle should be electrically silent at rest. The presence of abnormal spontaneous activity, such as fibrillation potentials or positive sharp waves, indicates denervation.
 - Voluntary Contraction: The patient is asked to perform specific tasks to activate the target muscles. For the TA muscle (adductor), the patient phonates (e.g., says "eee").[4] For the PCA muscle (abductor), the patient sniffs or takes a deep breath.[4] The recruitment pattern of motor unit potentials (MUPs) is analyzed.
- Interpretation: Findings consistent with neurogenic paralysis include abnormal spontaneous activity at rest and reduced MUP recruitment during voluntary tasks. A normal EMG signal in an immobile vocal fold suggests mechanical fixation (e.g., cricoarytenoid joint ankylosis).

Hypothesized Pathophysiological Mechanisms in Idiopathic BVFP

In the absence of an identifiable cause, research focuses on potential viral or autoimmune mechanisms leading to a cranial mononeuropathy or polyneuropathy affecting the vagus nerves.

Post-Viral Neuropathy

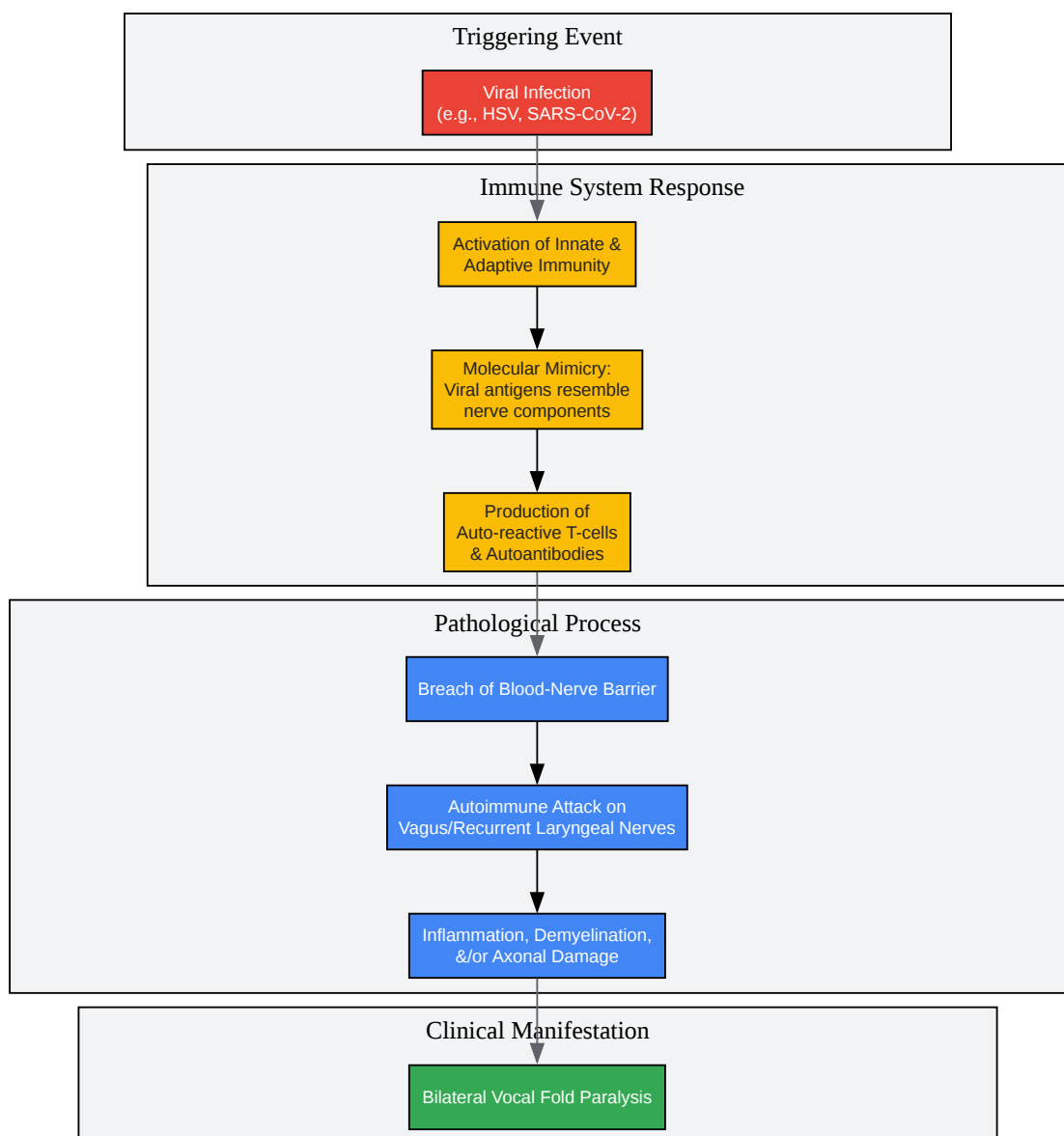
One of the leading theories suggests that a viral infection may trigger inflammation of the vagus or recurrent laryngeal nerves, leading to demyelination or axonal damage.[5] This is analogous to Bell's palsy affecting the facial nerve. Viruses such as Herpes Simplex Virus (HSV) and, more recently, SARS-CoV-2 have been implicated in cases of otherwise idiopathic vocal fold paralysis. The proposed mechanism involves direct viral invasion of the nerve or a post-viral inflammatory response.

Autoimmune Mechanisms

Autoimmune diseases can cause a wide range of neurological symptoms, and it is hypothesized that some idiopathic **BVFP** cases may represent an autoimmune or inflammatory neuropathy.[5] This could involve the production of autoantibodies that target components of the peripheral nerve sheath or axon, leading to nerve dysfunction. A history of other autoimmune conditions may be a clue, and serological testing for autoimmune markers is a component of the diagnostic workup.

Hypothesized Pathophysiological Pathway Diagram

The following diagram illustrates a conceptual model for a post-viral autoimmune etiology of **BVFP**.



[Click to download full resolution via product page](#)

Hypothesized post-viral autoimmune pathway in idiopathic **BVFP**.

Conclusion and Future Directions

Idiopathic bilateral vocal fold paralysis remains a significant clinical challenge, defined by what it is not rather than what it is. The diagnosis relies on a meticulous and comprehensive exclusion of known causes, with advanced imaging and laryngeal electromyography serving as cornerstone diagnostic tools.

For researchers and drug development professionals, the idiopathic nature of this condition presents a unique opportunity. Future research should focus on:

- Large-scale epidemiological studies to better define the demographics and true incidence of idiopathic **BVFP**.
- Advanced serological and genetic screening of patients with idiopathic **BVFP** to identify novel biomarkers, autoantibodies, or genetic predispositions.
- Development of animal models that replicate post-viral or autoimmune laryngeal neuropathy to test novel therapeutic agents.
- Investigation of neuro-immunomodulatory therapies, such as targeted anti-inflammatory agents or intravenous immunoglobulin (IVIg), in well-defined clinical trials for patients with suspected autoimmune-mediated **BVFP**.

By elucidating the underlying molecular mechanisms, the scientific community can move beyond a diagnosis of exclusion and toward the development of targeted, mechanism-based treatments for patients affected by idiopathic bilateral vocal fold paralysis.

Need Custom Synthesis?

BenchChem offers custom synthesis for rare earth carbides and specific isotopic labeling.

Email: info@benchchem.com or [Request Quote Online](#).

References

- 1. profiles.wustl.edu [profiles.wustl.edu]
- 2. mdpi.com [mdpi.com]
- 3. Outcomes in Bilateral Vocal Fold Immobility: A Retrospective Cohort Analysis - PMC [pmc.ncbi.nlm.nih.gov]

- 4. researchgate.net [researchgate.net]
- 5. ovid.com [ovid.com]
- To cite this document: BenchChem. [An In-depth Technical Guide to Idiopathic Bilateral Vocal Fold Paralysis in Adults]. BenchChem, [2025]. [Online PDF]. Available at: [https://www.benchchem.com/product/b5387700#idiopathic-causes-of-bilateral-vocal-fold-paralysis-in-adults]

Disclaimer & Data Validity:

The information provided in this document is for Research Use Only (RUO) and is strictly not intended for diagnostic or therapeutic procedures. While BenchChem strives to provide accurate protocols, we make no warranties, express or implied, regarding the fitness of this product for every specific experimental setup.

Technical Support: The protocols provided are for reference purposes. Unsure if this reagent suits your experiment? [[Contact our Ph.D. Support Team for a compatibility check](#)]

Need Industrial/Bulk Grade? [Request Custom Synthesis Quote](#)

BenchChem

Our mission is to be the trusted global source of essential and advanced chemicals, empowering scientists and researchers to drive progress in science and industry.

Contact

Address: 3281 E Guasti Rd
Ontario, CA 91761, United States
Phone: (601) 213-4426
Email: info@benchchem.com