

Adosterol Uptake vs. Histopathology in Adrenal Tumors: A Comparative Guide

Author: BenchChem Technical Support Team. **Date:** December 2025

Compound of Interest

Compound Name: Adosterol

Cat. No.: B1220196

[Get Quote](#)

For Researchers, Scientists, and Drug Development Professionals

The accurate differentiation of benign from malignant adrenal tumors is a critical diagnostic challenge. While anatomical imaging techniques like CT and MRI provide valuable morphological information, functional imaging with radiotracers such as **Adosterol** (^{131}I -6 β -iodomethyl-19-norcholesterol) offers insights into the metabolic activity of these lesions. This guide provides a comprehensive comparison of **Adosterol** uptake with the histopathological characteristics of adrenal tumors, supported by experimental data and detailed methodologies.

Correlation of Adrenal Tumor Characteristics

The following table summarizes the key distinctions in **Adosterol** uptake and histopathological features between the most common types of adrenal cortical tumors.

Feature	Adrenocortical Adenoma	Adrenocortical Carcinoma
Adosterol Uptake	Typically high uptake, especially in functioning adenomas.[1][2]	Generally no significant uptake.[3] Uncommonly, well-differentiated carcinomas may show some uptake.[3][4]
Histopathology (Weiss Score)	Weiss score typically ≤ 2 .[5]	Weiss score ≥ 3 is indicative of malignancy.[6][7][8]
Key Histological Features	Well-circumscribed, encapsulated, cells with bland nuclei and abundant clear or pink cytoplasm.[7]	Infiltrative growth, fibrous bands, necrosis, cellular atypia, and atypical mitotic figures.[7]
Hormonal Activity	Can be functioning (e.g., producing cortisol or aldosterone) or non-functioning.[1]	Can be functioning or non-functioning.[3]

Quantitative Comparison of Adosterol Uptake

Precise quantitative data directly comparing **Adosterol** uptake in adenomas versus carcinomas is limited in the literature. However, studies using the closely related agent ^{131}I -norcholesterol provide valuable insights. A semi-quantitative scoring of uptake has been shown to differentiate between hypersecreting and non-hypersecreting adenomas.

Tumor Type	^{131}I -norcholesterol Uptake (Semi-quantitative score)
Hypersecreting Adenoma	Significantly higher uptake.[1]
Non-hypersecreting Adenoma	Lower uptake compared to hypersecreting adenomas.[1]

Note: While specific standardized uptake values (SUVs) for **Adosterol** are not widely reported, the principle remains that benign, functioning adrenal tissue and adenomas actively take up this cholesterol analog, whereas most carcinomas do not.

Alternative Imaging Modalities

Several other imaging techniques are used to characterize adrenal masses, each with its own strengths and weaknesses.

Imaging Modality	Performance in Differentiating Benign vs. Malignant
Unenhanced CT	Attenuation value ≤ 10 Hounsfield Units (HU) is highly specific for benign (lipid-rich) adenomas. [9]
Contrast-Enhanced CT (Washout)	Absolute and relative washout percentages can help differentiate adenomas from malignant lesions. [10]
MRI (Chemical Shift)	High sensitivity and specificity for identifying lipid-rich adenomas based on signal loss on opposed-phase images. [11]
^{18}F -FDG PET/CT	Malignant lesions typically show higher glucose metabolism (higher FDG uptake) compared to benign adenomas. [12] [13]
^{123}I -MIBG Scintigraphy	Specific for pheochromocytomas, which are neuroendocrine tumors of the adrenal medulla. [14]

Experimental Protocols

Adosterol (^{131}I -6 β -iodomethyl-19-norcholesterol) Scintigraphy

A standardized protocol is crucial for accurate and reproducible results.

1. Patient Preparation:

- **Thyroid Blockade:** To prevent uptake of free ^{131}I by the thyroid gland, patients are administered a saturated solution of potassium iodide (SSKI) or Lugol's solution, starting one

day before the tracer injection and continuing for 5-10 days.[15][16][17]

- Medication Review: Certain medications that can interfere with **Adosterol** uptake, such as corticosteroids, diuretics, and oral contraceptives, should be discontinued at least 48 hours prior to the investigation.[15][16]
- Dexamethasone Suppression (for aldosteronomas and androgen-producing tumors): To suppress ACTH and visualize autonomous adrenal function, dexamethasone is administered for several days before and during the imaging period.[18]

2. Radiopharmaceutical Administration:

- A sterile, pyrogen-free solution of ^{131}I -**Adosterol** is administered intravenously. The typical adult dose is approximately 20 MBq (0.54 mCi).[16]

3. Imaging Acquisition:

- Planar Imaging: Anterior and posterior static images of the adrenal region are acquired using a gamma camera equipped with a high-energy collimator.
- Imaging Schedule: Images are typically acquired on days 3, 5, and sometimes later (e.g., day 8) after tracer injection to allow for clearance of background activity and optimal visualization of adrenal uptake.[15][18]
- SPECT/CT (Optional): Single Photon Emission Computed Tomography (SPECT), often combined with a low-dose CT for anatomical localization, can improve the accuracy of lesion detection and characterization.[16]

4. Image Interpretation:

- Qualitative Analysis: The distribution of tracer uptake is assessed. Normal adrenal glands show symmetric uptake. Asymmetric or focal uptake is suggestive of a unilateral adenoma, while bilateral increased uptake may indicate hyperplasia.[16]
- Semi-quantitative Analysis: Uptake in the adrenal glands can be compared to background activity (e.g., liver or kidney) to provide a semi-quantitative measure of function.

Histopathological Evaluation of Adrenal Tumors

The definitive diagnosis of an adrenal tumor is made through histopathological examination of the surgically removed specimen.

1. Gross Examination:

- The specimen is weighed and measured.
- The external surface is examined for capsular integrity and evidence of invasion into surrounding tissues.
- The tumor is sectioned to assess its color, consistency, and the presence of hemorrhage or necrosis.

2. Microscopic Examination:

- Tissue sections are stained with Hematoxylin and Eosin (H&E).
- The Weiss scoring system is a widely used method to differentiate between adrenocortical adenomas and carcinomas. A score of 3 or more is highly suggestive of malignancy.[\[6\]](#)[\[8\]](#)[\[19\]](#)

Weiss Score Criteria:[\[6\]](#)[\[7\]](#)

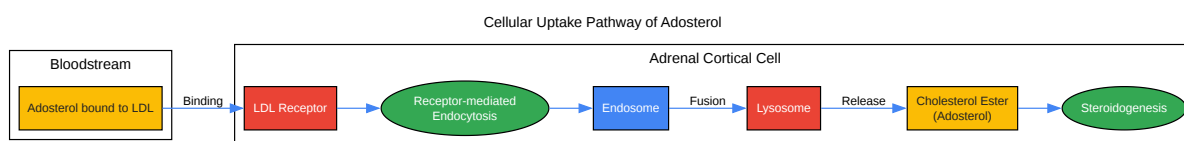
- High nuclear grade
- Mitotic rate >5 per 50 high-power fields
- Atypical mitoses
- Eosinophilic tumor cell cytoplasm (in >75% of cells)
- Diffuse architecture (in >33% of the tumor)
- Necrosis
- Venous invasion
- Sinusoidal invasion

- Capsular invasion

3. Immunohistochemistry:

- Immunohistochemical staining can aid in the differential diagnosis.
- SF-1 (Steroidogenic Factor 1): A marker for adrenocortical origin.
- Ki-67 (MIB-1): A proliferation marker. A high Ki-67 index (>5%) is more common in carcinomas.[5][7]
- Markers to exclude other tumor types: Chromogranin and synaptophysin (for neuroendocrine tumors like pheochromocytoma) and cytokeratins (for metastatic carcinoma).[20]

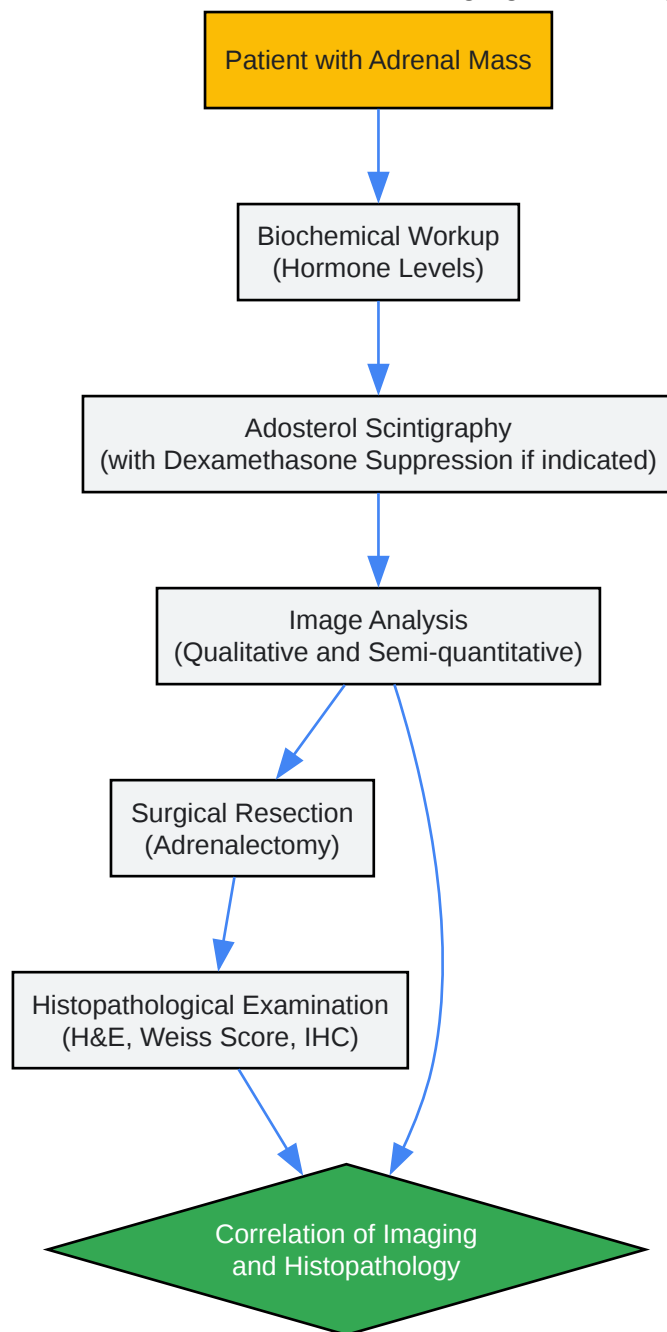
Visualizing the Pathways and Processes



[Click to download full resolution via product page](#)

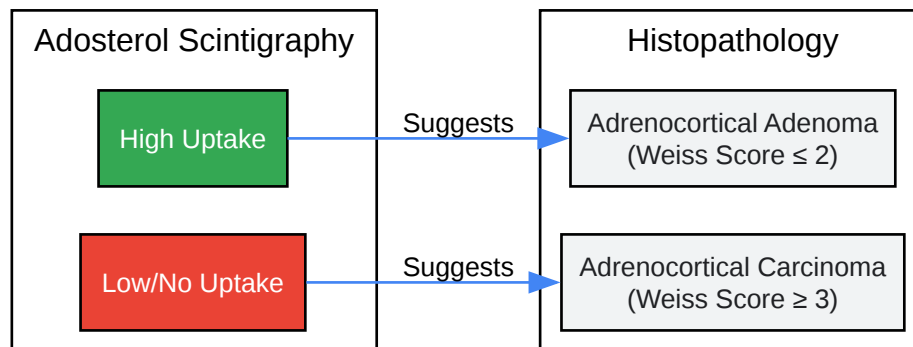
Caption: **Adosterol**, a cholesterol analog, is taken up by adrenal cortical cells via the LDL receptor pathway.

Experimental Workflow for Adosterol Imaging and Histopathology

[Click to download full resolution via product page](#)

Caption: A typical workflow for the evaluation of adrenal tumors using **Adosterol** imaging and histopathology.

Adosterol Uptake and Histopathology Correlation

[Click to download full resolution via product page](#)**Need Custom Synthesis?**

BenchChem offers custom synthesis for rare earth carbides and specific isotopic labeling.

Email: info@benchchem.com or [Request Quote Online](#).

References

- 1. Quantitative imaging characterization of hypersecreting or nonhypersecreting adrenal adenomas: comparison between iodine-131 norcholesterol uptake and magnetic resonance signal intensity ratios - PubMed [pubmed.ncbi.nlm.nih.gov]
- 2. researchgate.net [researchgate.net]
- 3. erc.bioscientifica.com [erc.bioscientifica.com]
- 4. Unusual visualization of an adrenal carcinoma on NP-59 scintiscan - PubMed [pubmed.ncbi.nlm.nih.gov]
- 5. Distinguishing adrenal cortical carcinomas and adenomas: a study of clinicopathological features and biomarkers - PMC [pmc.ncbi.nlm.nih.gov]
- 6. The Weiss Score and Beyond—Histopathology for Adrenocortical Carcinoma - PMC [pmc.ncbi.nlm.nih.gov]
- 7. Adrenocortical carcinoma - Libre Pathology [librepathology.org]
- 8. researchgate.net [researchgate.net]
- 9. bmc.org [bmc.org]

- 10. researchgate.net [researchgate.net]
- 11. ajronline.org [ajronline.org]
- 12. Adrenal imaging for adenoma characterization: imaging features, diagnostic accuracies and differential diagnoses - PMC [pmc.ncbi.nlm.nih.gov]
- 13. What imaging techniques best differentiate benign from malignant adrenal adenomas? - Consensus [consensus.app]
- 14. Advances in multimodal imaging for adrenal gland disorders: integrating CT, MRI, and nuclear medicine - PMC [pmc.ncbi.nlm.nih.gov]
- 15. richtlijndatabase.nl [richtlijndatabase.nl]
- 16. European Nuclear Medicine Guide [nucmed-guide.app]
- 17. Thieme E-Journals - Nuklearmedizin - NuclearMedicine / Abstract [thieme-connect.de]
- 18. Adrenal scintigraphy using ¹³¹I-Adosterol [inis.iaea.org]
- 19. Adrenal Gland | College of American Pathologists [cap.org]
- 20. emedicine.medscape.com [emedicine.medscape.com]
- To cite this document: BenchChem. [Adosterol Uptake vs. Histopathology in Adrenal Tumors: A Comparative Guide]. BenchChem, [2025]. [Online PDF]. Available at: [https://www.benchchem.com/product/b1220196#correlation-of-adosterol-uptake-with-histopathology-of-adrenal-tumors]

Disclaimer & Data Validity:

The information provided in this document is for Research Use Only (RUO) and is strictly not intended for diagnostic or therapeutic procedures. While BenchChem strives to provide accurate protocols, we make no warranties, express or implied, regarding the fitness of this product for every specific experimental setup.

Technical Support: The protocols provided are for reference purposes. Unsure if this reagent suits your experiment? [[Contact our Ph.D. Support Team for a compatibility check](#)]

Need Industrial/Bulk Grade? [Request Custom Synthesis Quote](#)

BenchChem

Our mission is to be the trusted global source of essential and advanced chemicals, empowering scientists and researchers to drive progress in science and industry.

Contact

Address: 3281 E Guasti Rd

Ontario, CA 91761, United States

Phone: (601) 213-4426

Email: info@benchchem.com