

# Addressing the risk of Tafenoquine-induced vortex keratopathy in long-term use

**Author:** BenchChem Technical Support Team. **Date:** December 2025

## Compound of Interest

Compound Name: *Tafenoquine*

Cat. No.: *B011912*

[Get Quote](#)

## Technical Support Center: Tafenoquine-Induced Vortex Keratopathy

This technical support center provides troubleshooting guides and frequently asked questions (FAQs) for researchers, scientists, and drug development professionals investigating **Tafenoquine**-induced vortex keratopathy.

### Frequently Asked Questions (FAQs)

Q1: What is **Tafenoquine**-induced vortex keratopathy?

A1: **Tafenoquine**-induced vortex keratopathy, also known as cornea verticillata, is a condition characterized by whorl-like, golden-brown or gray opacities in the corneal epithelium.<sup>[1][2]</sup> It is a known side effect of long-term **Tafenoquine** use and is generally considered benign and reversible.<sup>[3][4]</sup>

Q2: What is the proposed mechanism for this condition?

A2: The development of vortex keratopathy is attributed to **Tafenoquine**'s properties as a cationic amphiphilic drug.<sup>[5][6][7][8]</sup> These drugs are thought to cause an accumulation of phospholipids within the lysosomes of corneal epithelial cells, a condition known as phospholipidosis.<sup>[6][7][8]</sup> This intracellular buildup leads to the formation of the characteristic corneal deposits.

Q3: What is the incidence of vortex keratopathy in patients taking **Tafenoquine**?

A3: Clinical trials have reported a wide range of incidence, from 21% to 93% of individuals receiving **Tafenoquine** undergoing ophthalmic evaluations.[3][4][9][10] This variability may be due to differences in dosing, duration of treatment, and the sensitivity of detection methods.

Q4: Is **Tafenoquine**-induced vortex keratopathy associated with vision loss?

A4: Generally, this condition does not cause functional changes in vision.[3][4] While some patients may report symptoms like halos or photophobia, these are typically mild.[5][8] The corneal deposits usually resolve within a year after discontinuing the drug.[3][4]

Q5: How is **Tafenoquine**-induced vortex keratopathy diagnosed and monitored in a research setting?

A5: The primary method for diagnosis and monitoring is a thorough ophthalmic examination using a slit-lamp biomicroscope.[11] Advanced imaging techniques such as spectral-domain optical coherence tomography (SD-OCT) and fundus autofluorescence (FAF) can also be employed to assess the cornea and retina for any changes.[12][13]

Q6: How can **Tafenoquine**-induced vortex keratopathy be differentiated from other causes of vortex keratopathy, such as Fabry disease?

A6: While clinically similar, there can be subtle differences. In drug-induced keratopathy, the opacities may appear as horizontal lines with fine branches, whereas in Fabry disease, they often form curving whorls that are straighter at the periphery.[14] In vivo confocal microscopy can also reveal differences in the morphology and distribution of the epithelial deposits.[15][16] A thorough patient history, including medication use and family history of genetic diseases, is also crucial for differential diagnosis.

## Data Presentation

Table 1: Incidence of **Tafenoquine**-Induced Vortex Keratopathy in Clinical Trials

Trial Identifier/Reference	Dosing Regimen	Incidence of Vortex Keratopathy	Notes
Leary et al., 2009; Nasveld et al., 2010; NCT#01290601[3]	Not specified in summary	21% - 93%	Resolved within one year of drug cessation.
Nasveld et al., 2010[17]	200 mg weekly for 6 months (after loading dose)	93% (69/74)	No associated visual disturbances; resolved by 1 year.
NCT#01290601[18]	400 mg x 3 days	31.8% (14/44)	Mild keratopathy observed.
Safety Subgroup Analysis[10]	Not specified in summary	93.2% (69/74)	Changes were not associated with visual disturbances.

## Experimental Protocols

### Methodology 1: Slit-Lamp Examination for Vortex Keratopathy

- Patient Preparation: Ensure the patient is comfortably seated at the slit lamp, with their chin on the chin rest and forehead against the headrest.
- Initial Examination: Begin with low magnification (10x) and diffuse illumination to get an overall view of the anterior segment of both eyes.
- Detailed Corneal Assessment:
  - Increase magnification to 16x or higher.
  - Use a parallelepiped beam (a narrow, rectangular slit of light) to create a three-dimensional view of the cornea.
  - Systematically scan the entire cornea, from limbus to limbus, in a zig-zag or spiral pattern.
  - Pay close attention to the inferior and central cornea where the vortex pattern is often most prominent.

- Documentation: Document the presence, location, and characteristics of any corneal opacities. A grading scale (e.g., mild, moderate, severe) can be used for consistency. Photography through the slit lamp can be used for longitudinal follow-up.

#### Methodology 2: Corneal Imaging with Spectral-Domain Optical Coherence Tomography (SD-OCT)

- Patient Positioning: Position the patient at the SD-OCT machine, ensuring proper alignment and fixation.
- Scan Protocol: Select a high-resolution corneal scanning protocol. The "Anterior Segment Cube 512x128" or similar volumetric scan is recommended to obtain a 3D image of the cornea.[\[19\]](#)
- Image Acquisition: Acquire scans of the central 6mm of the cornea. Ensure the scan is centered on the corneal vertex.[\[12\]](#)
- Image Analysis:
  - Manually review the cross-sectional images (B-scans) to identify any hyper-reflective deposits in the epithelial layer.
  - Use the device's software to generate an epithelial thickness map. While vortex keratopathy is not primarily a change in thickness, localized irregularities may be observed.
  - Analyze the en face images, if available, to visualize the whorl-like pattern of the deposits.

## Troubleshooting Guides

### Issue 1: Difficulty Visualizing Vortex Keratopathy with Slit-Lamp

- Question: The characteristic whorl-like pattern is not clearly visible, but I suspect the presence of vortex keratopathy. What can I do?
- Answer:

- Optimize Illumination: Use a parallelepiped beam and vary the angle of illumination. Sclerotic scatter, where the light is directed at the limbus, can sometimes highlight subtle corneal opacities.
- Increase Magnification: Use the highest magnification that maintains a clear image.
- Use a Red-Free Filter: A green filter can sometimes enhance the contrast of the golden-brown deposits against the cornea.
- Consider Indirect Illumination: Focus the light adjacent to the area of interest to see if the deposits are illuminated by scattered light.

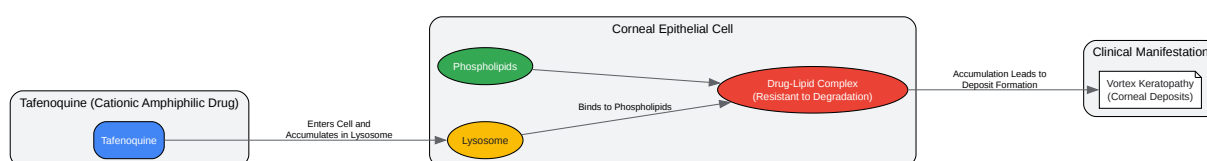
## Issue 2: Artifacts in SD-OCT Imaging of the Cornea

- Question: My SD-OCT images of the cornea have artifacts that are interfering with the assessment of the epithelium. How can I minimize these?
- Answer:
  - Blink and Tear Film Issues: Ensure the patient blinks normally before the scan to maintain a stable tear film. Instilling a single drop of artificial tears 5 minutes before imaging can help improve image quality.[\[19\]](#)
  - Motion Artifacts: Instruct the patient to fixate steadily on the target and to hold still during the scan. Repeat the scan if motion is evident (visible as jagged lines or breaks in the image).
  - Segmentation Errors: Manually review the automated segmentation lines that delineate the different corneal layers. If the software has incorrectly identified the epithelial boundaries, manually correct them if the software allows, or be aware of the error during interpretation.
  - Poor Signal Strength: This can be caused by factors like cataracts or dry eye.[\[20\]](#) Address underlying issues where possible (e.g., artificial tears for dry eye). A poor signal strength will be indicated on the device's quality score.

## Issue 3: Differentiating **Tafenoquine**-Induced Keratopathy from Imaging Artifacts

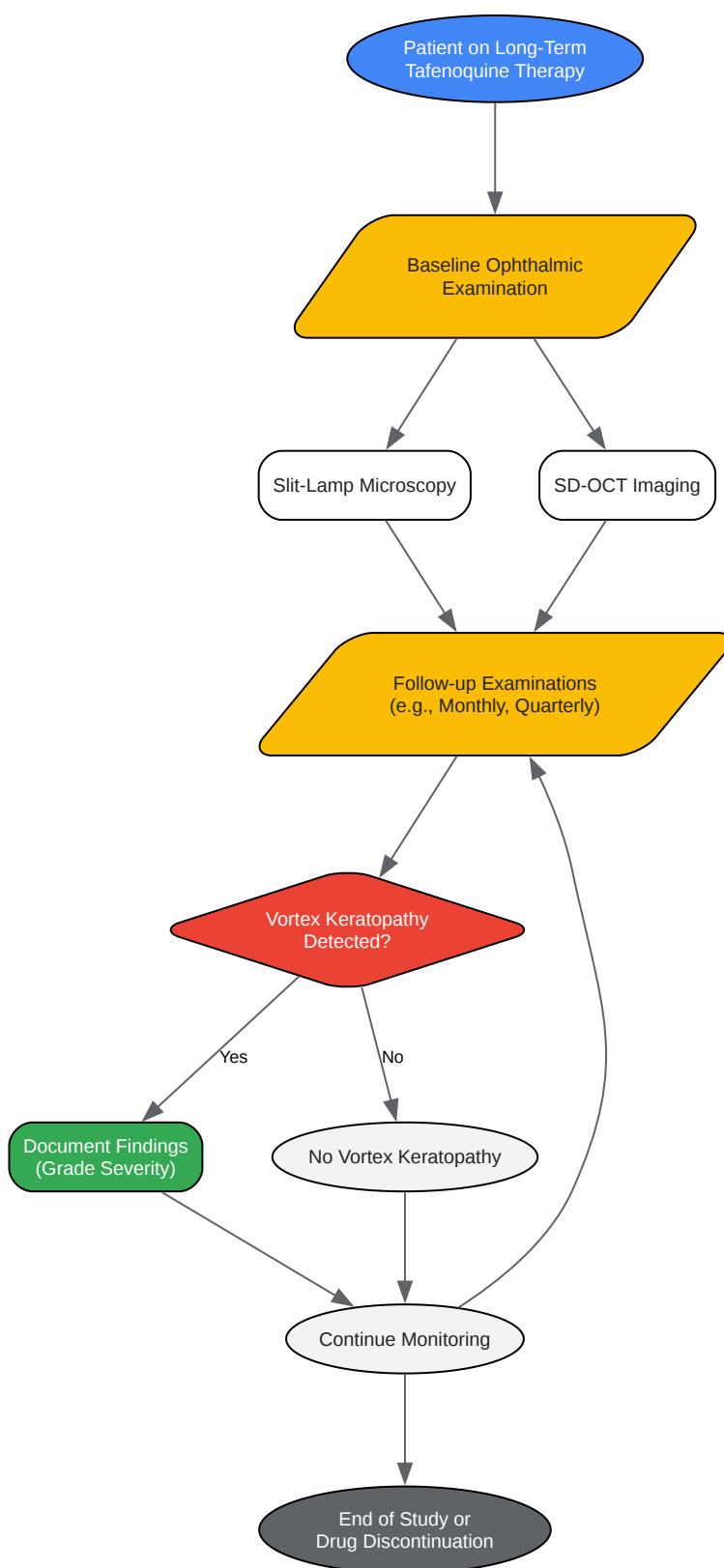
- Question: I see hyper-reflective spots on the SD-OCT. How can I be sure they are part of vortex keratopathy and not just noise or an artifact?
- Answer:
  - Correlate with Slit-Lamp Findings: The most reliable method is to correlate the location of the hyper-reflective areas on the OCT with the opacities seen during the slit-lamp examination.
  - Look for the Characteristic Pattern: True vortex keratopathy will typically show a swirling or linear pattern of deposits, especially when viewed on en face reconstructions. Randomly scattered hyper-reflective spots are more likely to be noise.
  - Check Scan Quality: Review the scan's quality score. Low-quality scans are more prone to artifacts that can mimic pathology.
  - Repeat the Scan: If in doubt, repeat the scan to see if the "deposits" are reproducible. Artifacts are often inconsistent between scans.

## Mandatory Visualizations



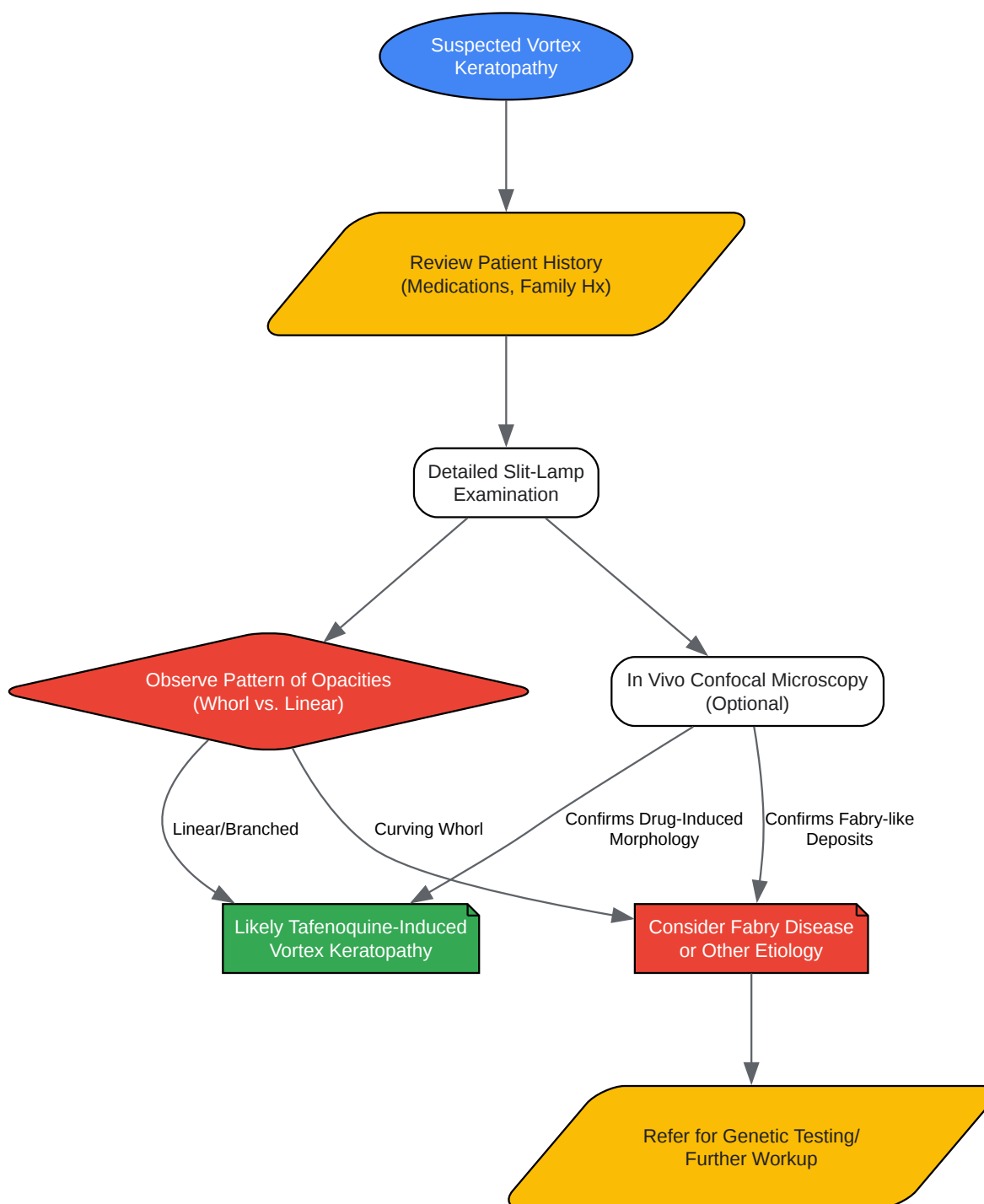
[Click to download full resolution via product page](#)

Caption: Proposed mechanism of **Tafenoquine**-induced vortex keratopathy.



[Click to download full resolution via product page](#)

Caption: Experimental workflow for monitoring vortex keratopathy.



[Click to download full resolution via product page](#)

Caption: Logical relationship for differential diagnosis of vortex keratopathy.



**Need Custom Synthesis?**

BenchChem offers custom synthesis for rare earth carbides and specific isotopic labeling.

Email: [info@benchchem.com](mailto:info@benchchem.com) or [Request Quote Online](#).

## References

- 1. researchgate.net [researchgate.net]
- 2. uthsc.edu [uthsc.edu]
- 3. In vitro assays and biomarkers for drug-induced phospholipidosis - PubMed [pubmed.ncbi.nlm.nih.gov]
- 4. Identification of Drugs Inducing Phospholipidosis by Novel in vitro Data - PMC [pmc.ncbi.nlm.nih.gov]
- 5. pubs.acs.org [pubs.acs.org]
- 6. Drug-induced corneal deposits: an up-to-date review - PMC [pmc.ncbi.nlm.nih.gov]
- 7. researchgate.net [researchgate.net]
- 8. Drug-induced corneal epithelial changes - PubMed [pubmed.ncbi.nlm.nih.gov]
- 9. academic.oup.com [academic.oup.com]
- 10. Tafenoquine - Assessment of Long-Term Health Effects of Antimalarial Drugs When Used for Prophylaxis - NCBI Bookshelf [ncbi.nlm.nih.gov]
- 11. tga.gov.au [tga.gov.au]
- 12. 2.3. Spectral-Domain-Optical Coherence Tomography [bio-protocol.org]
- 13. The Nuts and Bolts of Fundus Autofluorescence Imaging - American Academy of Ophthalmology [aao.org]
- 14. upjo.org [upjo.org]
- 15. In Vivo Confocal Microscopic Observations of Vortex Keratopathy in Patients with Amiodarone-Induced Keratopathy and Fabry Disease - PMC [pmc.ncbi.nlm.nih.gov]
- 16. Ophthalmic Manifestations in Fabry Disease: Updated Review - PMC [pmc.ncbi.nlm.nih.gov]
- 17. Randomized Placebo-Controlled Trial Evaluating the Ophthalmic Safety of Single-Dose Tafenoquine in Healthy Volunteers - PMC [pmc.ncbi.nlm.nih.gov]

- 18. researchgate.net [researchgate.net]
- 19. Spectral-domain OCT [bio-protocol.org]
- 20. Don't Be Fooled: Spotting OCT Artifacts [reviewofophthalmology.com]
- To cite this document: BenchChem. [Addressing the risk of Tafenoquine-induced vortex keratopathy in long-term use]. BenchChem, [2025]. [Online PDF]. Available at: [https://www.benchchem.com/product/b011912#addressing-the-risk-of-tafenoquine-induced-vortex-keratopathy-in-long-term-use]

---

### Disclaimer & Data Validity:

The information provided in this document is for Research Use Only (RUO) and is strictly not intended for diagnostic or therapeutic procedures. While BenchChem strives to provide accurate protocols, we make no warranties, express or implied, regarding the fitness of this product for every specific experimental setup.

**Technical Support:** The protocols provided are for reference purposes. Unsure if this reagent suits your experiment? [[Contact our Ph.D. Support Team for a compatibility check](#)]

**Need Industrial/Bulk Grade?** [Request Custom Synthesis Quote](#)

## BenchChem

Our mission is to be the trusted global source of essential and advanced chemicals, empowering scientists and researchers to drive progress in science and industry.

### Contact

Address: 3281 E Guasti Rd  
Ontario, CA 91761, United States  
Phone: (601) 213-4426  
Email: [info@benchchem.com](mailto:info@benchchem.com)