

Addressing low signal-to-noise in extrastriatal [18F]fallypride PET

Author: BenchChem Technical Support Team. **Date:** December 2025

Compound of Interest

Compound Name: Fallypride

Cat. No.: B043967

[Get Quote](#)

Technical Support Center: [18F]fallypride PET Imaging

This technical support center provides troubleshooting guidance and frequently asked questions to address the challenge of low signal-to-noise ratio (SNR) in extrastriatal [18F]**fallypride** Positron Emission Tomography (PET) imaging.

Frequently Asked Questions (FAQs)

Q1: Why is the signal-to-noise ratio inherently low in extrastriatal regions when using [18F]**fallypride** PET?

A1: The low SNR in extrastriatal areas is primarily due to the significantly lower density of dopamine D2/D3 receptors in these regions compared to the striatum.^{[1][2]} Extrastriatal D2/D3 receptor densities can be one to two orders of magnitude lower than in the striatum.^[2] This low receptor density results in a reduced specific binding signal, making it more susceptible to noise. To counteract this, high-affinity radiotracers like [18F]**fallypride** are necessary.^[1]

Q2: What is [18F]**fallypride** and why is it used for imaging both striatal and extrastriatal regions?

A2: [18F]**fallypride** is a high-affinity radioligand for dopamine D2/D3 receptors.^{[2][3][4][5]} Its high affinity makes it suitable for visualizing these receptors in both high-density striatal and

low-density extrastriatal areas.[5] The use of the Fluorine-18 isotope, with its longer half-life compared to Carbon-11, allows for longer scan durations, which is crucial for reliably quantifying [18F]**fallypride** binding in the slowly clearing striatum while also capturing the lower signal in extrastriatal regions in the same session.[6]

Q3: What are the main factors that contribute to low signal-to-noise in my extrastriatal [18F]**fallypride** PET data?

A3: Several factors can contribute to low SNR, including:

- Low Receptor Density: As mentioned, this is the primary biological reason.[1][2]
- Partial Volume Effects (PVE): The limited spatial resolution of PET scanners can cause the signal from small extrastriatal structures to be underestimated due to spill-over from adjacent regions with lower radioactivity.[1][3][7]
- Patient Motion: Movement during the long acquisition times can lead to blurred images, misregistration between PET and CT/MRI, and inaccurate attenuation correction, all of which degrade image quality and quantitative accuracy.[8][9][10][11][12]
- Suboptimal Acquisition and Reconstruction Parameters: Inadequate scan duration or inappropriate reconstruction algorithms and settings can increase noise and reduce signal recovery.[13][14]
- Inaccurate Attenuation and Scatter Correction: Errors in these correction processes can introduce bias and increase variance in the final image data.[15]

Q4: Can the choice of reference region impact the signal-to-noise ratio and quantification?

A4: Yes, the choice of reference region is critical for kinetic models like the Simplified Reference Tissue Model (SRTM). The cerebellum is commonly used due to its negligible density of D2/D3 receptors.[2] However, issues like spill-over effects from skull uptake of free fluoride can introduce uncertainty.[16] One study suggested that a white matter region, such as the superior longitudinal fasciculus, may be a reasonable alternative to the cerebellum, showing similar statistical properties.[15]

Troubleshooting Guides

Issue 1: High Image Noise in Extrastriatal Regions

Question: My reconstructed [^{18}F]**fallypride** PET images of extrastriatal regions are excessively noisy, making it difficult to accurately quantify binding potential. What are the potential causes and how can I reduce the noise?

Answer: High image noise is a common challenge that can be addressed by optimizing acquisition and reconstruction parameters.

Potential Causes and Solutions:

Potential Cause	Recommended Solution
Insufficient Injected Dose	Ensure the injected dose of [18F]fallypride is appropriate for the subject's weight and the sensitivity of the PET scanner. Lower doses lead to lower count statistics and consequently higher noise.[14]
Short Acquisition Time	The scan duration may be too short to collect a sufficient number of coincidence events, especially for the low-signal extrastriatal regions. Increasing the acquisition time can improve the signal-to-noise ratio.[5][14] A scan time of at least 2 hours is often necessary for accurate estimation in all brain regions.[5]
Suboptimal Image Reconstruction	The choice of reconstruction algorithm and its parameters significantly impacts image noise. Iterative reconstruction methods like Ordered Subset Expectation Maximization (OSEM) are common.[15] The number of iterations and subsets, as well as the use of post-reconstruction filtering, should be optimized. For instance, one study on a Siemens Biograph mCT system identified two iterations, 21 subsets, and a 5 mm FWHM Gaussian filter as optimal for an OSEM algorithm with Time-of-Flight (TOF).[13] Bayesian Penalized Likelihood (BPL) reconstruction algorithms (like Q-clear) can also improve signal-to-noise.[13]

Issue 2: Underestimation of Binding Potential in Small Extrastriatal Structures

Question: The binding potential (BP) values in smaller extrastriatal regions like the amygdala and thalamus seem lower than expected. What could be causing this and how can it be corrected?

Answer: This is a classic presentation of the Partial Volume Effect (PVE), which leads to an underestimation of the true radioactivity concentration in small structures.

Potential Causes and Solutions:

Potential Cause	Recommended Solution
Partial Volume Effects (PVE)	The limited spatial resolution of PET scanners causes a "spill-over" of signal between adjacent regions. This is particularly problematic for small extrastriatal nuclei surrounded by areas of lower tracer uptake. [3] [7] Implementing Partial Volume Correction (PVC) is crucial. PVC can lead to substantial increases in BP values, ranging from 30% to over 100% in extrastriatal regions, and can reveal group differences that were not significant in uncorrected data. [1] Various PVC methods exist, including voxel-based and region of interest (ROI)-based approaches. [1]
Inaccurate Anatomical Delineation	PVE correction often relies on accurate anatomical information from co-registered MRI scans. Ensure precise co-registration of PET and MRI data and accurate delineation of the regions of interest (ROIs).

Impact of Partial Volume Correction on $[18F]$ allypride Binding Potential (BP)

Brain Region	Increase in BP with PVC (Controls)	Increase in BP with PVC (Schizophrenia Patients)
Thalamus	30%	33%
Post-commissural Caudate	94%	103%
Uncus	109%	88%

Data summarized from a study on schizophrenia patients and healthy controls.[\[1\]](#)

Issue 3: Inconsistent Results and Motion Artifacts

Question: We are observing high variability in our results and sometimes see blurring or artifacts in the PET images. Could patient motion be the cause?

Answer: Yes, patient motion is a significant source of error in $[^{18}\text{F}]\text{fallypride}$ PET due to the long scan times required.

Potential Causes and Solutions:

Potential Cause	Recommended Solution
Patient Head Motion	Even small movements during the lengthy scan can lead to significant image degradation, blurring, and misalignment between PET frames and with the anatomical MRI/CT. [8] [9] [10] [12] This can result in inaccurate quantification of tracer uptake. [10] [11]
Misalignment of PET and CT/MRI	Motion can cause a misalignment between the PET emission data and the CT or MRI used for attenuation correction and anatomical localization. This leads to incorrect attenuation correction and mislocalization of the signal. [8] [12]

Mitigation Strategies:

- **Head Fixation:** Use head holders and other fixation devices to minimize patient movement.
- **Motion Correction:** Employ motion correction algorithms during image reconstruction. This often involves frame-by-frame realignment of the dynamic PET data.[\[15\]](#)[\[17\]](#)
- **Data-Driven Gating:** For respiratory motion, data-driven gating techniques can be used to reconstruct images from specific phases of the respiratory cycle.[\[18\]](#)

Experimental Protocols

[18F]fallypride PET Scanning Protocol

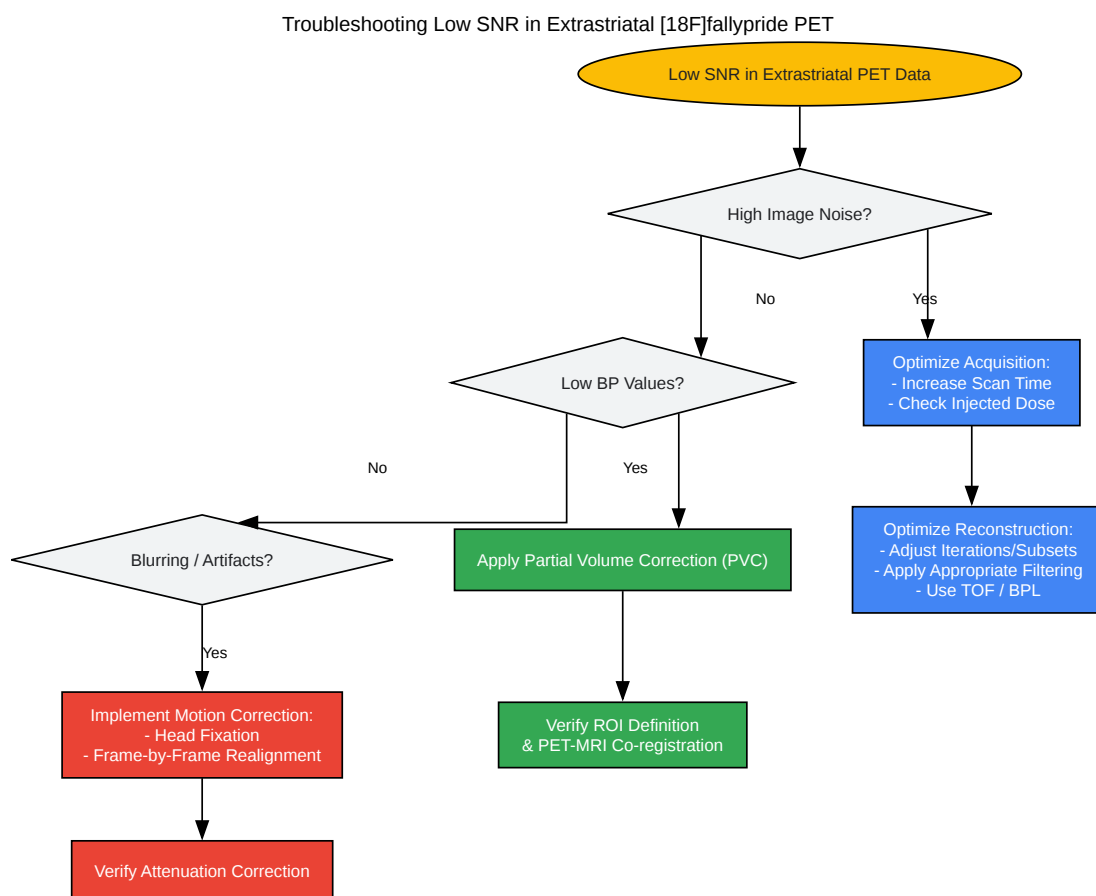
This protocol is a representative example and should be adapted based on the specific scanner and research question.

- **Subject Preparation:** Subjects should be positioned comfortably in the PET scanner to minimize motion. Head fixation is recommended.
- **Radiotracer Injection:** A bolus injection of [18F]**fallypride** (e.g., ~185 MBq \pm 5%) is administered intravenously.[\[15\]](#)
- **Dynamic Data Acquisition:** Dynamic emission data are acquired for an extended period, often up to 240 minutes, to allow for quantification in both striatal and extrastriatal regions.[\[1\]](#) The acquisition can be divided into frames of increasing duration (e.g., 3 x 20s, 3 x 1 min, 3 x 2 min, 2 x 5 min, and 13 x 10 min).[\[1\]](#) Breaks for subject comfort can be incorporated, with transmission scans performed before and after breaks for attenuation correction.[\[1\]](#)[\[19\]](#)
- **Attenuation and Scatter Correction:** A transmission scan (using 68Ge/68Ga rotating rod sources) or a CT scan is performed for attenuation correction.[\[15\]](#)[\[19\]](#) Data should be corrected for decay, attenuation, and scatter.[\[15\]](#)
- **Image Reconstruction:** Data are reconstructed using an appropriate algorithm (e.g., OSEM with 3 iterations and 16 subsets).[\[15\]](#)

Image Analysis and Quantification

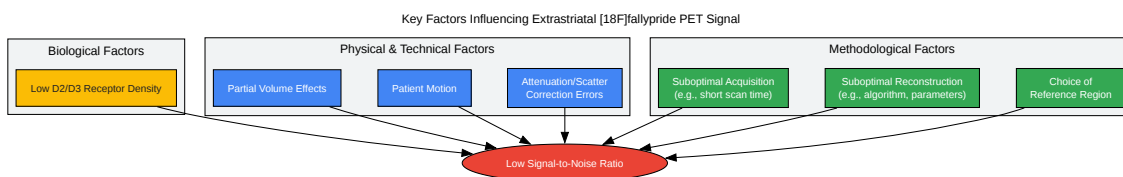
- **Motion Correction:** The dynamic PET images are co-registered to a reference frame (e.g., an average of early frames or a single frame) to correct for inter-frame motion.[\[15\]](#)[\[17\]](#)
- **Co-registration to MRI:** The mean PET image is co-registered to the subject's structural T1-weighted MRI to allow for anatomically defined regions of interest (ROIs).[\[15\]](#)[\[17\]](#)
- **Kinetic Modeling:** Time-activity curves (TACs) are extracted from the ROIs. The binding potential (BP_{ND}) is often calculated using a reference tissue model, such as the Simplified Reference Tissue Model (SRTM), with the cerebellum typically serving as the reference region.[\[2\]](#)[\[17\]](#)

Visualizations



[Click to download full resolution via product page](#)

Caption: A troubleshooting workflow for addressing low SNR.



[Click to download full resolution via product page](#)

Caption: Factors contributing to low SNR in extrastriatal PET.

Need Custom Synthesis?

BenchChem offers custom synthesis for rare earth carbides and specific isotopic labeling.

Email: info@benchchem.com or [Request Quote Online](#).

References

- 1. Striatal and extrastriatal dopamine D2/D3 receptors in schizophrenia evaluated with [^{18}F]fallypride PET - PMC [pmc.ncbi.nlm.nih.gov]
- 2. Optimized In Vivo Detection of Dopamine Release Using ^{18}F -Fallypride PET | Journal of Nuclear Medicine [jnm.snmjournals.org]
- 3. Striatal and Extrastriatal microPET Imaging of D2/D3 Dopamine Receptors in Rat Brain with [^{18}F]Fallypride and [^{18}F]Desmethoxyfallypride - PMC [pmc.ncbi.nlm.nih.gov]
- 4. In vivo affinity of [^{18}F]fallypride for striatal and extrastriatal dopamine D2 receptors in nonhuman primates - PubMed [pubmed.ncbi.nlm.nih.gov]
- 5. Quantitation of striatal and extrastriatal D-2 dopamine receptors using PET imaging of [^{18}F]fallypride in nonhuman primates - PubMed [pubmed.ncbi.nlm.nih.gov]

- 6. Striatal and extrastriatal dopamine release measured with PET and [18F]fallypride - PMC [pmc.ncbi.nlm.nih.gov]
- 7. scispace.com [scispace.com]
- 8. Frontiers | F-18 FDG PET/CT Imaging in Normal Variants, Pitfalls and Artifacts in the Abdomen and Pelvis [frontiersin.org]
- 9. F-18 FDG PET/CT Imaging in Normal Variants, Pitfalls and Artifacts in the Abdomen and Pelvis - PMC [pmc.ncbi.nlm.nih.gov]
- 10. Impact of patient motion on parametric PET imaging - PMC [pmc.ncbi.nlm.nih.gov]
- 11. researchgate.net [researchgate.net]
- 12. Frontiers | Motion-correction strategies for enhancing whole-body PET imaging [frontiersin.org]
- 13. Making sure you're not a bot! [gupea.ub.gu.se]
- 14. benchchem.com [benchchem.com]
- 15. The Simplified Reference Tissue Model with 18F-fallypride PET: Choice of Reference Region - PMC [pmc.ncbi.nlm.nih.gov]
- 16. [18F]fallypride dopamine D2 receptor studies using delayed microPET scans and a modified Logan plot - PMC [pmc.ncbi.nlm.nih.gov]
- 17. [18F]fallypride characterization of striatal and extrastriatal D2/3 receptors in Parkinson's disease - PMC [pmc.ncbi.nlm.nih.gov]
- 18. Impact of respiratory motion on 18F-FDG PET radiomics stability: Clinical evaluation with a digital PET scanner - PMC [pmc.ncbi.nlm.nih.gov]
- 19. Partial-volume correction increases estimated dopamine D2-like receptor binding potential and reduces adult age differences - PMC [pmc.ncbi.nlm.nih.gov]
- To cite this document: BenchChem. [Addressing low signal-to-noise in extrastriatal [18F]fallypride PET]. BenchChem, [2025]. [Online PDF]. Available at: [https://www.benchchem.com/product/b043967#addressing-low-signal-to-noise-in-extrastriatal-18f-fallypride-pet]

Disclaimer & Data Validity:

The information provided in this document is for Research Use Only (RUO) and is strictly not intended for diagnostic or therapeutic procedures. While BenchChem strives to provide

accurate protocols, we make no warranties, express or implied, regarding the fitness of this product for every specific experimental setup.

Technical Support: The protocols provided are for reference purposes. Unsure if this reagent suits your experiment? [[Contact our Ph.D. Support Team for a compatibility check](#)]

Need Industrial/Bulk Grade? [Request Custom Synthesis Quote](#)

BenchChem

Our mission is to be the trusted global source of essential and advanced chemicals, empowering scientists and researchers to drive progress in science and industry.

Contact

Address: 3281 E Guasti Rd
Ontario, CA 91761, United States
Phone: (601) 213-4426
Email: info@benchchem.com