

A Technical Guide to the Non-Cardiac Applications of Thallium-201

Author: BenchChem Technical Support Team. **Date:** December 2025

Compound of Interest

Compound Name: Thallium-201

Cat. No.: B079191

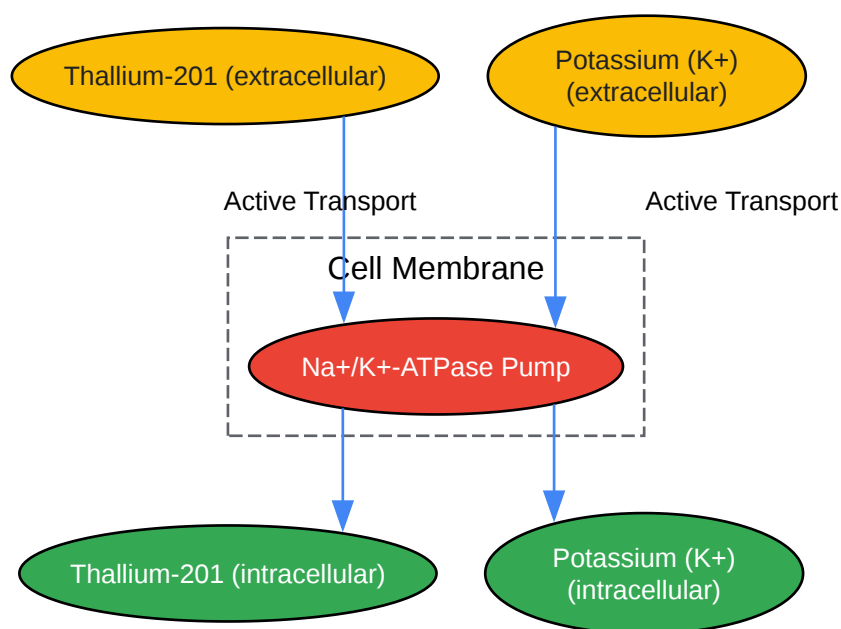
[Get Quote](#)

For Researchers, Scientists, and Drug Development Professionals

Thallium-201 (^{201}Tl), a radiopharmaceutical traditionally recognized for its pivotal role in myocardial perfusion imaging, has demonstrated significant utility in a variety of non-cardiac applications.^{[1][2][3][4][5][6][7][8]} Its properties as a potassium analog allow it to be actively transported into cells, providing a functional assessment of tissue viability and metabolic activity.^{[4][5][9][10][11][12][13]} This guide offers an in-depth exploration of the core principles, experimental protocols, and clinical data supporting the use of ^{201}Tl in oncology and parathyroid imaging.

Mechanism of Thallium-201 Uptake

The primary mechanism governing the uptake of ^{201}Tl in both healthy and tumor cells is its behavior as a potassium (K^+) analog.^{[4][5][11][12][13]} This allows it to be actively transported across the cell membrane via the Na^+/K^+ -ATPase pump.^{[9][11]} Tumorous tissues, characterized by high metabolic activity and increased regional blood flow, often exhibit enhanced ^{201}Tl accumulation.^{[9][14]} The uptake is therefore indicative of cellular viability and metabolic state.^{[9][10]} Studies have shown that the activity of the Na^+/K^+ pump is a more critical factor for ^{201}Tl uptake in tumors than blood flow alone.^[9]



[Click to download full resolution via product page](#)

Mechanism of **Thallium-201** cellular uptake.

Oncologic Applications

201Tl scintigraphy has been extensively evaluated for the diagnosis, staging, and assessment of treatment response in various malignancies.[2][15] It is particularly valuable in differentiating viable tumor tissue from necrosis or fibrosis, a common challenge with anatomical imaging modalities like CT and MRI.[16]

201Tl SPECT has shown greater accuracy than CT scans in evaluating brain tumor burden and identifying disease progression or regression following therapy. It is effective in distinguishing recurrent tumors from radiation necrosis, as 201Tl accumulation is minimal in necrotic tissue. [14][17] The uptake of 201Tl in brain tumors is proportional to the malignant grade and is not significantly affected by steroid administration.[14]

Parameter	201TI SPECT	CT Scan	Reference
Identified Disease (23 patients)	23	20	
Identified No Recurrence (11 patients)	11	6	
Progression on Follow-up (17 patients)	9	3	

Sequential 201TI scintigraphy is a useful tool for assessing the histological response of high-grade osteosarcomas and soft-tissue sarcomas to preoperative chemotherapy.[10] A reduction in 201TI uptake post-chemotherapy correlates well with tumor necrosis.[10][18]

Imaging Phase	Sensitivity	Specificity	Accuracy	Reference
Early	94%	65%	82%	[18]
Delayed	94%	85%	90%	[18]

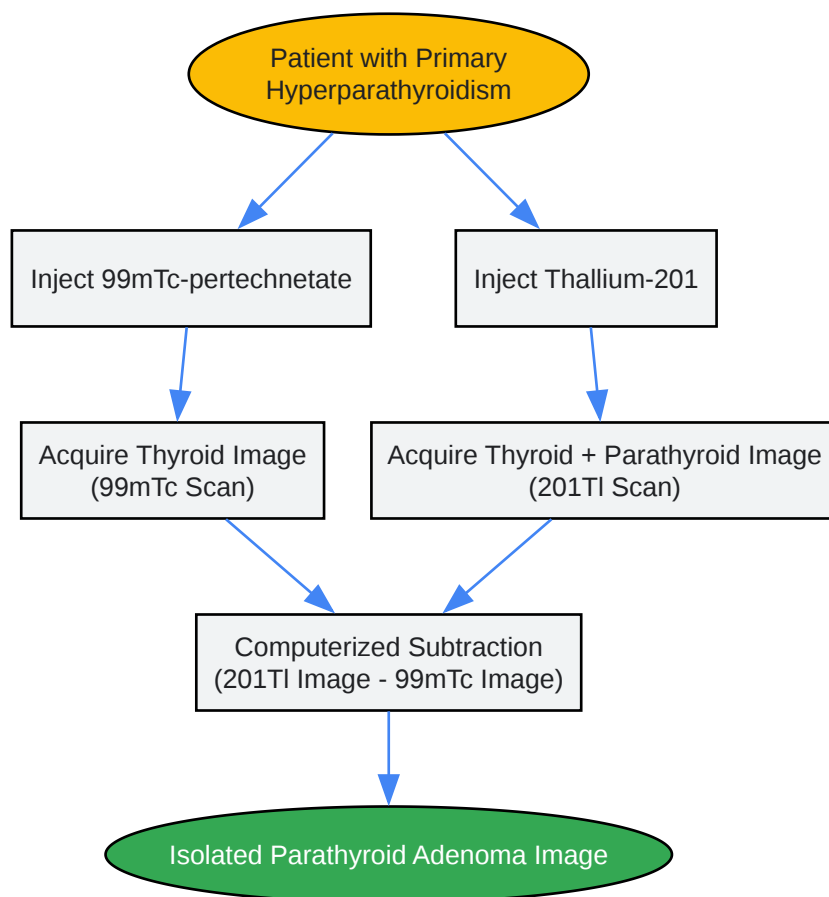
201TI imaging has also been applied to a range of other cancers, including lung, breast, thyroid, and lymphoma.[2][9] For lung cancer, it has a reported sensitivity of 91-100%, though it is best suited for lesions larger than 2 cm.[14] However, its specificity can be limited by uptake in benign inflammatory conditions such as tuberculosis and sarcoidosis.[14] In comparison to FDG-PET in lung cancer, FDG-PET is generally considered superior, especially for smaller lesions and mediastinal staging.[19][20] For head and neck cancers, 201TI SPECT has demonstrated high accuracy in identifying primary tumors, metastases, and recurrences.[21]

Parathyroid Imaging

201TI scintigraphy, typically in conjunction with Technetium-99m (99mTc) subtraction imaging, is used for the preoperative localization of parathyroid adenomas in patients with primary hyperparathyroidism.[11][22] 201TI accumulates in both the thyroid and parathyroid glands,

while ^{99m}Tc pertechnetate is taken up only by the thyroid.[11] By subtracting the ^{99m}Tc image from the ^{201}Tl image, the location of the parathyroid adenoma can be identified.

The sensitivity of this technique varies widely in the literature, with some studies reporting sensitivities as high as 87.5%, while others have found it to be less reliable, particularly for smaller glands.[22][23][24] The success of localization often correlates with the size of the adenoma and parathyroid hormone levels.[22][24]



[Click to download full resolution via product page](#)

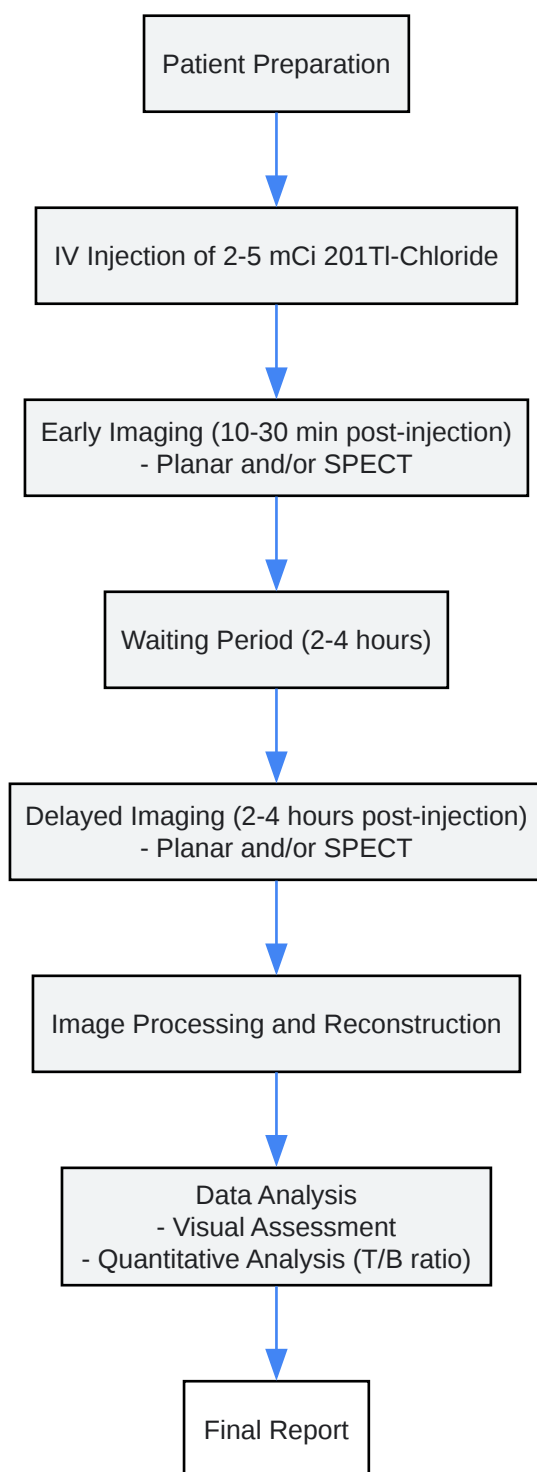
Workflow for **Thallium-201**/Technetium-99m subtraction scintigraphy.

Experimental Protocols

While specific parameters may vary between institutions, a general protocol for ^{201}Tl tumor scintigraphy can be outlined.

- Dose: 2-5 mCi (74-185 MBq) of ^{201}Tl chloride is administered intravenously.[2][25]

- Scanner: A dual-headed gamma camera equipped with a low-energy, all-purpose or high-resolution collimator is typically used.[\[2\]](#)[\[25\]](#)
- Imaging Times:
 - Early Phase: Imaging is performed 10-30 minutes post-injection.[\[2\]](#)[\[25\]](#)
 - Delayed Phase: Imaging is repeated 2-4 hours post-injection.[\[14\]](#)[\[25\]](#) The retention of ²⁰¹Tl in malignant lesions on delayed images helps differentiate them from benign lesions, which tend to show washout of the tracer.[\[14\]](#)[\[15\]](#)
- Imaging Type: Both static planar and Single Photon Emission Computed Tomography (SPECT) images are acquired.[\[2\]](#) SPECT imaging is particularly useful for better localization and characterization of lesions.[\[15\]](#)
- Qualitative Analysis: Images are visually assessed for areas of abnormal ²⁰¹Tl uptake.
- Quantitative Analysis: A common method involves calculating a tumor-to-background (T/B) or lesion-to-normal tissue ratio. This is done by drawing regions of interest (ROIs) over the tumor and a contralateral normal area.[\[25\]](#) These ratios can be calculated for both early and delayed images to assess tracer uptake and retention.



[Click to download full resolution via product page](#)

Need Custom Synthesis?

BenchChem offers custom synthesis for rare earth carbides and specific isotopic labeling.

Email: info@benchchem.com or [Request Quote Online](#).

References

- 1. Thallium-201 - StatPearls - NCBI Bookshelf [ncbi.nlm.nih.gov]
- 2. To study the efficacy of thallium-201 as tumor seeking agent and to study its role in therapeutic response - PMC [pmc.ncbi.nlm.nih.gov]
- 3. radiopaedia.org [radiopaedia.org]
- 4. Thallium 201 scintigraphy - PubMed [pubmed.ncbi.nlm.nih.gov]
- 5. Thallium 201 Scintigraphy - PMC [pmc.ncbi.nlm.nih.gov]
- 6. openmedscience.com [openmedscience.com]
- 7. Thallium-201 as a myocardial imaging agent - PubMed [pubmed.ncbi.nlm.nih.gov]
- 8. researchgate.net [researchgate.net]
- 9. Mechanism of ²⁰¹Tl uptake in tumours - PubMed [pubmed.ncbi.nlm.nih.gov]
- 10. Thallium-201 scanning for the evaluation of osteosarcoma and soft-tissue sarcoma. A study of the evaluation and predictability of the histological response to chemotherapy - PubMed [pubmed.ncbi.nlm.nih.gov]
- 11. dovepress.com [dovepress.com]
- 12. scholarscompass.vcu.edu [scholarscompass.vcu.edu]
- 13. Adenosine SPECT Thallium Imaging - StatPearls - NCBI Bookshelf [ncbi.nlm.nih.gov]
- 14. auntminnie.com [auntminnie.com]
- 15. [Diagnosis of tumor with thallium-201] - PubMed [pubmed.ncbi.nlm.nih.gov]
- 16. Thallium-201 brain tumor imaging: a comparative study with pathologic correlation - PubMed [pubmed.ncbi.nlm.nih.gov]
- 17. jnm.snmjournals.org [jnm.snmjournals.org]
- 18. Clinical significance of thallium-201 scintigraphy in bone and soft tissue tumors - PubMed [pubmed.ncbi.nlm.nih.gov]
- 19. Comparison of fluorine-18-FDG PET and thallium-201 SPECT in evaluation of lung cancer - PubMed [pubmed.ncbi.nlm.nih.gov]
- 20. Imaging with F-18 FDG PET is superior to Tl-201 SPECT in the staging of non-small cell lung cancer for radical radiation therapy - PubMed [pubmed.ncbi.nlm.nih.gov]
- 21. Thallium-201 SPECT in the diagnosis of head and neck cancer - PubMed [pubmed.ncbi.nlm.nih.gov]

- 22. Localization of enlarged parathyroid glands by thallium-201 and technetium-99m subtraction imaging. Gland mass and parathormone levels in primary hyperparathyroidism - PubMed [pubmed.ncbi.nlm.nih.gov]
- 23. Parathyroid imaging with thallium-201 subtraction scintigraphy: a report of 33 cases - PubMed [pubmed.ncbi.nlm.nih.gov]
- 24. Localization of abnormal parathyroid gland(s) using thallium-201/iodine-123 subtraction scintigraphy in patients with primary hyperparathyroidism - PubMed [pubmed.ncbi.nlm.nih.gov]
- 25. The Role of Thallium-201 Scintigraphy in Bone and Soft Tissue Tumor. [e-jyms.org]
- To cite this document: BenchChem. [A Technical Guide to the Non-Cardiac Applications of Thallium-201]. BenchChem, [2025]. [Online PDF]. Available at: [https://www.benchchem.com/product/b079191#exploring-thallium-201-for-non-cardiac-applications]

Disclaimer & Data Validity:

The information provided in this document is for Research Use Only (RUO) and is strictly not intended for diagnostic or therapeutic procedures. While BenchChem strives to provide accurate protocols, we make no warranties, express or implied, regarding the fitness of this product for every specific experimental setup.

Technical Support: The protocols provided are for reference purposes. Unsure if this reagent suits your experiment? [[Contact our Ph.D. Support Team for a compatibility check](#)]

Need Industrial/Bulk Grade? [Request Custom Synthesis Quote](#)

BenchChem

Our mission is to be the trusted global source of essential and advanced chemicals, empowering scientists and researchers to drive progress in science and industry.

Contact

Address: 3281 E Guasti Rd
Ontario, CA 91761, United States
Phone: (601) 213-4426
Email: info@benchchem.com