

# A Researcher's Guide to Positive and Negative Controls for CD235a Immunohistochemistry

**Author:** BenchChem Technical Support Team. **Date:** December 2025

## Compound of Interest

Compound Name: CD235

Cat. No.: B12299716

[Get Quote](#)

For researchers, scientists, and drug development professionals, the precise identification of erythroid lineage cells is critical. **CD235a**, also known as Glycophorin A, is a well-established marker for these cells. However, the reliability of immunohistochemistry (IHC) staining for **CD235a** hinges on the meticulous use of appropriate positive and negative controls. This guide provides a comprehensive comparison of recommended controls, alternative markers, and detailed experimental protocols to ensure the accuracy and reproducibility of your results.

The validation of any immunohistochemical staining protocol is fundamentally reliant on the inclusion of proper controls. Positive controls confirm that the antibody and detection system are working correctly, while negative controls help to identify non-specific staining. For **CD235a**, a sialoglycoprotein expressed on the surface of erythrocytes and their precursors, the choice of controls is paramount for accurate interpretation of erythroid cell presence and development.<sup>[1]</sup>  
<sup>[2]</sup>

## Positive Controls for CD235a: Ensuring Staining Efficacy

Positive control tissues are those known to express the target antigen. For **CD235a**, the most reliable positive controls are tissues rich in erythroid cells at various stages of maturation.

Recommended Positive Control Tissues:

- **Bone Marrow:** As the primary site of erythropoiesis, bone marrow is the gold standard positive control for **CD235a**.<sup>[3]</sup> It contains a heterogeneous population of erythroid precursors, from early proerythroblasts to mature erythrocytes, allowing for the assessment of the antibody's ability to detect the antigen across different developmental stages.
- **Spleen:** The red pulp of the spleen, involved in filtering blood and housing a reserve of red blood cells, serves as another excellent positive control tissue.
- **Peripheral Blood Smear:** A simple and effective positive control can be prepared from a peripheral blood smear, which is predominantly composed of mature erythrocytes that strongly express **CD235a**.
- **K562 Cell Line:** For a consistent and renewable source of positive control material, the human erythroleukemia cell line K562 can be used. These cells are known to express Glycophorin A.

Table 1: Comparison of Positive Control Performance for **CD235a** IHC

Control Tissue	Expected Staining Pattern	Advantages	Disadvantages
Bone Marrow	Membranous staining of erythroid precursors and mature erythrocytes.	Represents various maturation stages; high physiological relevance.	Cellular heterogeneity can sometimes make interpretation complex.
Spleen	Strong membranous staining in the red pulp.	Abundant target antigen; readily available.	Staining may be less uniform than in bone marrow.
Peripheral Blood Smear	Uniform, strong membranous staining of red blood cells.	Easy to prepare; highly consistent staining.	Primarily shows mature erythrocytes; limited view of precursor staining.
K562 Cell Block	Membranous staining of cultured cells.	Highly consistent and reproducible; readily available.	Lacks the tissue architecture of in vivo samples.

## Negative Controls for CD235a: Verifying Staining Specificity

Negative controls are crucial for ensuring that the observed staining is specific to the **CD235a** antigen and not a result of non-specific antibody binding or other artifacts.

### Recommended Negative Control Tissues:

The specificity of **CD235a** to the erythroid lineage means that most non-hematopoietic tissues can serve as negative controls. The key is to select tissues that are definitively devoid of erythroid cells.

- **Liver:** The parenchymal cells (hepatocytes) of the liver do not express **CD235a** and provide a clear negative internal control. However, it is important to note that sinusoids within the liver will contain erythrocytes, which will stain positive.
- **Brain:** Nervous tissue is an excellent negative control as it lacks erythroid cells.
- **Kidney:** The epithelial cells of the renal tubules and glomeruli are negative for **CD235a**.

### Internal Negative Controls:

In many tissue sections, particularly bone marrow, non-erythroid cells such as myeloid and lymphoid precursors, as well as stromal cells, will be present. These cells should not stain for **CD235a** and can serve as valuable internal negative controls within the same tissue section.

Table 2: Comparison of Negative Control Performance for **CD235a** IHC

Control Tissue	Expected Staining Pattern	Advantages	Disadvantages
Liver	No staining in hepatocytes; positive staining of erythrocytes in sinusoids.	Provides both negative (hepatocytes) and internal positive (erythrocytes) controls.	The presence of positive cells requires careful interpretation of the negative areas.
Brain	No staining in neural and glial cells.	Homogenously negative tissue provides a clear background.	Lacks internal positive controls.
Kidney	No staining in renal tubules and glomeruli.	Clear negative staining in parenchymal structures.	Erythrocytes may be present in blood vessels.
Internal Controls (e.g., in Bone Marrow)	No staining in non-erythroid hematopoietic cells and stroma.	Provides the most relevant background control within the tissue of interest.	Requires careful morphological identification of cell types.

## Alternative Markers for Erythroid Lineage Identification

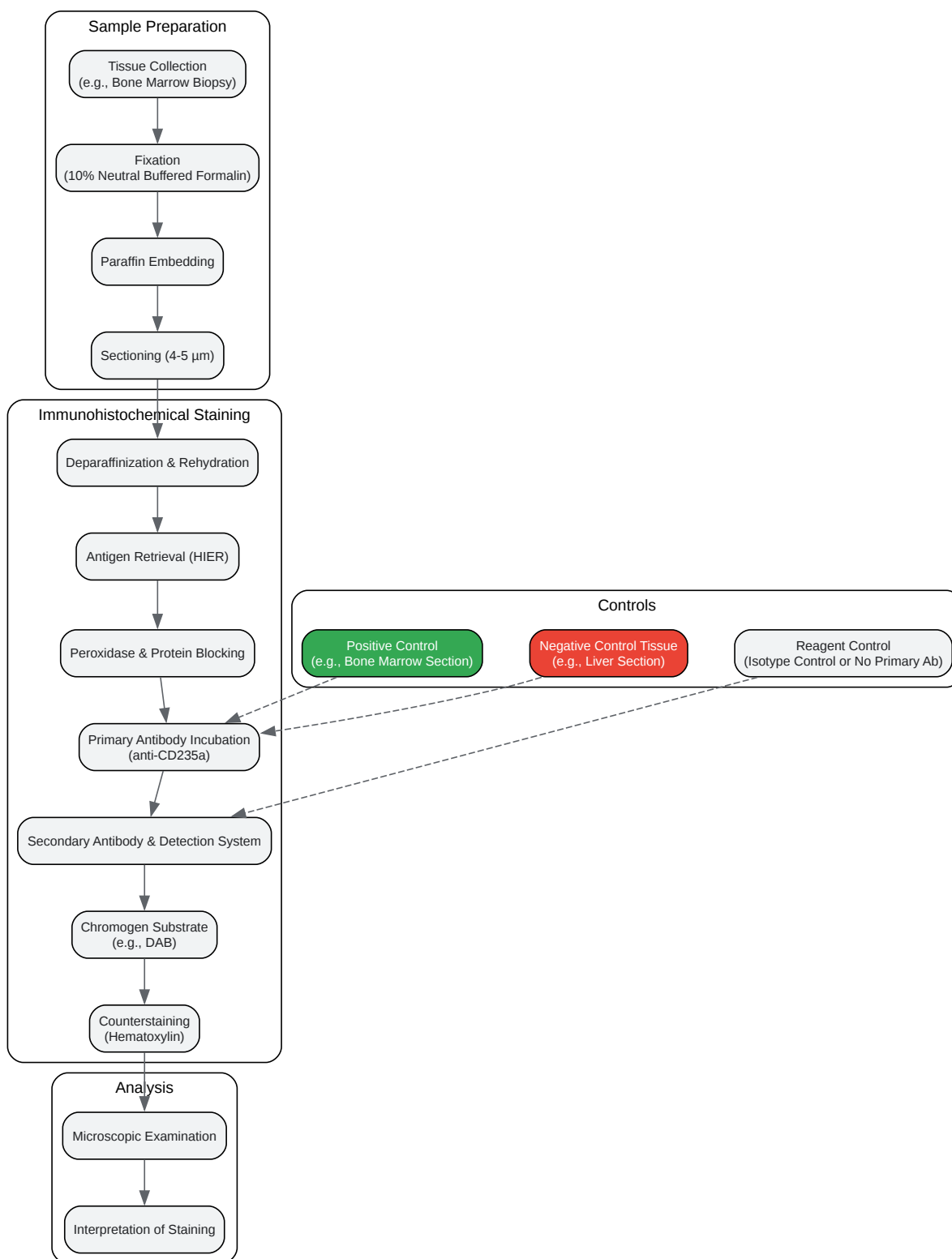
While **CD235a** is a robust marker, a multi-marker approach can provide a more comprehensive characterization of erythropoiesis.

Table 3: Comparison of **CD235a** with Alternative Erythroid Markers

Marker	Cellular Localization	Expression During Erythropoiesis	Advantages over CD235a	Disadvantages
CD71 (Transferrin Receptor)	Cell Membrane	Highly expressed on early erythroid precursors, expression decreases with maturation.	Excellent for identifying immature erythroid precursors.[4]	Not specific to erythroid lineage; expressed on other proliferating cells.
Spectrin	Cytoplasmic	Present in both early and late erythroblasts.	May be a superior marker for identifying early erythroid precursors in paraffin sections compared to Glycophorin A.[5]	Cytoplasmic staining can sometimes be diffuse.
Hemoglobin A	Cytoplasmic	Expressed in intermediate to late erythroid precursors.	Specific for more mature erythroid cells.	Does not stain early erythroid precursors.[3]
ALDH (Aldehyde Dehydrogenase)	Cytoplasmic	Intense staining in immature erythroblasts.	Highlights immature erythroid precursors.[6]	May show weak staining in some non-erythroid blasts.
CA I (Carbonic Anhydrase I)	Cytoplasmic	Stronger staining in more mature erythroid precursors.	Useful for identifying later stages of erythroid maturation.[6]	Weaker staining in immature erythroblasts.
CD2AP (CD2-associated protein)	Cytoplasmic	Stronger staining in more mature erythroid precursors.	Highlights later-stage erythroid cells.[6]	Weak to negative staining in immature erythroblasts.

## Experimental Workflow and Control Strategy

A well-defined experimental workflow incorporating appropriate controls is essential for reliable IHC results.

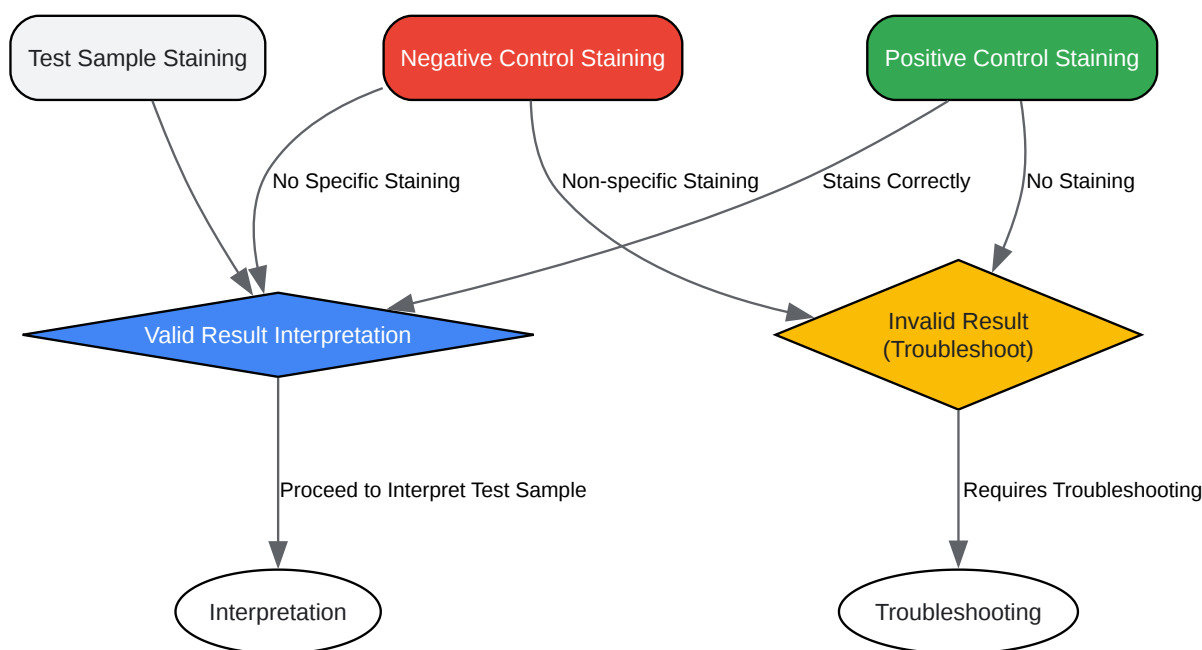


[Click to download full resolution via product page](#)

Caption: A typical workflow for **CD235a** immunohistochemistry, highlighting the integration of control samples.

## Logical Relationship of Controls in IHC

The interpretation of IHC results relies on a logical assessment of the staining patterns observed in the test and control samples.



[Click to download full resolution via product page](#)

### Need Custom Synthesis?

BenchChem offers custom synthesis for rare earth carbides and specific isotopic labeling.

Email: [info@benchchem.com](mailto:info@benchchem.com) or [Request Quote Online](#).

## References

- 1. Immune Transcriptome Study of Human Nucleated Erythroid Cells from Different Tissues by Single-Cell RNA-Sequencing - PMC [pmc.ncbi.nlm.nih.gov]
- 2. beckman.com [beckman.com]



- 3. researchgate.net [researchgate.net]
- 4. researchgate.net [researchgate.net]
- 5. Immunohistochemical identification of erythroid precursors in paraffin embedded bone marrow sections: spectrin is a superior marker to glycophorin - PMC [pmc.ncbi.nlm.nih.gov]
- 6. academic.oup.com [academic.oup.com]
- To cite this document: BenchChem. [A Researcher's Guide to Positive and Negative Controls for CD235a Immunohistochemistry]. BenchChem, [2025]. [Online PDF]. Available at: [https://www.benchchem.com/product/b12299716#positive-and-negative-controls-for-cd235a-immunohistochemistry]

---

### Disclaimer & Data Validity:

The information provided in this document is for Research Use Only (RUO) and is strictly not intended for diagnostic or therapeutic procedures. While BenchChem strives to provide accurate protocols, we make no warranties, express or implied, regarding the fitness of this product for every specific experimental setup.

**Technical Support:** The protocols provided are for reference purposes. Unsure if this reagent suits your experiment? [[Contact our Ph.D. Support Team for a compatibility check](#)]

**Need Industrial/Bulk Grade?** [Request Custom Synthesis Quote](#)

## BenchChem

Our mission is to be the trusted global source of essential and advanced chemicals, empowering scientists and researchers to drive progress in science and industry.

### Contact

Address: 3281 E Guasti Rd  
Ontario, CA 91761, United States  
Phone: (601) 213-4426  
Email: [info@benchchem.com](mailto:info@benchchem.com)