

A Comparative Study of Pyomyositis in Tropical and Temperate Climates

Author: BenchChem Technical Support Team. **Date:** December 2025

Compound of Interest

Compound Name: *Piomy*

Cat. No.: *B1172056*

[Get Quote](#)

For Researchers, Scientists, and Drug Development Professionals

Pyomyositis, a primary bacterial infection of skeletal muscle, presents with distinct epidemiological and clinical characteristics that vary significantly between tropical and temperate regions. Traditionally considered a disease of the tropics, its incidence is rising in temperate climates, often with different patient profiles and predisposing factors. This guide provides an objective comparison of pyomyositis in these two distinct climatic settings, supported by experimental data and detailed methodologies.

Epidemiological and Clinical Comparison

The following tables summarize the key differences in the epidemiology, causative organisms, clinical presentation, and laboratory findings of pyomyositis in tropical versus temperate climates.

Table 1: Epidemiological Comparison

Feature	Tropical Climates	Temperate Climates
Typical Patient Profile	Healthy, active children and young adults (10-40 years)[1]	Often immunocompromised or with underlying debilitating conditions[2]
Incidence	Accounts for 1-4% of hospital admissions in some regions[3]	Lower, but increasing; one study in Australia estimated 0.5 cases per 100,000 person-years[4]
Male-to-Female Ratio	1.5:1[1][5]	Varies, with some studies showing a male predominance[4]
Common Predisposing Factors	Minor trauma, nutritional deficiencies, parasitic and viral infections[1]	HIV/AIDS, diabetes mellitus, malignancy, intravenous drug use, chronic kidney disease[2][6]

Table 2: Causative Organisms

Organism	Tropical Climates (Approximate Prevalence)	Temperate Climates (Approximate Prevalence)
Staphylococcus aureus	~90% [1] [5]	~75% [5]
Methicillin-Resistant S. aureus (MRSA)	Increasing prevalence	A significant and increasing cause
Streptococcus pyogenes (Group A Strep)	1-5% [1] [5]	A common causative agent [7]
Other Streptococci (Groups B, C, G)	Less common [1] [5]	Implicated in some cases
Gram-negative bacilli	Less common [1] [5]	More frequent in immunocompromised patients
Haemophilus influenzae	Rare [1] [5]	Rare
Pneumococcus	Rare [1] [5]	Rare

Table 3: Clinical Presentation

Feature	Tropical Climates	Temperate Climates
Onset	Often insidious	Can be acute or subacute
Commonly Affected Muscles	Large muscle groups: quadriceps, gluteals, iliopsoas, pectoralis major [5] [8]	Similar to tropical climates: pelvic and leg muscles are most affected [7]
Clinical Stages	Classically described in three stages: 1. Invasive (diffuse pain, low-grade fever) 2. Suppurative (abscess formation, high fever) 3. Late (septicemia, metastatic abscesses)	Progression through stages is also observed
Mortality Rate	0.5% to 2% [5]	Can be up to 10% [1]

Table 4: Laboratory Findings

Parameter	Tropical Climates	Temperate Climates
White Blood Cell Count	Often shows moderate leukocytosis with a left shift[9]	Leukocytosis is a common finding[10]
Erythrocyte Sedimentation Rate (ESR)	Typically elevated[1]	Elevated[10]
C-Reactive Protein (CRP)	Typically elevated[1]	Elevated[9]
Muscle Enzymes (CK, Aldolase)	Usually normal or slightly elevated[1]	Often normal or only mildly elevated[11]
Blood Cultures	Positive in less than 5% of cases[10]	Positive in 5-35% of cases[11]
Pus Culture from Abscess	Gold standard for diagnosis; may be sterile in 15-30% of cases[5][10]	Gold standard for diagnosis[10]

Experimental Protocols

Accurate diagnosis and characterization of pyomyositis rely on standardized experimental procedures. The following are detailed methodologies for key diagnostic tests.

Protocol for Diagnostic Musculoskeletal Ultrasound

- **Patient Positioning:** Position the patient to allow for optimal access to the muscle group of interest. For extremity evaluations, this may involve supine, prone, or decubitus positioning.
- **Transducer Selection:** Utilize a high-frequency linear array transducer (typically 7-12 MHz or higher) for optimal resolution of superficial and intermediate-depth muscle structures. A lower frequency curvilinear transducer may be necessary for deeper muscle groups.
- **Imaging Planes:** Obtain images in at least two orthogonal planes (longitudinal and transverse) of the affected muscle.
- **Grayscale Imaging:**

- Assess muscle echotexture for any focal or diffuse changes. Early pyomyositis may present as diffuse muscle edema with loss of the normal striated architecture.
- Look for hypoechoic or anechoic fluid collections, which may represent abscess formation. Note the size, shape, and internal characteristics of any collections.
- Doppler Imaging:
 - Apply color or power Doppler to assess for hyperemia in the affected muscle and surrounding tissues, which is indicative of inflammation.
 - Evaluate for the absence of flow within a fluid collection, which is characteristic of an abscess.
- Comparative Imaging: Whenever possible, perform a comparative scan of the contralateral asymptomatic muscle to aid in the identification of subtle abnormalities.
- Image Documentation: Document all findings with representative static images and video clips.

Protocol for Magnetic Resonance Imaging (MRI) of Soft Tissue Infection

- Patient Preparation: Ensure the patient has no contraindications to MRI (e.g., certain metallic implants, pacemakers).
- Coil Selection: Use a surface coil appropriate for the anatomical region being imaged to maximize the signal-to-noise ratio.
- Imaging Sequences: A standard protocol for suspected pyomyositis should include:
 - T1-weighted sequences (axial): Provide excellent anatomical detail of the muscle and surrounding structures.
 - T2-weighted fat-suppressed or Short Tau Inversion Recovery (STIR) sequences (axial and coronal/sagittal): Highly sensitive for detecting fluid and edema within the muscle and soft tissues. Pyomyositis will appear as high signal intensity.

- Post-contrast T1-weighted fat-suppressed sequences (axial and coronal/sagittal):
Administer a gadolinium-based contrast agent intravenously. This is crucial for identifying and delineating abscesses, which will typically demonstrate peripheral rim enhancement.
- Image Interpretation:
 - Early Stage: Look for diffuse muscle enlargement and increased signal intensity on T2-weighted/STIR images, consistent with myositis.
 - Suppurative Stage: Identify discrete, rim-enhancing fluid collections on post-contrast T1-weighted images, confirming the presence of an abscess.
 - Assess for Complications: Evaluate for extension of the infection to adjacent structures, such as bone (osteomyelitis) or joints (septic arthritis).

Protocol for Bacterial Culture of Pus from Muscle Abscess

- Specimen Collection:
 - Aseptically prepare the skin overlying the abscess.
 - Aspirate pus from the abscess using a sterile needle and syringe. Whenever possible, a sample of the abscess wall should also be obtained.
 - If the volume of aspirate is small, a small amount of sterile, non-bacteriostatic saline can be drawn into the syringe and flushed to recover the specimen.
- Specimen Transport:
 - Transfer the aspirated pus into a sterile, leak-proof container.
 - Transport the specimen to the microbiology laboratory immediately. If a delay is anticipated, the sample should be refrigerated.
- Laboratory Processing:

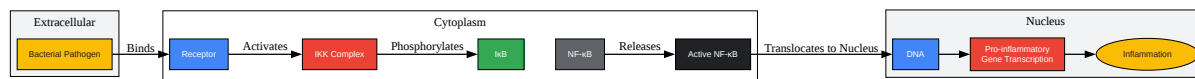
- Gram Stain: Perform a Gram stain on a smear of the pus to provide a rapid, preliminary identification of the bacterial morphology (e.g., Gram-positive cocci in clusters, suggestive of *Staphylococcus*).
- Aerobic Culture: Inoculate the specimen onto appropriate culture media, such as blood agar and MacConkey agar. Incubate at 35-37°C in an aerobic atmosphere.
- Anaerobic Culture: If an anaerobic infection is suspected, inoculate the specimen onto appropriate anaerobic media and incubate in an anaerobic environment.
- Organism Identification and Susceptibility Testing:
 - Identify any bacterial growth based on colony morphology, Gram stain, and biochemical tests.
 - Perform antimicrobial susceptibility testing on the isolated pathogen(s) to guide targeted antibiotic therapy.

Signaling Pathways and Pathophysiology

The pathogenesis of pyomyositis is thought to involve the hematogenous seeding of bacteria into a site of pre-existing muscle injury. The subsequent inflammatory response is mediated by complex signaling pathways.

NF-κB Signaling in Muscle Inflammation

The Nuclear Factor-kappa B (NF-κB) signaling pathway is a central regulator of inflammation. In the context of bacterial infection in muscle, bacterial components can trigger a cascade that leads to the activation of NF-κB, resulting in the transcription of pro-inflammatory cytokines and chemokines. This contributes to the recruitment of immune cells to the site of infection and the propagation of the inflammatory response.

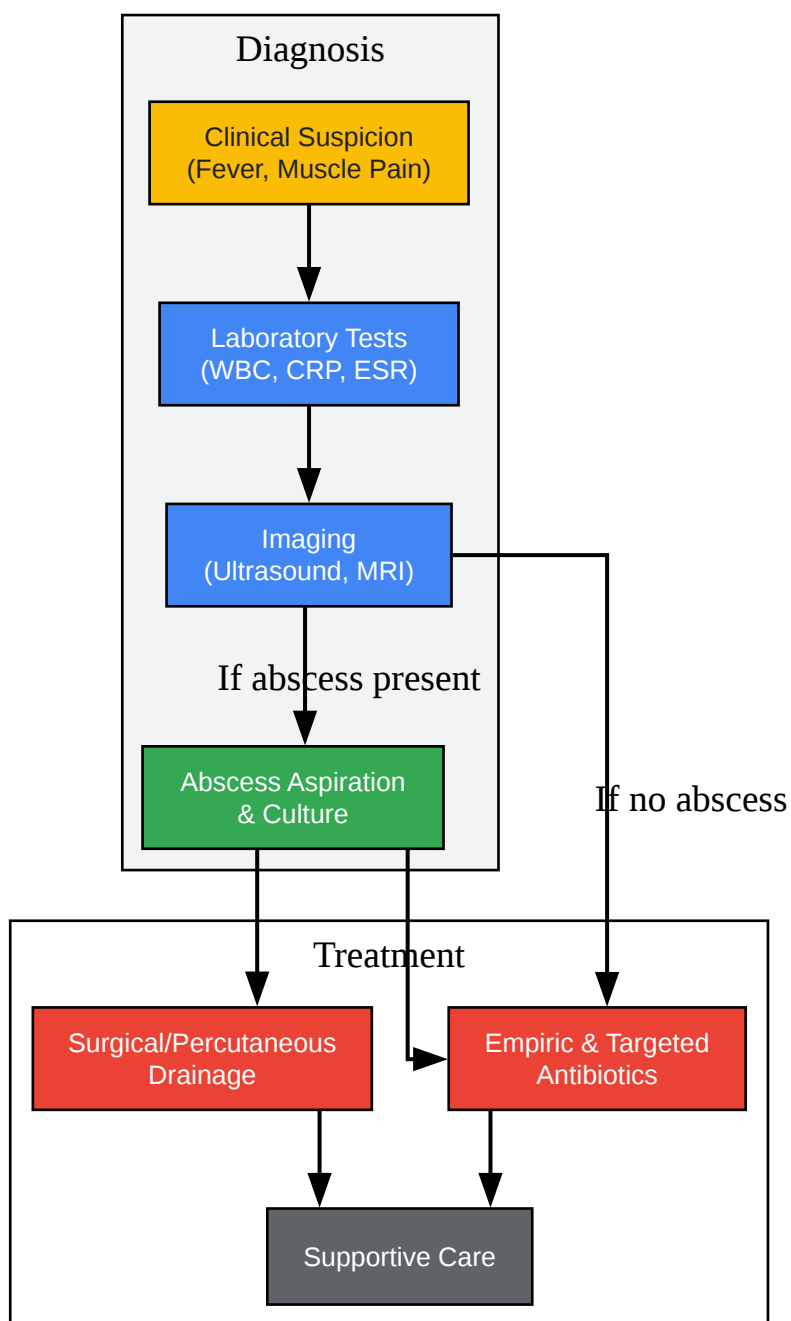


[Click to download full resolution via product page](#)

NF-κB signaling pathway in bacterial muscle infection.

Diagnostic and Treatment Workflow

The diagnosis and management of pyomyositis follow a logical workflow, which can be influenced by the clinical setting (tropical vs. temperate).



[Click to download full resolution via product page](#)

General diagnostic and treatment workflow for pyomyositis.

Need Custom Synthesis?

BenchChem offers custom synthesis for rare earth carbides and specific isotopic labeling.

Email: info@benchchem.com or [Request Quote Online](#).

References

- 1. dermnetnz.org [dermnetnz.org]
- 2. Tropical and temperate pyomyositis - PubMed [pubmed.ncbi.nlm.nih.gov]
- 3. clinmedjournals.org [clinmedjournals.org]
- 4. Staphylococcal pyomyositis in a temperate region: epidemiology and modern management | The Medical Journal of Australia [mja.com.au]
- 5. Tropical Pyomyositis - PMC [pmc.ncbi.nlm.nih.gov]
- 6. Pyomyositis in the United States 2002-2014 - PubMed [pubmed.ncbi.nlm.nih.gov]
- 7. Clinical Characteristics and Management of Children and Adolescents Hospitalized With Pyomyositis - PMC [pmc.ncbi.nlm.nih.gov]
- 8. Tropical pyomyositis (myositis tropicans): current perspective - PubMed [pubmed.ncbi.nlm.nih.gov]
- 9. Pyomyositis is not only a tropical pathology: a case series - PMC [pmc.ncbi.nlm.nih.gov]
- 10. An Unresolving Case of Pyomyositis: A Case Report - PMC [pmc.ncbi.nlm.nih.gov]
- 11. Primary bacterial intercostal pyomyositis diagnosis: A case report - PMC [pmc.ncbi.nlm.nih.gov]
- To cite this document: BenchChem. [A Comparative Study of Pyomyositis in Tropical and Temperate Climates]. BenchChem, [2025]. [Online PDF]. Available at: [https://www.benchchem.com/product/b1172056#a-comparative-study-of-pyomyositis-in-tropical-and-temperate-climates]

Disclaimer & Data Validity:

The information provided in this document is for Research Use Only (RUO) and is strictly not intended for diagnostic or therapeutic procedures. While BenchChem strives to provide accurate protocols, we make no warranties, express or implied, regarding the fitness of this product for every specific experimental setup.

Technical Support: The protocols provided are for reference purposes. Unsure if this reagent suits your experiment? [[Contact our Ph.D. Support Team for a compatibility check](#)]

Need Industrial/Bulk Grade? [Request Custom Synthesis Quote](#)

BenchChem

Our mission is to be the trusted global source of essential and advanced chemicals, empowering scientists and researchers to drive progress in science and industry.

Contact

Address: 3281 E Guasti Rd

Ontario, CA 91761, United States

Phone: (601) 213-4426

Email: info@benchchem.com