

A Comparative Guide to Transvaginal Sonography and Hysteroscopy in Infertility Investigations

Author: BenchChem Technical Support Team. **Date:** December 2025

Compound of Interest

Compound Name: FR 76830

Cat. No.: B1674034

[Get Quote](#)

The evaluation of the uterine cavity is a cornerstone in the diagnostic workup of female infertility. Uterine abnormalities, whether congenital or acquired, are implicated as a causal factor in a significant percentage of infertile couples. Transvaginal Sonography (TVS) and hysteroscopy are the two primary modalities for assessing the integrity of the endometrial cavity. While TVS offers a non-invasive initial assessment, hysteroscopy is widely regarded as the gold standard for both diagnosis and treatment of intrauterine pathologies.^{[1][2][3]} This guide provides an objective comparison of their diagnostic accuracy, supported by experimental data, to inform researchers and clinicians in the field of reproductive medicine.

Experimental Protocols and Methodologies

The data presented in this guide are derived from multiple cross-sectional and prospective observational studies involving infertile women. The general methodology across these studies follows a consistent protocol to compare the findings of TVS against the gold standard, hysteroscopy.

General Protocol:

- **Patient Population:** Studies typically enroll women of reproductive age with a history of primary or secondary infertility.^{[4][5][6]} Sample sizes in the cited studies range from under 100 to over 700 participants.^{[4][5][6]}

- **Timing of Procedures:** To ensure optimal visualization of the endometrium, both TVS and hysteroscopy are usually performed in the early to mid-follicular phase of the menstrual cycle, after the cessation of bleeding.[\[4\]](#)[\[6\]](#)
- **Transvaginal Sonography (TVS):** A high-frequency transvaginal ultrasound probe is used to systematically evaluate the uterus, endometrium, and adnexa.[\[7\]](#)[\[8\]](#) The assessment looks for structural abnormalities such as polyps, fibroids, congenital anomalies (e.g., septa), and signs of adhesions.[\[9\]](#) In some studies, 3D-TVS is employed to provide more detailed coronal views of the uterus.[\[6\]](#)
- **Hysteroscopy:** This procedure is performed by inserting a thin, lighted telescope (hysteroscope) through the cervix to directly visualize the uterine cavity.[\[1\]](#)[\[3\]](#) The cavity is distended, typically with saline, to allow for thorough inspection.[\[1\]](#) It is considered the gold standard because it allows for direct visual confirmation of pathologies.[\[1\]](#)[\[2\]](#)[\[10\]](#)
- **Data Analysis:** The findings from TVS are compared to the findings from hysteroscopy. The diagnostic accuracy of TVS is calculated in terms of sensitivity, specificity, positive predictive value (PPV), and negative predictive value (NPV).[\[4\]](#)[\[5\]](#) In many cases, a definitive diagnosis is confirmed by histopathology of tissue obtained via biopsy or resection during hysteroscopy.[\[5\]](#)[\[11\]](#)

Data Presentation: Diagnostic Accuracy of TVS

Transvaginal sonography is a valuable, non-invasive screening tool, but its accuracy varies depending on the specific type of intrauterine pathology. Hysteroscopy remains the definitive diagnostic procedure.[\[4\]](#)[\[12\]](#) The following table summarizes the diagnostic performance of TVS in detecting various uterine abnormalities in infertile women, with hysteroscopy serving as the reference standard.

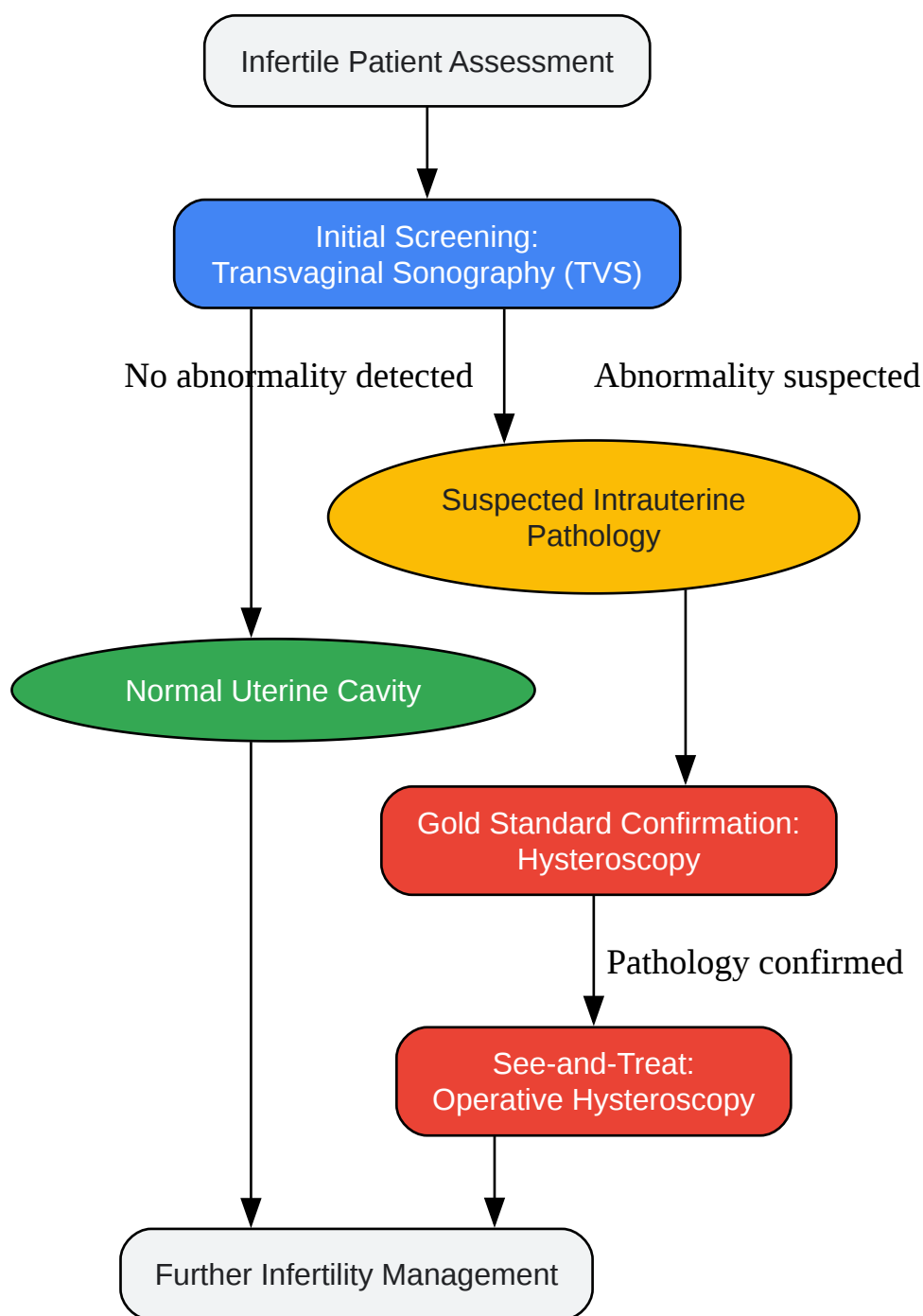
Uterine Abnormality	Sensitivity	Specificity	Positive Predictive Value (PPV)	Negative Predictive Value (NPV)	Source(s)
Overall					
Intrauterine Pathology	79% - 84.5%	82% - 98.7%	84% - 98.0%	71% - 89.2%	[4] [5]
Endometrial Polyps	60% - 88.3%	82.9% - 91.5%	81.6%	94.6%	[4] [6] [13]
Submucous Myomas (Fibroids)	89.2% - 100%	92.3% - 99.6%	92.5%	-	[4] [13]
Uterine Septum	67% - 90.9%	99.8% - 100%	98.3%	-	[4]
Intrauterine Adhesions	35%	-	57.1%	-	[4]

Data compiled from multiple studies. Ranges reflect findings from different research cohorts and methodologies.

The data indicates that TVS demonstrates high accuracy, particularly in specificity, for diagnosing submucous fibroids and uterine septa.[\[4\]](#) However, its sensitivity can be lower for other conditions, most notably for intrauterine adhesions, where direct visualization via hysteroscopy is superior.[\[4\]](#)[\[10\]](#) While TVS is effective for initial screening, these findings underscore the role of hysteroscopy for definitive diagnosis and to avoid misdiagnosis.[\[5\]](#)[\[14\]](#)

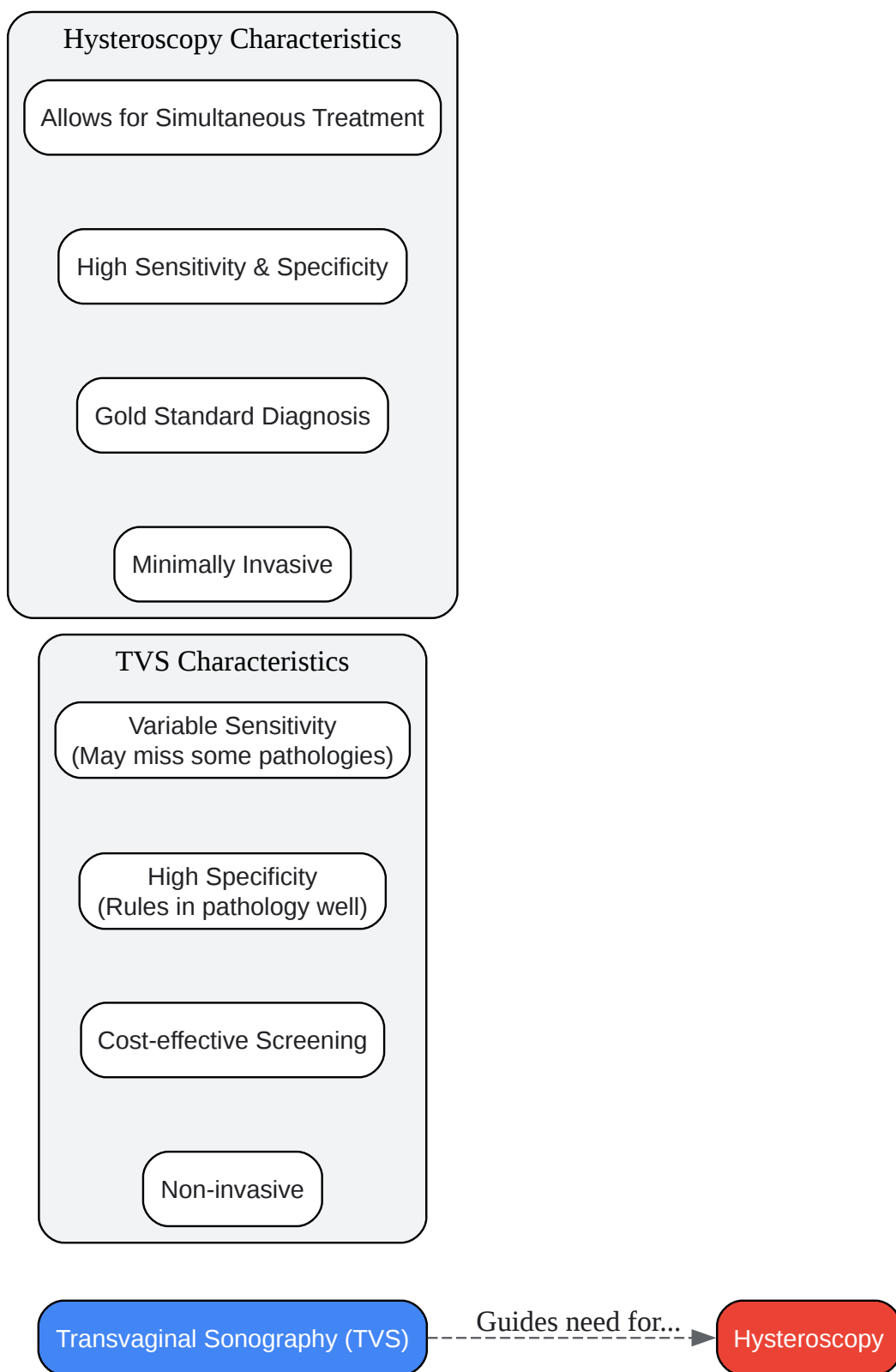
Visualizing the Diagnostic Workflow

To better understand the clinical application and logical relationship between these two procedures, the following diagrams illustrate the investigative workflow and a comparison of their diagnostic roles.



[Click to download full resolution via product page](#)

Caption: Workflow for uterine cavity assessment in infertility.



[Click to download full resolution via product page](#)

Caption: Comparative characteristics of TVS and Hysteroscopy.

Objective Comparison

Transvaginal Sonography (TVS): As a non-invasive and widely accessible imaging modality, TVS is an excellent first-line tool in the evaluation of female infertility.[7][8] Its primary advantages are its safety, patient comfort, and cost-effectiveness. The data show that TVS is particularly proficient at identifying structural abnormalities like submucous fibroids and uterine septa, often with high specificity.[4] This makes it valuable for "ruling in" a suspected diagnosis. However, its sensitivity is operator-dependent and can be limited in detecting more subtle pathologies such as small polyps, mild adhesions, or chronic endometritis.[4][10] A normal finding on TVS does not entirely exclude the presence of intrauterine abnormalities.

Hysteroscopy: Hysteroscopy is considered the gold standard for evaluating the uterine cavity for good reason.[1][3] By providing direct visualization, it offers the highest diagnostic accuracy, with superior sensitivity for detecting subtle lesions that may be missed by TVS.[10][11] Its most significant advantage is the "see and treat" capability, which allows for the diagnosis and immediate surgical correction of pathologies like polyps, adhesions, and septa in a single procedure.[5][15] While it is a minimally invasive surgical procedure and more costly than TVS, its definitive diagnostic and therapeutic capabilities often make it an indispensable tool, especially in cases of recurrent implantation failure or when abnormalities are suspected on TVS.[5][10]

Conclusion

In the context of infertility investigation, transvaginal sonography and hysteroscopy are not competing but rather complementary procedures. TVS serves as an essential, non-invasive screening method that can accurately identify many significant uterine pathologies and guide further management.[4][9] Hysteroscopy remains the undisputed gold standard for a definitive diagnosis and offers the invaluable advantage of immediate treatment.[2][3] The strategic use of TVS for initial assessment allows for the judicious application of hysteroscopy, ensuring that patients who require intervention receive it promptly, thereby optimizing the diagnostic pathway and potentially improving reproductive outcomes.

Need Custom Synthesis?

BenchChem offers custom synthesis for rare earth carbides and specific isotopic labeling.

Email: info@benchchem.com or [Request Quote Online](#).

References

- 1. Hysteroscopy - StatPearls - NCBI Bookshelf [ncbi.nlm.nih.gov]
- 2. ajmsjournal.info [ajmsjournal.info]
- 3. draksoyivf.com [draksoyivf.com]
- 4. Diagnostic Accuracy of Transvaginal Sonography in the Detection of Uterine Abnormalities in Infertile Women - PMC [pmc.ncbi.nlm.nih.gov]
- 5. Uterine cavity assessment in infertile women: comparison of transvaginal sonography and hysteroscopy - PubMed [pubmed.ncbi.nlm.nih.gov]
- 6. Diagnostic accuracy of 3D-transvaginal ultrasound in detecting uterine cavity abnormalities in infertile patients as compared with hysteroscopy - PubMed [pubmed.ncbi.nlm.nih.gov]
- 7. dsjuog.com [dsjuog.com]
- 8. Role of Transvaginal Sonography in the Diagnosis of Female Infertility: A Comprehensive Review - PubMed [pubmed.ncbi.nlm.nih.gov]
- 9. Use of Trans-Vaginal Ultrasound to Diagnose and Treat Infertility and Its Performance [scirp.org]
- 10. karger.com [karger.com]
- 11. Comparison of transvaginal ultrasonography and hysteroscopy in the diagnosis of uterine pathologies - PMC [pmc.ncbi.nlm.nih.gov]
- 12. journal.unisza.edu.my [journal.unisza.edu.my]
- 13. file.sdiarticle3.com [file.sdiarticle3.com]
- 14. researchgate.net [researchgate.net]
- 15. Hysterolaparoscopy: A Gold Standard for Diagnosing and Treating Infertility and Benign Uterine Pathology - PMC [pmc.ncbi.nlm.nih.gov]
- To cite this document: BenchChem. [A Comparative Guide to Transvaginal Sonography and Hysteroscopy in Infertility Investigations]. BenchChem, [2025]. [Online PDF]. Available at: [https://www.benchchem.com/product/b1674034#accuracy-of-transvaginal-sonography-compared-to-hysteroscopy-for-infertility-investigation]

Disclaimer & Data Validity:

The information provided in this document is for Research Use Only (RUO) and is strictly not intended for diagnostic or therapeutic procedures. While BenchChem strives to provide accurate protocols, we make no warranties, express or implied, regarding the fitness of this product for every specific experimental setup.

Technical Support: The protocols provided are for reference purposes. Unsure if this reagent suits your experiment? [[Contact our Ph.D. Support Team for a compatibility check](#)]

Need Industrial/Bulk Grade? [Request Custom Synthesis Quote](#)

BenchChem

Our mission is to be the trusted global source of essential and advanced chemicals, empowering scientists and researchers to drive progress in science and industry.

Contact

Address: 3281 E Guasti Rd
Ontario, CA 91761, United States
Phone: (601) 213-4426
Email: info@benchchem.com