

A Comparative Guide to Iodamide CT Angiography and Magnetic Resonance Angiography

Author: BenchChem Technical Support Team. **Date:** December 2025

Compound of Interest

Compound Name: Iodamide

Cat. No.: B1672015

[Get Quote](#)

This guide provides a comprehensive comparison of **iodamide**-enhanced Computed Tomography Angiography (CTA) and gadolinium-enhanced Magnetic Resonance Angiography (MRA) for vascular imaging. The information is intended for researchers, scientists, and drug development professionals to facilitate an objective evaluation of these two prominent imaging modalities.

Mechanism of Action

The fundamental principles behind CTA and MRA contrast enhancement differ significantly. **Iodamide**, an iodinated contrast agent used in CTA, enhances the visibility of blood vessels by attenuating X-rays. Due to the high atomic number of iodine, the contrast-filled vessels appear denser than the surrounding tissues on a CT scan.

In contrast, MRA utilizes gadolinium-based contrast agents that are paramagnetic. These agents shorten the T1 relaxation time of protons in the blood, leading to a stronger signal and brighter appearance of the blood vessels on T1-weighted MR images.

Quantitative Performance Data

The diagnostic accuracy of CTA and MRA has been evaluated in numerous studies across various vascular territories. The following tables summarize key performance metrics from comparative studies. It is important to note that while the user specified "**iodamide**," the

available literature often refers more broadly to "iodinated" contrast agents. **Iodamide** is a type of non-ionic, iodinated contrast medium.

Table 1: Diagnosis of Carotid Artery Stenosis

Modality	Sensitivity	Specificity	Reference
CTA	85% - 100%	93% - 97%	[1] [2]
MRA	88% - 94%	97% - 98%	[3]

Table 2: Diagnosis of Peripheral Artery Disease

Modality	Accuracy (Aorto-iliac)	Accuracy (Femoro- popliteal)	Accuracy (Infrapopliteal)	Reference
CTA	92%	94%	96%	[4]
MRA	92%	90%	90%	[4]

Table 3: Diagnosis of Aortic Dissection

Modality	Sensitivity	Specificity	Reference
CTA	98% - 100%	98% - 100%	[5]
MRA	90% - 100%	100%	[5]

Table 4: Detection of Thoracic Aortic Aneurysm

Modality	Accuracy (Ascending Aorta)	Accuracy (Descending Aorta)	Reference
CTA	88% - 90%	81% - 82%	[6]
MRA	Becoming the preferred modality for follow-up due to lack of ionizing radiation.[7]		

Experimental Protocols

Detailed methodologies are crucial for the replication and validation of experimental findings. Below are representative protocols for **iodamide** CTA and gadolinium-enhanced MRA for the evaluation of carotid artery stenosis.

Iodamide CT Angiography Protocol

A typical experimental protocol for CTA of the carotid arteries involves the following steps:

- **Patient Preparation:** Patients are positioned supine on the CT scanner table. An intravenous (IV) line, typically 18-20 gauge, is inserted into an antecubital vein.
- **Non-Contrast Scan:** A preliminary non-contrast scan of the neck is often performed to identify calcifications that could interfere with the interpretation of the angiogram.[8]
- **Contrast Administration:** A non-ionic, iodinated contrast agent such as **iodamide** (e.g., 350 mgI/mL) is injected at a rate of 3-4 mL/sec.[1] The total volume is typically weight-based.
- **Bolus Tracking:** A bolus tracking technique is employed to time the image acquisition with the peak arterial enhancement. A region of interest (ROI) is placed in the aortic arch, and scanning commences once the enhancement reaches a predefined threshold (e.g., 100-150 Hounsfield Units).
- **Image Acquisition:** A helical scan is performed from the aortic arch to the skull base.[1] Typical acquisition parameters include a 120 kVp tube voltage, 280-400 mA, and a slice collimation of 0.5-1.0 mm.[1]

- **Image Reconstruction and Analysis:** The raw data is reconstructed into thin axial slices. Post-processing techniques, including Maximum Intensity Projection (MIP) and 3D volume rendering, are used to visualize the carotid arteries and assess for stenosis.[\[9\]](#)[\[10\]](#)

Gadolinium-Enhanced MR Angiography Protocol

A standard protocol for contrast-enhanced MRA of the carotid arteries includes:

- **Patient Preparation:** The patient is positioned supine on the MRI table with a dedicated head and neck coil. An IV line is placed for contrast administration.
- **Localizer and Pre-Contrast Imaging:** Initial localizer scans are performed, followed by pre-contrast T1-weighted sequences.
- **Contrast Administration:** A gadolinium-based contrast agent is administered intravenously, typically at a dose of 0.1 mmol/kg body weight, followed by a saline flush.[\[11\]](#)
- **Image Acquisition:** A 3D gradient-echo pulse sequence is initiated timed to the arterial phase of the contrast bolus.[\[3\]](#) This can be achieved using a test bolus or automated bolus-tracking methods.
- **Image Post-Processing:** The acquired data is post-processed to generate MIP images and 3D reconstructions of the carotid arteries for evaluation.

Visualizations

Signaling Pathways

Figure 1. Contrast Agent Signaling Pathways

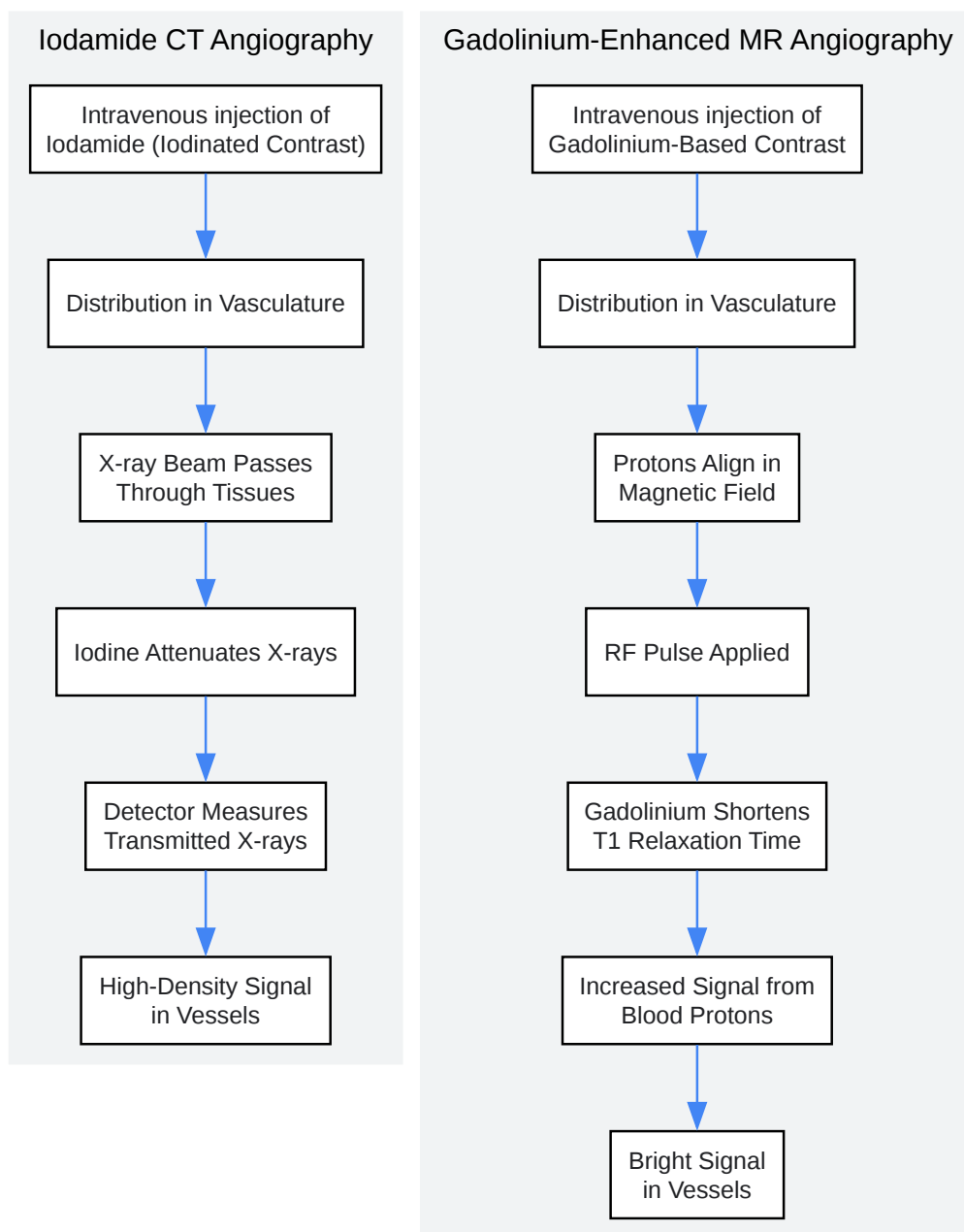
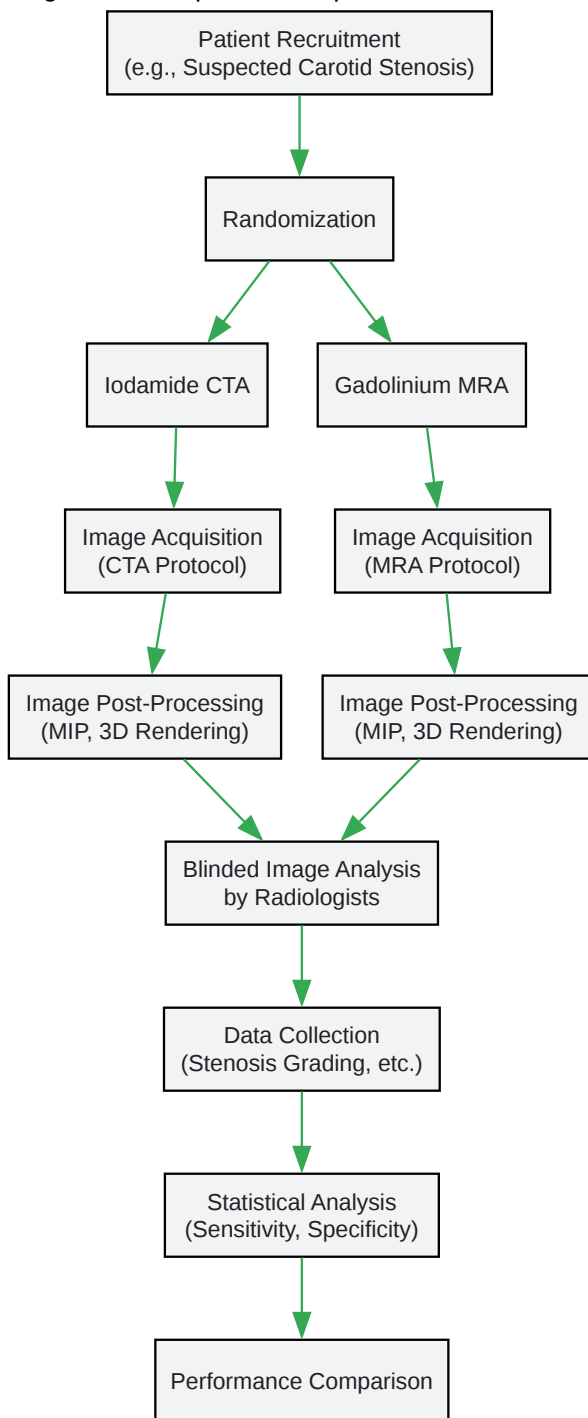
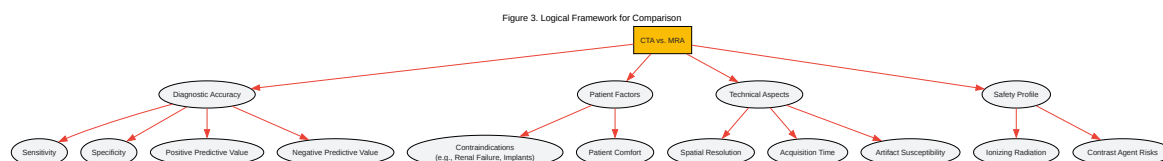


Figure 2. Comparative Experimental Workflow





[Click to download full resolution via product page](#)

Need Custom Synthesis?

BenchChem offers custom synthesis for rare earth carbides and specific isotopic labeling.

Email: info@benchchem.com or [Request Quote Online](#).

References

- 1. appliedradiology.com [appliedradiology.com]
- 2. Imaging Approaches and Challenges in the Assessment of Peripheral Artery Disease | Radiology Key [radiologykey.com]
- 3. Contrast-Enhanced MR Angiography of the Carotid and Vertebrobasilar Circulations - PMC [pmc.ncbi.nlm.nih.gov]
- 4. Comparison of CT and MR angiography in evaluation of peripheral arterial disease before endovascular intervention - PubMed [pubmed.ncbi.nlm.nih.gov]
- 5. droracle.ai [droracle.ai]

- 6. Quantification of the Thoracic Aorta and Detection of Aneurysm at CT: Development and Validation of a Fully Automatic Methodology - PMC [pmc.ncbi.nlm.nih.gov]
- 7. Aortic Volumetry at Contrast-enhanced MR Angiography: Feasibility as a Sensitive Method for Monitoring Bicuspid Aortic Valve Aortopathy - PMC [pmc.ncbi.nlm.nih.gov]
- 8. emedicine.medscape.com [emedicine.medscape.com]
- 9. Carotid artery stenosis: a prospective comparison of CT angiography and conventional angiography - PubMed [pubmed.ncbi.nlm.nih.gov]
- 10. ajronline.org [ajronline.org]
- 11. Dose optimization of contrast-enhanced carotid MR angiography - PubMed [pubmed.ncbi.nlm.nih.gov]
- To cite this document: BenchChem. [A Comparative Guide to Iodamide CT Angiography and Magnetic Resonance Angiography]. BenchChem, [2025]. [Online PDF]. Available at: [https://www.benchchem.com/product/b1672015#cross-validation-of-iodamide-ct-angiography-with-magnetic-resonance-angiography]

Disclaimer & Data Validity:

The information provided in this document is for Research Use Only (RUO) and is strictly not intended for diagnostic or therapeutic procedures. While BenchChem strives to provide accurate protocols, we make no warranties, express or implied, regarding the fitness of this product for every specific experimental setup.

Technical Support: The protocols provided are for reference purposes. Unsure if this reagent suits your experiment? [[Contact our Ph.D. Support Team for a compatibility check](#)]

Need Industrial/Bulk Grade? [Request Custom Synthesis Quote](#)

BenchChem

Our mission is to be the trusted global source of essential and advanced chemicals, empowering scientists and researchers to drive progress in science and industry.

Contact

Address: 3281 E Guasti Rd

Ontario, CA 91761, United States

Phone: (601) 213-4426

Email: info@benchchem.com