

# A Comparative Guide to Gallium-67 Imaging and Anatomical Modalities (MRI & CT)

**Author:** BenchChem Technical Support Team. **Date:** December 2025

## Compound of Interest

Compound Name: Gallium-67

Cat. No.: B084094

[Get Quote](#)

In the landscape of medical imaging, the convergence of functional and anatomical techniques provides a powerful diagnostic arsenal for researchers, scientists, and drug development professionals. This guide offers a comprehensive comparison of **Gallium-67** (Ga-67) scintigraphy, a functional imaging modality, with Magnetic Resonance Imaging (MRI) and Computed Tomography (CT), which provide anatomical detail. The cross-validation of these techniques is crucial for accurate disease staging, monitoring treatment response, and elucidating biological pathways.

## Quantitative Performance Analysis

The diagnostic accuracy of an imaging modality is paramount. The following tables summarize the performance metrics of Ga-67 imaging in comparison to MRI and CT in various clinical contexts, primarily focusing on lymphoma and infection, where Ga-67 has historically been most utilized.

Table 1: Performance in Mediastinal Hodgkin's Lymphoma Evaluation

Modality	Sensitivity	Specificity	Positive Predictive Value (PPV)	Accuracy	Reference
Gallium-67 Scan	85.7%	100%	100%	Not Reported	<a href="#">[1]</a>
MRI	92.8%	80.6%	68.4%	Not Reported	<a href="#">[1]</a>
Gallium-67 Scan	50.0%	88.5%	40.0%	83.3%	<a href="#">[2]</a>
MRI	75.0%	96.2%	75.0%	93.3%	<a href="#">[2]</a>
Gallium-67 Scan (at restaging)	Lower than CT and MR (90%)	Superior to CT, equivalent to MR (98%)	Not Reported	Not Reported	<a href="#">[3]</a> <a href="#">[4]</a>
CT (at restaging)	Higher than Ga-67 (96%)	Lower than Ga-67 and MR (45%)	Not Reported	Not Reported	<a href="#">[3]</a> <a href="#">[4]</a>
MRI (at restaging)	Highest (100%)	High (92%)	Not Reported	Not Reported	<a href="#">[3]</a> <a href="#">[4]</a>

Table 2: Performance in Infection Imaging

Modality	Sensitivity	Specificity	Accuracy	Reference
Gallium-67 Citrate Scintigraphy	81%	79%	Not Reported	[5]
Gallium-68 Citrate PET-CT	69%	67%	Not Reported	[5]
Gallium-67 Scan (Lymphoma Assessment)	80%	88%	Not Reported	[6]
Gallium-67 Scan (Infection Assessment)	80%	100%	Not Reported	[6]

Table 3: Performance in Head and Neck Tumor Differentiation

Modality	Mean Accuracy (before Ga-67)	Mean Accuracy (after Ga-67)	Reference
CT and/or MRI	70.7%	83.3%	[7]

## Experimental Protocols

Detailed methodologies are critical for the reproducibility and validation of experimental data. The following are generalized protocols for **Gallium-67** scintigraphy, MRI, and CT based on common clinical practices for lymphoma and infection imaging.

### Gallium-67 Scintigraphy Protocol

- Radiopharmaceutical: **Gallium-67** (Ga-67) citrate.[8][9]
- Dosage: For adults, typically 5 mCi (185 MBq) for infection imaging and up to 10 mCi (370 MBq) for tumor imaging, administered via intravenous injection.[8]

- Patient Preparation: A mild laxative may be prescribed to reduce bowel activity, which can interfere with image interpretation.[8]
- Imaging Timeline:
  - Initial images are typically acquired 24-48 hours post-injection.[8][10]
  - Delayed imaging at 72 hours, and sometimes later (up to 5 days), may be performed to allow for clearance of background activity and to differentiate infection or tumor from normal physiological uptake.[8][9]
- Instrumentation: A dual-head rotating gamma camera with a medium-energy collimator is preferred.[8] Energy windows are centered at approximately 93, 185, and 300 keV.[8]
- Image Acquisition:
  - Whole-body planar images (anterior and posterior views) are acquired.
  - Single-Photon Emission Computed Tomography (SPECT) or SPECT/CT of specific regions of interest can provide improved localization and anatomical correlation.[8][11]

## MRI Protocol for Lymphoma and Infection

- Patient Preparation: Patients should remove all metallic objects. A consent form is required, and for contrast-enhanced scans, renal function (GFR) should be assessed.[12]
- Positioning: The patient is positioned supine, head-first for head and neck studies, within the appropriate coil (e.g., head coil, body coil).[12]
- Core Sequences:
  - T1-weighted images: Provide excellent anatomical detail.
  - T2-weighted images: Sensitive for detecting edema and fluid, which are often associated with inflammation and malignancy. High signal intensity on T2-weighted images can be indicative of active disease.[2]

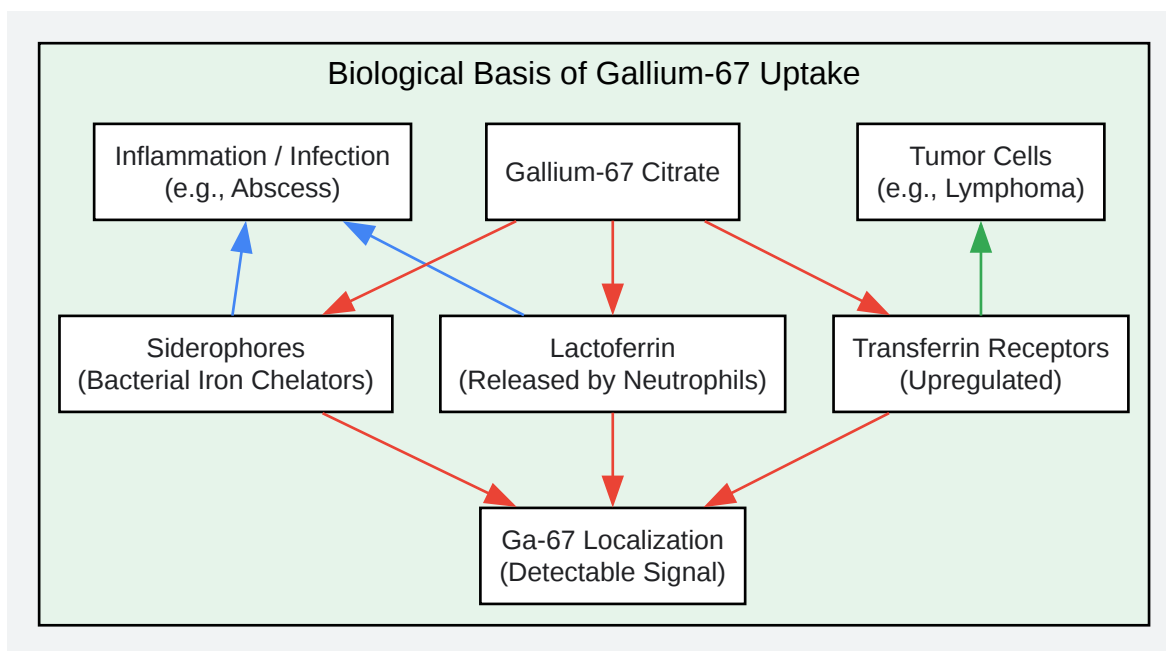
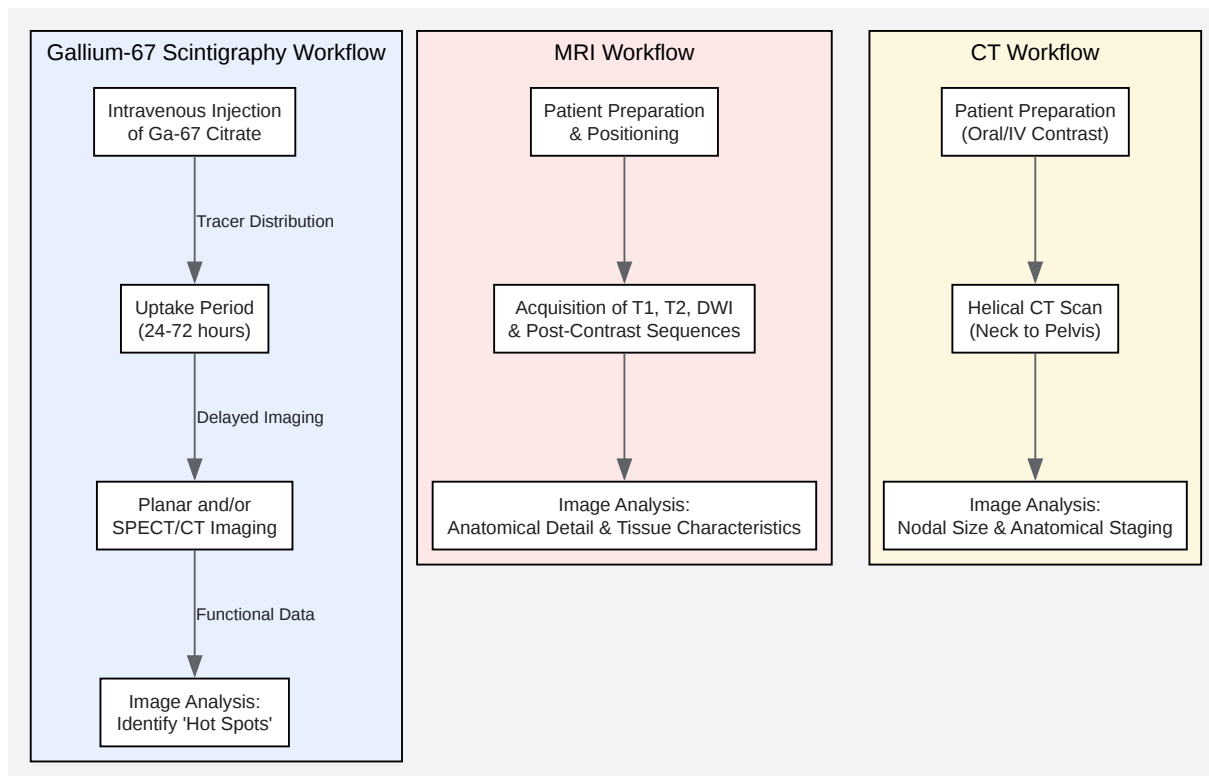
- Diffusion-Weighted Imaging (DWI): Measures the random motion of water molecules and is highly sensitive for detecting cellular tumors and abscesses, which appear as areas of restricted diffusion.[\[13\]](#)
- Post-Contrast T1-weighted images (with Gadolinium): Areas of inflammation or viable tumor typically show enhancement after the administration of a gadolinium-based contrast agent.
- Advanced Techniques (for infection):
  - MR Perfusion: Can help differentiate tumor from infection by assessing blood volume in the surrounding tissue.[\[13\]](#)
  - MR Spectroscopy: Can aid in distinguishing tumor from abscess by detecting specific metabolites.[\[13\]](#)

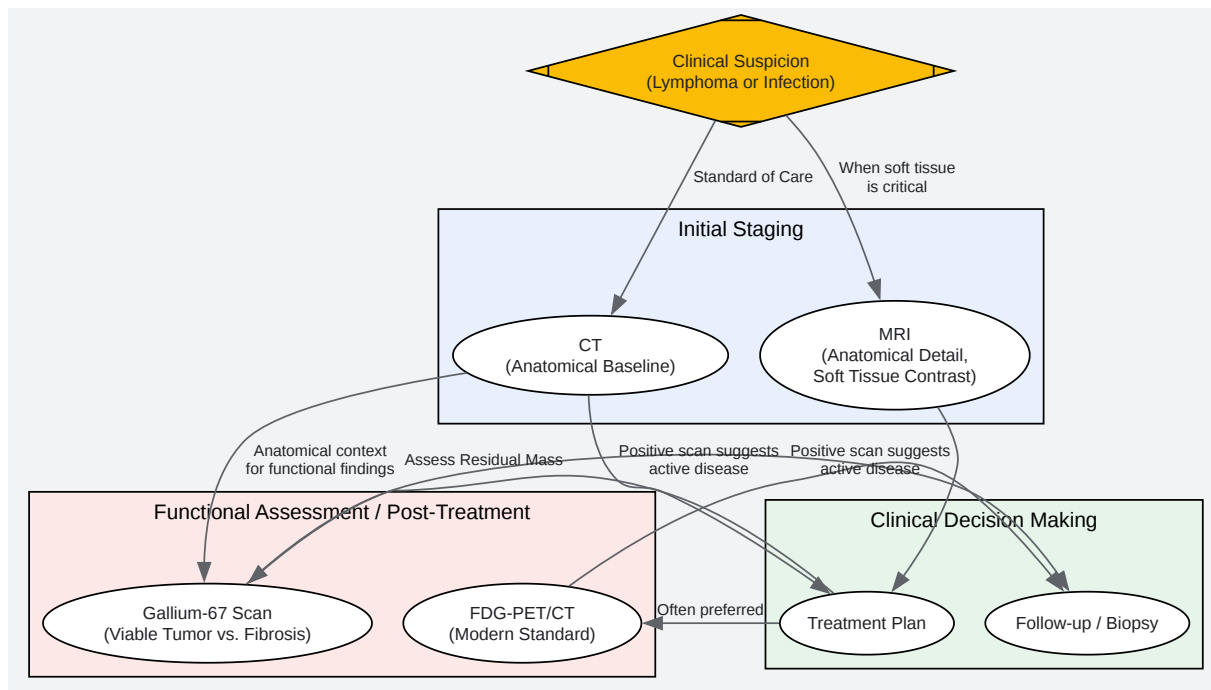
## CT Protocol for Lymphoma Staging

- Patient Preparation: Patients may be given oral contrast to opacify the bowel. Intravenous iodinated contrast is typically administered.[\[14\]](#)
- Scanning Technique: Modern staging is performed on multidetector-row CT scanners.[\[14\]](#) The scan typically covers the area from the neck to the pelvis.
- Image Interpretation:
  - Nodal involvement is primarily determined by size criteria, with a short-axis diameter greater than 10 mm generally considered positive.[\[14\]](#)
  - CT provides excellent anatomical detail of nodal and extranodal disease.[\[14\]](#) However, it cannot reliably distinguish between active tumor and residual fibrotic tissue after treatment.[\[1\]](#)[\[15\]](#)
- Staging Systems: The Lugano classification, which incorporates findings from both CT and PET-CT, is the current standard for staging and response assessment in lymphoma.[\[16\]](#)[\[17\]](#)  
[\[18\]](#)

## Visualization of Methodologies and Logical Relationships

To better illustrate the interplay between these imaging modalities, the following diagrams, created using the DOT language, depict the experimental workflow and the logical framework for their application.





[Click to download full resolution via product page](#)

### Need Custom Synthesis?

BenchChem offers custom synthesis for rare earth carbides and specific isotopic labeling.

Email: [info@benchchem.com](mailto:info@benchchem.com) or [Request Quote Online](#).

## References

- 1. Current role of gallium scan and magnetic resonance imaging in the management of mediastinal Hodgkin lymphoma - PubMed [pubmed.ncbi.nlm.nih.gov]
- 2. Comparison of magnetic resonance imaging and (67)gallium scintigraphy in the evaluation of posttherapeutic residual mediastinal mass in the patients with Hodgkin's lymphoma -



PubMed [pubmed.ncbi.nlm.nih.gov]

- 3. Comparison of gallium scan, computed tomography, and magnetic resonance in patients with mediastinal Hodgkin's disease [iris.hunimed.eu]
- 4. Comparison of gallium scan, computed tomography, and magnetic resonance in patients with mediastinal Hodgkin's disease - PubMed [pubmed.ncbi.nlm.nih.gov]
- 5. researchgate.net [researchgate.net]
- 6. Gallium-67 Scintigraphy in the Era of Positron Emission Tomography and Computed Tomography: Tertiary centre experience - PMC [pmc.ncbi.nlm.nih.gov]
- 7. Does supplementation of CT and MRI with gallium-67 SPECT improve the differentiation between benign and malignant tumors of the head and neck? - PubMed [pubmed.ncbi.nlm.nih.gov]
- 8. apps.ausrad.com [apps.ausrad.com]
- 9. Gallium Scan - StatPearls - NCBI Bookshelf [ncbi.nlm.nih.gov]
- 10. radiology.unm.edu [radiology.unm.edu]
- 11. jnm.snmjournals.org [jnm.snmjournals.org]
- 12. mrimaster.com [mrimaster.com]
- 13. radiopaedia.org [radiopaedia.org]
- 14. ashpublications.org [ashpublications.org]
- 15. Monitoring bulky mediastinal disease with gallium-67, CT-scan and magnetic resonance imaging in Hodgkin's disease and high-grade non-Hodgkin's lymphoma - PubMed [pubmed.ncbi.nlm.nih.gov]
- 16. radiopaedia.org [radiopaedia.org]
- 17. pubs.rsna.org [pubs.rsna.org]
- 18. radiopaedia.org [radiopaedia.org]
- To cite this document: BenchChem. [A Comparative Guide to Gallium-67 Imaging and Anatomical Modalities (MRI & CT)]. BenchChem, [2025]. [Online PDF]. Available at: [https://www.benchchem.com/product/b084094#cross-validation-of-gallium-67-imaging-with-mri-or-ct-scans]

---

#### Disclaimer & Data Validity:

The information provided in this document is for Research Use Only (RUO) and is strictly not intended for diagnostic or therapeutic procedures. While BenchChem strives to provide accurate protocols, we make no warranties, express or implied, regarding the fitness of this product for every specific experimental setup.

**Technical Support:** The protocols provided are for reference purposes. Unsure if this reagent suits your experiment? [[Contact our Ph.D. Support Team for a compatibility check](#)]

**Need Industrial/Bulk Grade?** [Request Custom Synthesis Quote](#)

## BenchChem

Our mission is to be the trusted global source of essential and advanced chemicals, empowering scientists and researchers to drive progress in science and industry.

### Contact

Address: 3281 E Guasti Rd  
Ontario, CA 91761, United States  
Phone: (601) 213-4426  
Email: [info@benchchem.com](mailto:info@benchchem.com)