

A Comparative Guide to Ceretec Scintigraphy for Diagnosing Inflammatory Conditions

Author: BenchChem Technical Support Team. **Date:** December 2025

Compound of Interest

Compound Name: Ceretec

Cat. No.: B1204290

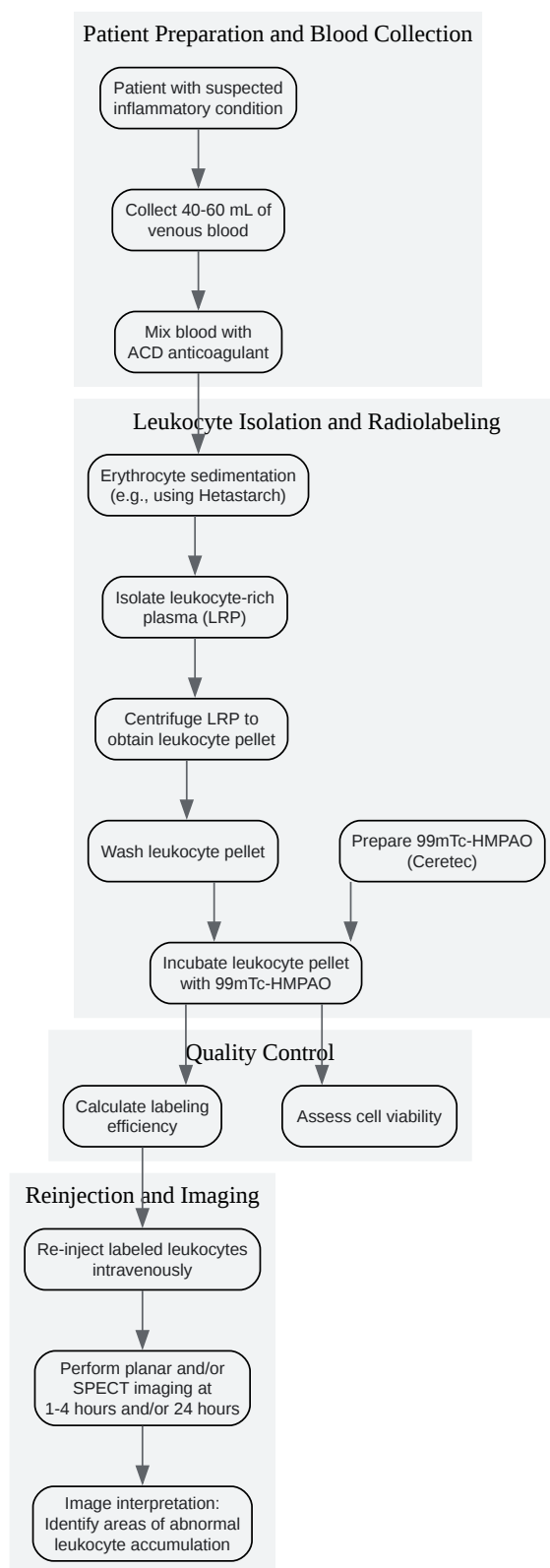
[Get Quote](#)

For Researchers, Scientists, and Drug Development Professionals

This guide provides a comprehensive comparison of **Ceretec** (99mTc-exametazime or HMPAO) scintigraphy with other imaging modalities for the diagnosis of inflammatory conditions. The information is intended to assist researchers, scientists, and drug development professionals in selecting the most appropriate imaging techniques for their specific needs.

Experimental Workflow: 99mTc-HMPAO Labeled Leukocyte Scintigraphy

The following diagram outlines the typical workflow for performing **Ceretec** scintigraphy for the diagnosis of inflammatory conditions. This procedure involves the radiolabeling of a patient's own white blood cells (leukocytes) and tracking their accumulation at sites of inflammation.



[Click to download full resolution via product page](#)

Diagram 1: Experimental workflow for 99mTc-HMPAO labeled leukocyte scintigraphy.

Key Findings on the Accuracy of Ceretec Scintigraphy

Ceretec scintigraphy, specifically ^{99m}Tc -HMPAO labeled leukocyte imaging, is a well-established nuclear medicine technique for localizing infection and inflammation. The principle lies in the ability of radiolabeled white blood cells (WBCs) to migrate to and accumulate at sites of inflammation, allowing for their visualization with a gamma camera.

The diagnostic accuracy of **Ceretec** scintigraphy has been evaluated for various inflammatory conditions, often in comparison to other imaging modalities. For the diagnosis of inflammatory bowel disease (IBD), ^{99m}Tc -HMPAO labeled leukocyte scintigraphy has demonstrated high sensitivity and specificity. In a study comparing it with endoscopy, radiology, and ^{111}In -labeled human polyclonal immunoglobulin G (^{111}In -IgG), the ^{99m}Tc -WBC scan showed a sensitivity of 96.3%, specificity of 85.7%, and accuracy of 94.1%.^[1] Another study on IBD found that ^{99m}Tc -HMPAO is the agent of choice in terms of isotope availability, radiation dosimetry, and image quality for detecting active IBD, with the ability to localize disease as early as 1-hour post-injection.^[2]

In the context of intra-abdominal sepsis, a study comparing 4-hour ^{99m}Tc -leukocyte scans with 24-hour ^{111}In -leukocyte scans reported a sensitivity of 100% for the ^{99m}Tc scan, but a lower specificity of 62% due to physiologic bowel uptake.^{[3][4]} This highlights a limitation of ^{99m}Tc -HMPAO for abdominal imaging, where ^{111}In -labeled leukocytes may be preferred due to the lack of normal gastrointestinal excretion.^[5]

For musculoskeletal infections, such as prosthetic joint infections, ^{99m}Tc -HMPAO-leukocyte scintigraphy has shown improved diagnostic accuracy when a semiquantitative evaluation is added to the qualitative analysis. One study reported that with semiquantitative analysis, the sensitivity, specificity, and accuracy were all 95.8%.^[6] In the diagnosis of osteomyelitis, ^{99m}Tc -HMPAO labeled WBC scintigraphy is considered a valuable tool, with a systematic review suggesting its accuracy may be comparable to MRI and PET.^[7]

In the evaluation of cerebral vasculitis, ^{99m}Tc -HMPAO SPECT (which assesses cerebral perfusion rather than leukocyte accumulation) has demonstrated high sensitivity (87.5%) in detecting perfusion abnormalities, suggesting its utility in the early diagnosis of central nervous system involvement in vasculitis.^[8]

Experimental Methodologies

A standardized protocol for the labeling of leukocytes with ^{99m}Tc -HMPAO is crucial for ensuring the quality and accuracy of the scintigraphic study. The European Association of Nuclear Medicine (EANM) has published guidelines for this procedure.^{[9][10]}

^{99m}Tc -HMPAO Labeled Leukocyte Scintigraphy Protocol:

- Blood Collection and Leukocyte Separation:
 - Approximately 40-60 mL of venous blood is drawn from the patient and mixed with an anticoagulant (e.g., ACD solution).
 - Erythrocyte sedimentation is facilitated using an agent like 6% hydroxyethyl starch (hetastarch).
 - The leukocyte-rich plasma (LRP) is then carefully separated.
- Leukocyte Labeling:
 - The LRP is centrifuged to form a leukocyte pellet.
 - The pellet is washed and then incubated with freshly prepared, unstabilized ^{99m}Tc -exametazime (**Ceretec**).
- Quality Control:
 - The labeling efficiency (the percentage of radioactivity bound to the leukocytes) is calculated and should typically be greater than 40%.
 - Cell viability is assessed to ensure the functional integrity of the labeled leukocytes.
- ReInjection and Imaging:
 - The suspension of ^{99m}Tc -labeled leukocytes is reinjected into the patient intravenously.
 - Planar and/or SPECT (Single Photon Emission Computed Tomography) images are acquired at various time points, typically between 1 and 4 hours, and sometimes at 24

hours post-injection.

Alternative Imaging Modalities:

- **Indium-111 Labeled Leukocyte Scintigraphy:** The protocol is similar to that of 99mTc-HMPAO labeling, but uses 111In-oxine to radiolabel the leukocytes. Imaging is typically performed at 24 hours post-injection.
- **Gallium-67 Scintigraphy:** Gallium-67 citrate is injected intravenously. It binds to transferrin in the plasma and accumulates in areas of inflammation, infection, and tumors. Imaging is usually performed at 48-72 hours post-injection.
- **18F-FDG PET/CT:** The patient is injected with the glucose analog 18F-fluorodeoxyglucose (FDG). Inflammatory cells have high glucose metabolism and therefore show increased uptake of FDG. PET (Positron Emission Tomography) scans are typically acquired 60 minutes after injection and are often fused with CT (Computed Tomography) images for better anatomical localization.

Quantitative Data Summary

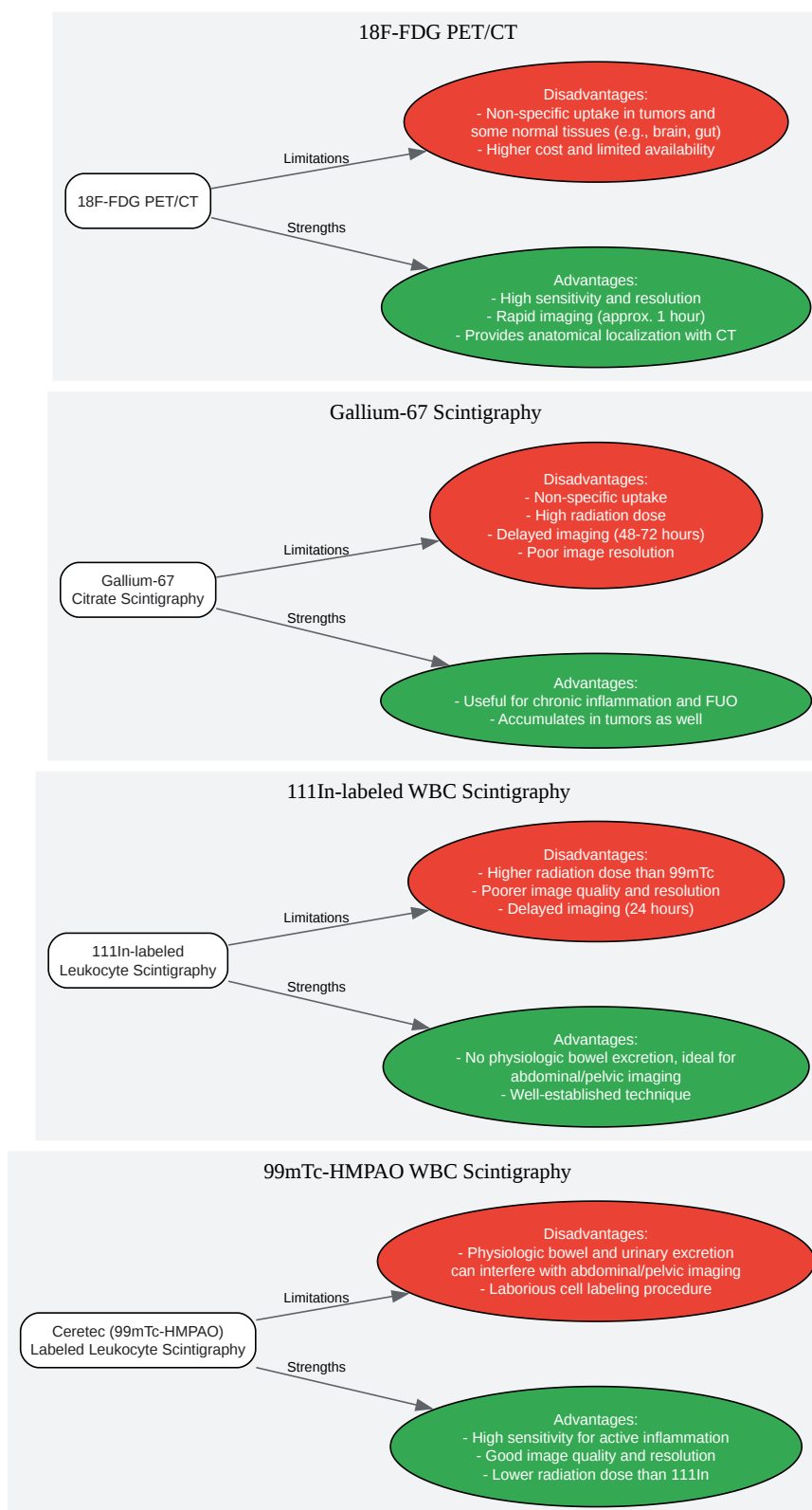
The following table summarizes the diagnostic accuracy of **Ceretec** scintigraphy in comparison to other imaging modalities for various inflammatory conditions.

Inflammatory Condition	Imaging Modality	Sensitivity (%)	Specificity (%)	Accuracy (%)	Reference
Inflammatory Bowel Disease	99mTc-HMPAO WBC Scintigraphy	96.3	85.7	94.1	[1]
Endoscopy	88.5	100	90.3	[1]	
Radiology	73.7	75	73.9	[1]	
111In-IgG Scintigraphy	59.3	85.7	64.7	[1]	
99mTc-HMPAO WBC Scintigraphy	87.8	84.5	-	[11] [12]	
Ultrasonography	89.7	95.6	-	[11] [12]	[3] [4]
MRI	93.0	92.8	-	[11] [12]	
CT	84.3	95.1	-	[11] [12]	
Intra-abdominal Sepsis	99mTc-HMPAO WBC (4-hr)	100	62	-	
111In-oxine WBC (4-hr)	67	90	-	[3] [4]	
111In-oxine WBC (24-hr)	100	86	-	[3] [4]	[6]
Prosthetic Joint Infection	99mTc-HMPAO WBC (Qualitative)	80.4 - 87	65.3 - 71.4	75.8 - 77.9	
99mTc-HMPAO WBC (Semiquantitative)	95.6	95.8	95.8	[6]	

Osteomyelitis (Diabetic Foot)	99mTc- HMPAO WBC SPECT/CT	89	35	-	[13]
MRI		87	37	-	[13]
Cerebral Vasculitis	99mTc- HMPAO SPECT	87.5	-	-	[8]

Comparison of Imaging Modalities

The choice of imaging modality for diagnosing inflammatory conditions depends on the specific clinical question, the location of the suspected inflammation, and the advantages and disadvantages of each technique.



[Click to download full resolution via product page](#)

Diagram 2: Logical comparison of **Ceretec** scintigraphy with other imaging modalities.

Conclusion

Ceretec (99mTc-HMPAO) labeled leukocyte scintigraphy is a highly sensitive and accurate method for diagnosing a variety of inflammatory conditions, particularly inflammatory bowel disease and musculoskeletal infections. Its advantages include good image quality and a lower radiation dose compared to 111In-labeled leukocyte scintigraphy. However, its utility in the abdomen and pelvis can be limited by physiologic bowel and urinary excretion of the radiotracer.

The choice between **Ceretec** scintigraphy and other imaging modalities such as 111In-labeled leukocyte scintigraphy, Gallium-67 scintigraphy, and 18F-FDG PET/CT depends on the specific clinical scenario. For suspected intra-abdominal infections, 111In-labeled leukocytes are often preferred due to the absence of gut excretion. Gallium-67 may be useful for chronic inflammation and fever of unknown origin, while 18F-FDG PET/CT offers high sensitivity and excellent resolution, though with less specificity for inflammation versus malignancy. For anatomical imaging and the detection of complications, modalities like MRI and CT remain indispensable and are often used in conjunction with nuclear medicine studies. A thorough understanding of the strengths and limitations of each technique is essential for optimal diagnostic workup and for guiding research and drug development in the field of inflammatory diseases.

Need Custom Synthesis?

BenchChem offers custom synthesis for rare earth carbides and specific isotopic labeling.

Email: info@benchchem.com or [Request Quote Online](#).

References

- 1. [Comparison of endoscopy, radiology and scintigraphy with Tc-99m-exametazine labeled leukocytes and In-111 labeled human polyclonal immunoglobulin G in the diagnosis of inflammatory bowel disease] - PubMed [pubmed.ncbi.nlm.nih.gov]
- 2. Comparison of simultaneous 99mTc-HMPAO and 111In oxine labelled white cell scans in the assessment of inflammatory bowel disease - PubMed [pubmed.ncbi.nlm.nih.gov]
- 3. Comparison of technetium-99m-HM-PAO leukocytes with indium-111-oxine leukocytes for localizing intraabdominal sepsis - PubMed [pubmed.ncbi.nlm.nih.gov]

- 4. Comparison of technetium-99m-HM-PAO leukocytes with indium-111-oxine leukocytes for localizing intraabdominal sepsis (Journal Article) | OSTI.GOV [osti.gov]
- 5. Guidelines for the labelling of leucocytes with 99mTc-HMPAO - PMC [pmc.ncbi.nlm.nih.gov]
- 6. jnm.snmjournals.org [jnm.snmjournals.org]
- 7. Conclusions - Imaging tests for the detection of osteomyelitis: a systematic review - NCBI Bookshelf [ncbi.nlm.nih.gov]
- 8. 99m-Tc-HMPAO-SPECT in diagnosis of early cerebral vasculitis - PubMed [pubmed.ncbi.nlm.nih.gov]
- 9. Guidelines for the labelling of leucocytes with (99m)Tc-HMPAO. Inflammation/Infection Taskgroup of the European Association of Nuclear Medicine - PubMed [pubmed.ncbi.nlm.nih.gov]
- 10. iaea.org [iaea.org]
- 11. researchgate.net [researchgate.net]
- 12. Inflammatory bowel disease diagnosed with US, MR, scintigraphy, and CT: meta-analysis of prospective studies - Database of Abstracts of Reviews of Effects (DARE): Quality-assessed Reviews - NCBI Bookshelf [ncbi.nlm.nih.gov]
- 13. hmpgloballearningnetwork.com [hmpgloballearningnetwork.com]
- To cite this document: BenchChem. [A Comparative Guide to Ceretec Scintigraphy for Diagnosing Inflammatory Conditions]. BenchChem, [2025]. [Online PDF]. Available at: [https://www.benchchem.com/product/b1204290#accuracy-of-ceretec-scintigraphy-in-diagnosing-inflammatory-conditions]

Disclaimer & Data Validity:

The information provided in this document is for Research Use Only (RUO) and is strictly not intended for diagnostic or therapeutic procedures. While BenchChem strives to provide accurate protocols, we make no warranties, express or implied, regarding the fitness of this product for every specific experimental setup.

Technical Support: The protocols provided are for reference purposes. Unsure if this reagent suits your experiment? [[Contact our Ph.D. Support Team for a compatibility check](#)]

Need Industrial/Bulk Grade? [Request Custom Synthesis Quote](#)

BenchChem

Our mission is to be the trusted global source of essential and advanced chemicals, empowering scientists and researchers to drive progress in science and industry.

Contact

Address: 3281 E Guasti Rd

Ontario, CA 91761, United States

Phone: (601) 213-4426

Email: info@benchchem.com