

A Comparative Guide to Assessing Fracture Healing: Ultrasound vs. Traditional Radiography

Author: BenchChem Technical Support Team. **Date:** December 2025

Compound of Interest

Compound Name: SQ 27786

Cat. No.: B1681082

[Get Quote](#)

For researchers and drug development professionals, accurately and quantitatively assessing fracture healing is paramount to evaluating the efficacy of novel therapeutics and understanding the biological processes of bone repair. While traditional radiography (X-ray) has long been the standard, high-frequency ultrasound, particularly with Doppler capabilities, is emerging as a valuable alternative, offering distinct advantages in visualizing the early stages of healing. This guide provides an objective comparison of these two modalities, supported by experimental data and detailed protocols.

At a Glance: Ultrasound vs. Radiography for Fracture Healing Assessment

Feature	Ultrasound	Traditional Radiography
Imaging Principle	High-frequency sound waves	Ionizing radiation (X-rays)
Key Assessments	Soft callus formation, neovascularization, cortical bridging	Hard callus formation, fracture line visibility, cortical continuity
Radiation Exposure	None	Yes
Real-time Imaging	Yes	No
Soft Tissue Detail	Excellent	Poor
Early Healing Detection	Superior for soft callus and vascularity	Limited until callus mineralization
Operator Dependence	High	Moderate
Cost	Generally lower	Generally higher
Portability	High	Low

Quantitative Comparison of Healing Assessment

The primary advantage of ultrasound is its ability to detect signs of healing earlier than radiography. This is crucial for early intervention in cases of delayed or non-union.

Parameter	Ultrasound	Radiography	Key Findings
Time to Detect Callus	~10-16 days (soft callus)[1]	~19 days (hard callus) [2]	Ultrasound can identify the initial soft, non-mineralized callus weeks before it becomes visible on X-rays.
Time to Union Confirmation	Mean 6.5 weeks	Mean 19 weeks	In some studies, ultrasound confirmed healing significantly earlier than radiographs.
Vascularity Assessment	Power Doppler detects neovascularization in the first month.[3][4]	Not applicable	Increased blood flow is a key indicator of active healing and can be quantified with ultrasound.
Callus Index	Can measure callus dimensions.	Can measure callus diameter.	Both methods can quantify callus size, but ultrasound can differentiate soft and hard callus components.

Experimental Protocols

Radiographic Assessment of Fracture Healing

Objective: To visually assess the progression of mineralized callus formation and the bridging of the fracture gap.

Protocol:

- Patient Positioning:** The limb with the fracture is positioned to obtain at least two orthogonal views, typically anteroposterior (AP) and lateral.

- Image Acquisition: Standard radiographic equipment is used. Exposure settings (kVp and mAs) are optimized for bony detail of the specific anatomical location.
- Follow-up Imaging: Radiographs are typically taken at set intervals, such as 6, 12, and 24 weeks post-operatively, to monitor healing progression.^[5]
- Data Analysis (Scoring):
 - Radiographic Union Scale for Tibial Fractures (RUST): This is a widely used 10-point scoring system.^{[6][7]} Each of the four cortices (anterior, posterior, medial, and lateral) is scored based on the presence and nature of the callus and the visibility of the fracture line.^{[5][7]}
 - 1 point: Fracture line is visible with no callus.
 - 2 points: Callus is present, but the fracture line is still visible.
 - 3 points: Callus is bridging, and the fracture line is not visible.
 - A total score is calculated (range: 4-12), with higher scores indicating better healing.
 - Lane and Sandhu Score: Another scoring system that evaluates bone formation and union, often used in animal models but applicable to human studies.^{[8][9]} It typically assesses callus formation, fracture line visibility, and cortical continuity.

Ultrasound Assessment of Fracture Healing

Objective: To assess both the structural (callus formation) and biological (vascularity) aspects of fracture healing in real-time.

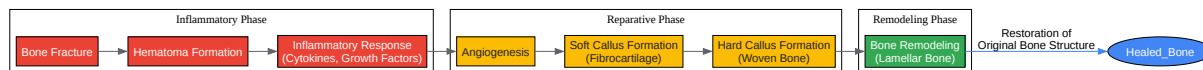
Protocol:

- Equipment: A high-resolution ultrasound machine with a high-frequency linear transducer (e.g., 5-17 MHz) is used.^[10] Power Doppler functionality is essential for vascular assessment.
- Patient Positioning: The patient is positioned comfortably, allowing for generous application of ultrasound gel and access to the fracture site from multiple angles.

- Image Acquisition:
 - B-mode (Grayscale) Imaging: The transducer is placed over the fracture site to visualize the bone cortex and surrounding soft tissues. The sonographer assesses:
 - Cortical disruption or "step-off" deformity.
 - The presence and echogenicity of the fracture hematoma and subsequent callus formation. The callus appears as a hypoechoic structure initially, becoming progressively more hyperechoic as it mineralizes.[\[11\]](#)
 - Measurements of callus length and width are taken.[\[10\]](#)
 - Power Doppler Imaging: This mode is activated to detect and quantify blood flow within the callus and surrounding periosteum.[\[4\]](#)
 - Settings should be optimized for low-flow states to detect the small vessels of neovascularization.
 - The degree of vascularity can be semi-quantitatively scored or measured by counting vessels within a defined area.[\[10\]](#)
- Follow-up Imaging: Ultrasound examinations can be performed more frequently than radiographs due to the lack of ionizing radiation, allowing for a more detailed temporal analysis of the healing process.

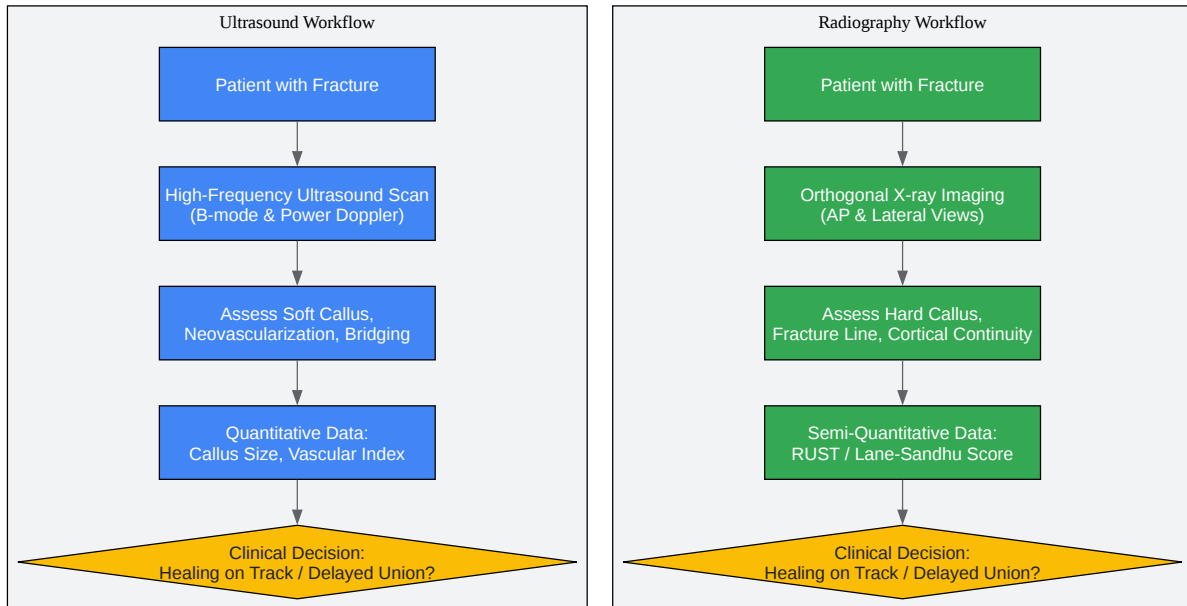
Visualizing Biological and Methodological Frameworks

To better understand the underlying biology and the assessment workflows, the following diagrams are provided.



[Click to download full resolution via product page](#)

The biological cascade of fracture healing.



[Click to download full resolution via product page](#)

Comparison of clinical assessment workflows.

Conclusion

Traditional radiography remains the clinical gold standard for assessing the structural integrity of a healing fracture, particularly in the later stages when a hard, mineralized callus has

formed. Its primary strengths are its ability to visualize the mineralized tissues and the widespread availability and familiarity of the technique.

However, ultrasound offers a significant paradigm shift, particularly for research and development where early and detailed biological insights are critical. Its ability to visualize soft callus and quantify neovascularization without ionizing radiation provides a real-time window into the crucial early stages of bone repair.[1] This can lead to earlier detection of delayed union and provides quantitative biological endpoints for assessing the efficacy of therapeutic interventions. For a comprehensive understanding of fracture healing, particularly in a research context, a combination of both ultrasound and radiography may provide the most complete picture, capturing both the early biological response and the eventual restoration of structural integrity.

Need Custom Synthesis?

BenchChem offers custom synthesis for rare earth carbides and specific isotopic labeling.

Email: info@benchchem.com or [Request Quote Online](#).

References

- 1. Ultrasound imaging of bone fractures - PMC [pmc.ncbi.nlm.nih.gov]
- 2. ajronline.org [ajronline.org]
- 3. Assessment of neovascularization during bone healing using contrast-enhanced ultrasonography in a canine tibial osteotomy model: a preliminary study - PMC [pmc.ncbi.nlm.nih.gov]
- 4. What is the role of ultrasound in fracture management? Diagnosis and therapeutic potential for fractures, delayed unions, and fracture-related infection - PMC [pmc.ncbi.nlm.nih.gov]
- 5. researchgate.net [researchgate.net]
- 6. The radiographic union scale in tibial (RUST) fractures: Reliability of the outcome measure at an independent centre - PMC [pmc.ncbi.nlm.nih.gov]
- 7. Reliability of the radiographic union scale in tibial fractures (RUST) - PMC [pmc.ncbi.nlm.nih.gov]
- 8. medicalalgorithms.com [medicalalgorithms.com]

- 9. The reliability of the Lane-Sandhu score and the modified RUST for the assessment of postoperative radiographs of long bone non-unions and bone defects - PubMed [pubmed.ncbi.nlm.nih.gov]
- 10. The Role of Ultrasound Imaging of Callus Formation in the Treatment of Long Bone Fractures in Children - PMC [pmc.ncbi.nlm.nih.gov]
- 11. JCDR - Fracture, Healing, Ultrasound, Callus, Mineralization, Vascularization [jcdr.net]
- To cite this document: BenchChem. [A Comparative Guide to Assessing Fracture Healing: Ultrasound vs. Traditional Radiography]. BenchChem, [2025]. [Online PDF]. Available at: [https://www.benchchem.com/product/b1681082#assessing-fracture-healing-with-ultrasound-versus-traditional-radiography]

Disclaimer & Data Validity:

The information provided in this document is for Research Use Only (RUO) and is strictly not intended for diagnostic or therapeutic procedures. While BenchChem strives to provide accurate protocols, we make no warranties, express or implied, regarding the fitness of this product for every specific experimental setup.

Technical Support: The protocols provided are for reference purposes. Unsure if this reagent suits your experiment? [[Contact our Ph.D. Support Team for a compatibility check](#)]

Need Industrial/Bulk Grade? [Request Custom Synthesis Quote](#)

BenchChem

Our mission is to be the trusted global source of essential and advanced chemicals, empowering scientists and researchers to drive progress in science and industry.

Contact

Address: 3281 E Guasti Rd
Ontario, CA 91761, United States
Phone: (601) 213-4426
Email: info@benchchem.com