

# A Comparative Guide: Fluorometholone vs. Loteprednol Etabonate in Ocular Inflammation Models

**Author:** BenchChem Technical Support Team. **Date:** December 2025

## Compound of Interest

Compound Name: Fluorometholone

Cat. No.: B1672912

[Get Quote](#)

For Researchers, Scientists, and Drug Development Professionals

This guide provides an objective comparison of the performance of two widely used topical corticosteroids, **fluorometholone** (FML) and loteprednol etabonate (LE), in preclinical and clinical models of ocular inflammation. The information presented is supported by experimental data to aid in the evaluation and selection of these agents for research and development purposes.

## Executive Summary

**Fluorometholone** and loteprednol etabonate are both effective in managing ocular inflammation. Preclinical studies in rabbit models of uveitis show that **fluorometholone** may have a slight efficacy advantage in some acute and chronic inflammation paradigms. However, both agents demonstrate comparable efficacy in controlling postoperative inflammation following cataract and refractive surgeries. A key differentiator is intraocular pressure (IOP) elevation; multiple studies indicate that loteprednol etabonate has a lower propensity for causing clinically significant increases in IOP compared to **fluorometholone**, a critical safety consideration in glucocorticoid therapy.

## Data Presentation

### Table 1: Efficacy in Endotoxin-Induced Uveitis in Rabbits

Parameter	Fluorometholone (FML)	Loteprednol Etabonate (LE)	Dexamethasone (Reference)	Key Finding
Reduction in Inflammatory Measures	More effective than LE	Effective, but less so than FML and Dexamethasone	Effective	FML showed greater anti-inflammatory activity than LE in this acute model. <a href="#">[1]</a>

**Table 2: Efficacy in Freund's Adjuvant-Induced Chronic Uveitis in Rabbits**

Parameter	Fluorometholone (FML)	Loteprednol Etabonate (LE)	Dexamethasone (Reference)	Key Finding
Reduction in Inflammatory Measures	Very effective	Similar activity to Dexamethasone	Similar activity to LE	FML was highly effective, while LE and dexamethasone showed comparable efficacy. <a href="#">[1]</a>

**Table 3: Efficacy in Postoperative Inflammation Following Cataract Surgery (Phacoemulsification)**

Parameter	Fluorometholone Acetate 0.1%	Loteprednol Etabonate 0.5%	Study Design	Key Finding
Anterior Chamber Flare	No flare observed in any patient on day 21	3 patients still showed flare on day 21	Randomized, double-masked, parallel-group study in 30 patients	No statistically significant difference in flare, anterior segment cells, or conjunctival hyperemia scores between the two groups. <a href="#">[2]</a>
Anterior Chamber Cells	Not statistically different from LE	Not statistically different from FML	Randomized, double-masked, parallel-group study in 30 patients	Efficacies were considered equivalent. <a href="#">[2]</a>
Conjunctival Hyperemia	Not statistically different from LE	Not statistically different from FML	Randomized, double-masked, parallel-group study in 30 patients	Efficacies were considered equivalent. <a href="#">[2]</a>

**Table 4: Efficacy and Safety in Postoperative Management Following Photorefractive Keratectomy (PRK)**

Parameter	Fluorometholone 0.1%	Loteprednol Etabonate 0.5%	Study Design	Key Findings
Uncorrected Distance Visual Acuity (UDVA) at 3 months (20/25 or better)	92% of eyes	95% of eyes	Randomized, fellow-eye comparison in 124 eyes of 62 patients	No significant difference in visual outcomes.
Corneal Haze	No visually significant haze	No visually significant haze	Randomized, fellow-eye comparison in 124 eyes of 62 patients	Both were effective in preventing visually significant haze.
Intraocular Pressure (IOP) Increase > 5 mmHg	0% of eyes	5% of eyes	Randomized, fellow-eye comparison in 124 eyes of 62 patients	No statistically significant difference between groups.
IOP Rise > 10 mmHg or IOP > 21 mmHg	Not observed	Not observed	Randomized, fellow-eye comparison in 124 eyes of 62 patients	Neither drug induced ocular hypertension in this study.
Mean Corneal Optical Density Changes	No significant difference from LE	No significant difference from FML	Triple-blinded randomized controlled trial in 100 patients	No significant difference at 1 and 3 months post-intervention.
Mean Best-Corrected Distance Visual Acuity (BCDVA) at 1 month	0.84 ± 0.11	0.79 ± 0.11 (p=0.02)	Triple-blinded randomized controlled trial in 100 patients	Statistically significant difference in favor of FML at 1 month, but not at 3 months.

Mean IOP changes	No significant difference from LE	No significant difference from FML	Triple-blinded randomized controlled trial in 100 patients	No significant difference at 1 and 3 months post-intervention.
------------------	-----------------------------------	------------------------------------	--	--

## Experimental Protocols

### Endotoxin-Induced Uveitis (EIU) in Rabbits

This model induces an acute, transient anterior uveitis.

- Animals: New Zealand White rabbits are commonly used.
- Induction: A single intravitreal injection of E. coli-derived lipopolysaccharide (LPS) endotoxin (e.g., 100 ng in 20 µL) is administered into the vitreous humor. This elicits an inflammatory response that typically resolves within 72 hours.
- Treatment: Test articles (**Fluorometholone** or Loteprednol Etabonate ophthalmic suspensions) or vehicle are administered topically at specified intervals before and/or after LPS injection.
- Assessments:
  - Clinical Evaluation: Slit-lamp biomicroscopy is used to score signs of ocular inflammation, including conjunctival hyperemia, chemosis, edema, and secretion.
  - Aqueous Humor Analysis: Aqueous humor is collected at various time points (e.g., 24 hours post-injection) to quantify inflammatory cell infiltration (leukocyte counts) and protein concentration (a measure of blood-aqueous barrier breakdown).
  - Cytokine Analysis: Levels of pro-inflammatory cytokines (e.g., TNF-α, IL-6) in the aqueous humor can be measured using techniques like ELISA.

### Freund's Adjuvant-Induced Chronic Uveitis in Rabbits

This model establishes a more prolonged, chronic panuveitis.

- Animals: New Zealand White rabbits are typically used.

- Induction:
  - Sensitization: Rabbits are first sensitized with a subcutaneous injection of Mycobacterium tuberculosis H37RA antigen emulsified in an adjuvant like TiterMax Gold or Freund's Complete Adjuvant (FCA).
  - Challenge: After a period of 2 to 4 weeks, uveitis is induced by an intravitreal challenge with the same antigen in a saline suspension. A second intravitreal challenge can be performed weeks later to sustain the inflammation.
- Treatment: Topical or intravitreal administration of the test compounds is initiated following the antigen challenge.
- Assessments:
  - Clinical Scoring: Regular slit-lamp examinations are performed to grade the severity of anterior chamber and vitreous inflammation (e.g., cells, flare, haze).
  - Histopathology: At the end of the study, eyes are enucleated, sectioned, and stained (e.g., with H&E) to evaluate the extent of inflammatory cell infiltration in the anterior and posterior segments of the eye.

## Postoperative Inflammation Models in Rabbits

These models mimic the inflammatory response following ocular surgery.

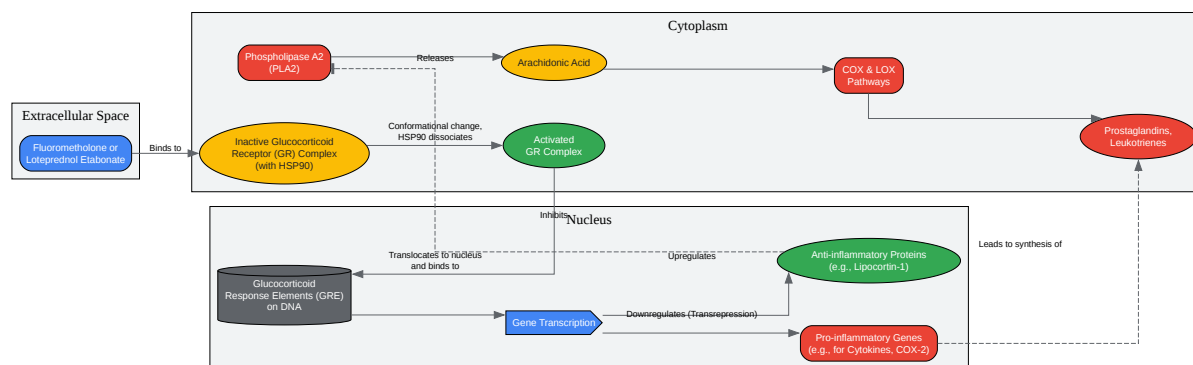
- Photorefractive Keratectomy (PRK) Model:
  - Procedure: After epithelial debridement, an excimer laser is used to create a central corneal ablation of a specific depth (e.g., 22  $\mu\text{m}$ ).
  - Treatment: Topical corticosteroids or vehicle are administered postoperatively for a defined period (e.g., up to 3 months).
  - Assessments: Corneal haze is graded clinically. Corneas can be examined by immunofluorescence and electron microscopy to assess keratocyte activity and repopulation, and extracellular matrix deposition.

- Cataract Surgery (Phacoemulsification) Model:
  - Procedure: A clear corneal incision is made, a capsulorhexis is performed, and the lens nucleus and cortex are removed by phacoemulsification and aspiration. An intraocular lens (IOL) may or may not be implanted.
  - Treatment: Test agents are administered topically or via intracameral injection post-surgery.
  - Assessments: Ocular inflammatory scores (e.g., Hackett-McDonald scores), intraocular pressure, and central corneal thickness are measured at various postoperative time points. Confocal microscopy can be used to evaluate the corneal endothelium.

## Signaling Pathways and Experimental Workflows

### Corticosteroid Anti-Inflammatory Signaling Pathway

Corticosteroids like **fluorometholone** and loteprednol etabonate exert their anti-inflammatory effects primarily through the glucocorticoid receptor (GR).



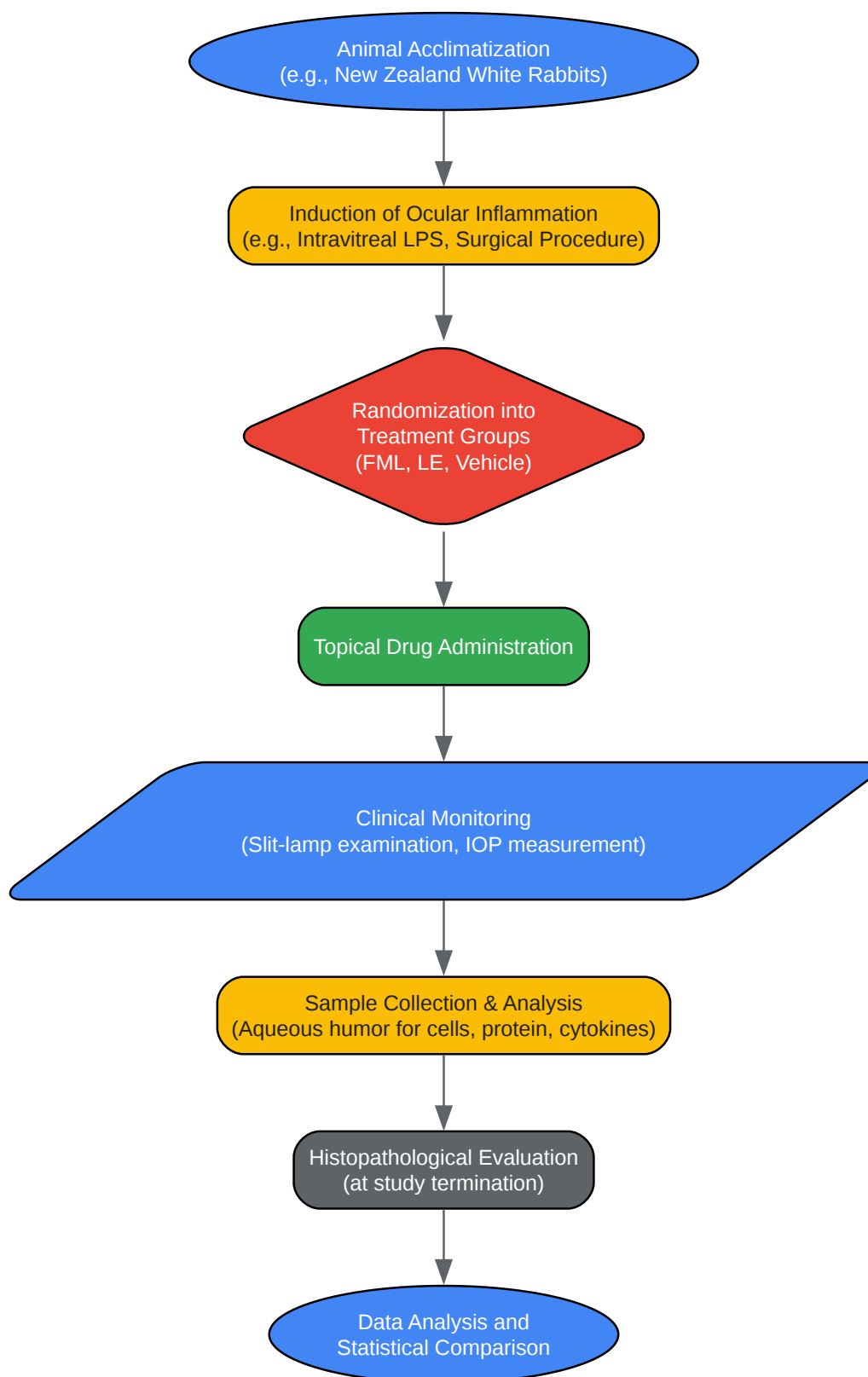
[Click to download full resolution via product page](#)

Caption: General mechanism of corticosteroid action in ocular inflammation.

## Experimental Workflow for Preclinical Ocular Inflammation Studies

The following diagram illustrates a typical workflow for evaluating anti-inflammatory agents in rabbit models.





[Click to download full resolution via product page](#)

Caption: A typical experimental workflow for preclinical ocular inflammation studies.

In conclusion, both **fluorometholone** and loteprednol etabonate are valuable tools for managing ocular inflammation. The choice between them for research or clinical development may depend on the specific inflammatory model and the relative importance of maximizing anti-inflammatory potency versus minimizing the risk of IOP elevation.

#### Need Custom Synthesis?

BenchChem offers custom synthesis for rare earth carbides and specific isotopic labeling.

Email: [info@benchchem.com](mailto:info@benchchem.com) or [Request Quote Online](#).

## References

- 1. Loteprednol etabonate: comparison with other steroids in two models of intraocular inflammation - PubMed [pubmed.ncbi.nlm.nih.gov]
- 2. iovs.arvojournals.org [iovs.arvojournals.org]
- To cite this document: BenchChem. [A Comparative Guide: Fluorometholone vs. Loteprednol Etabonate in Ocular Inflammation Models]. BenchChem, [2025]. [Online PDF]. Available at: [https://www.benchchem.com/product/b1672912#fluorometholone-versus-loteprednol-etabonate-in-ocular-inflammation-models]

---

#### Disclaimer & Data Validity:

The information provided in this document is for Research Use Only (RUO) and is strictly not intended for diagnostic or therapeutic procedures. While BenchChem strives to provide accurate protocols, we make no warranties, express or implied, regarding the fitness of this product for every specific experimental setup.

**Technical Support:** The protocols provided are for reference purposes. Unsure if this reagent suits your experiment? [[Contact our Ph.D. Support Team for a compatibility check](#)]

**Need Industrial/Bulk Grade?** [Request Custom Synthesis Quote](#)

# BenchChem

Our mission is to be the trusted global source of essential and advanced chemicals, empowering scientists and researchers to drive progress in science and industry.

## Contact

Address: 3281 E Guasti Rd

Ontario, CA 91761, United States

Phone: (601) 213-4426

Email: [info@benchchem.com](mailto:info@benchchem.com)