

A Comparative Analysis of Tropical and Temperate Pyomyositis: A Technical Guide

Author: BenchChem Technical Support Team. **Date:** December 2025

Compound of Interest

Compound Name: *Piomy*

Cat. No.: *B1172056*

[Get Quote](#)

For Researchers, Scientists, and Drug Development Professionals

Abstract

Pyomyositis, a primary bacterial infection of skeletal muscle, manifests with distinct clinical characteristics depending on its geographical occurrence. Historically known as "tropical pyomyositis" due to its prevalence in tropical regions, the incidence of this condition is increasingly being reported in temperate climates, often with different patient demographics and predisposing factors. This technical guide provides an in-depth comparison of the clinical presentation of tropical and temperate pyomyositis, offering a valuable resource for researchers, scientists, and professionals involved in drug development. The guide summarizes key quantitative data, outlines experimental protocols for diagnosis, and presents visual representations of the disease's pathogenesis and clinical progression.

Introduction

Pyomyositis is characterized by the formation of abscesses within large skeletal muscles.^[1] While once considered a disease exclusive to the tropics, its emergence in temperate zones has highlighted significant epidemiological and clinical differences.^[2] Understanding these distinctions is crucial for accurate diagnosis, effective treatment, and the development of targeted therapeutic strategies. This guide aims to provide a comprehensive overview of these differences, supported by quantitative data and detailed methodologies.

Clinical Presentation: A Tale of Two Climates

The clinical presentation of pyomyositis varies significantly between tropical and temperate regions, from patient demographics and risk factors to the causative organisms and disease progression.

Demographics and Predisposing Factors

In tropical regions, pyomyositis typically affects young, healthy, and active individuals, with a notable male predominance.^{[3][4]} Conversely, in temperate climates, the disease is more commonly observed in immunocompromised individuals or those with underlying chronic illnesses.^{[3][4][5]}

Characteristic	Tropical Pyomyositis	Temperate Pyomyositis	References
Predominant Age Group	Children and young adults (often 10-40 years)	Bimodal distribution (30-50 and 60-70 years), also seen in children	^{[4][6]}
Gender Predilection	Male > Female (Ratio approx. 1.5:1)	Male predominance	^{[4][7]}
Immune Status	Often immunocompetent, healthy individuals	Frequently immunocompromised	^{[3][4][5]}
Common Predisposing Factors	Minor trauma, vigorous exercise, malnutrition, parasitic infections	HIV/AIDS, diabetes mellitus, malignancy, intravenous drug use, chronic renal failure, rheumatoid arthritis, organ transplant	^{[2][3][4][7][8]}

Etiology: The Microbial Landscape

Staphylococcus aureus is the primary causative agent in both tropical and temperate pyomyositis. However, the proportion of cases attributed to this bacterium is higher in tropical

regions.[9] In temperate zones, a broader range of pathogens, including methicillin-resistant *Staphylococcus aureus* (MRSA) and gram-negative bacteria, are more frequently implicated.[4]

Causative Organism	Tropical Pyomyositis (Approximate Frequency)	Temperate Pyomyositis (Approximate Frequency)	References
<i>Staphylococcus aureus</i>	~90%	~70-75%	[4][9]
<i>Streptococcus pyogenes</i> (Group A Strep)	1-5%	More common than in tropical cases	[9]
Methicillin-Resistant <i>S. aureus</i> (MRSA)	Less common	Increasingly reported	[4]
Gram-Negative Bacilli (e.g., <i>Pseudomonas</i>)	Rare	More frequent, especially in immunocompromised patients	[7][10]
Anaerobes	Uncommon	Can be involved, often in polymicrobial infections	[9]

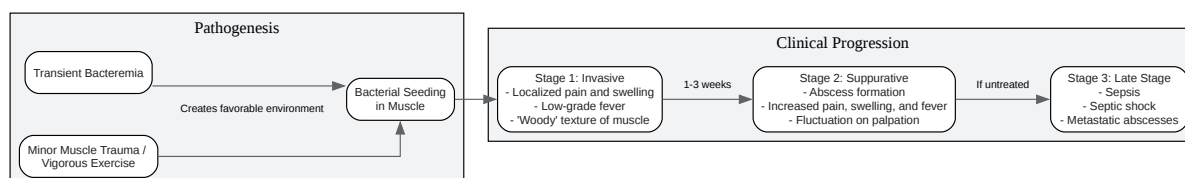
Clinical Features and Progression

The clinical course of pyomyositis is classically divided into three stages. While the progression is similar in both settings, the initial presentation may be more insidious in temperate cases, often leading to a delay in diagnosis.[11]

Clinical Feature	Tropical Pyomyositis	Temperate Pyomyositis	References
Commonly Affected Muscles	Large muscles of the lower limbs and pelvic girdle (e.g., quadriceps, gluteals, iliopsoas)	Similar to tropical, with iliopsoas involvement being common	[4][6][10]
Number of Affected Muscles	Single muscle group is common	Multiple sites may be more frequent	[4]
Initial Symptoms	Subacute onset of fever, localized muscle pain, and tenderness	Often insidious, with vague symptoms that can mimic other conditions	[4][11]
Progression	Follows the three classical stages	Follows the three classical stages, but diagnosis is often made in later stages	[1][4][5][12][13]

Pathogenesis and Clinical Progression

The pathogenesis of pyomyositis is thought to begin with transient bacteremia, with subsequent seeding of bacteria in a muscle that has been predisposed to infection, often due to minor trauma or vigorous exercise.[8] The infection then progresses through distinct stages if left untreated.



[Click to download full resolution via product page](#)

Figure 1: Pathogenesis and Clinical Progression of Pyomyositis.

Diagnostic Workflow

A timely and accurate diagnosis of pyomyositis is crucial to prevent progression to later, more severe stages. The diagnostic process involves a combination of clinical evaluation, laboratory tests, and imaging studies.

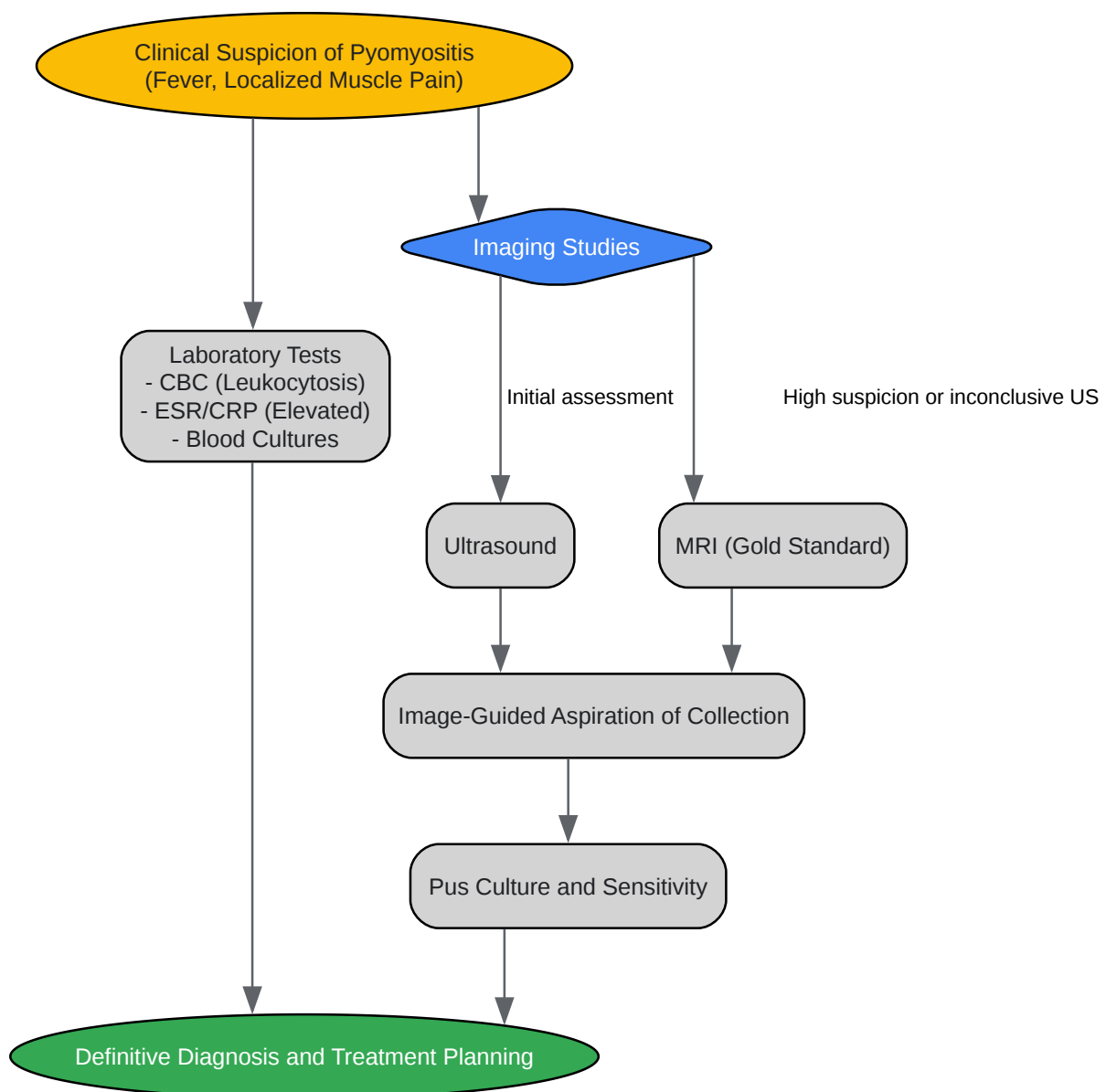
[Click to download full resolution via product page](#)

Figure 2: Diagnostic Workflow for Pyomyositis.

Experimental Protocols

Microbiological Culture

Objective: To isolate and identify the causative bacterial pathogen from pus or blood samples.

a) Sample Collection:

- Pus: Aspirate purulent material from the muscle abscess using a sterile syringe and needle, preferably under ultrasound or CT guidance.[13] Transfer the sample to a sterile, anaerobic transport medium.
- Blood: Collect two sets of blood cultures from different venipuncture sites before initiating antibiotic therapy.[13]

b) Culture and Identification:

- Staphylococcus aureus and Streptococcus pyogenes:
 - Inoculate samples onto 5% sheep blood agar, chocolate agar, and MacConkey agar.[14] For S. pyogenes, selective media like Columbia agar with colistin and nalidixic acid can be used.[6]
 - Incubate plates at 35-37°C in a CO₂-enriched atmosphere (for streptococci) or ambient air for 24-48 hours.[7]
 - Examine for characteristic colony morphology and hemolysis. S. aureus typically produces golden-yellow colonies with beta-hemolysis. S. pyogenes forms small, translucent colonies with a large zone of beta-hemolysis.[6][7]
 - Perform Gram staining (Gram-positive cocci in clusters for Staphylococcus and chains for Streptococcus).[15]
 - Conduct biochemical tests (e.g., catalase and coagulase for S. aureus; bacitracin susceptibility and PYR test for S. pyogenes) for definitive identification.[6]

- Perform antimicrobial susceptibility testing using methods such as disk diffusion or automated systems to guide antibiotic therapy.[14]

Muscle Biopsy and Histopathology

Objective: To obtain muscle tissue for histopathological examination to confirm myositis and rule out other pathologies.

a) Biopsy Procedure:

- An open or needle biopsy of the affected muscle can be performed.[10]
- The sample should be taken from a clinically affected but not yet purulent area to avoid non-diagnostic necrotic tissue.
- A portion of the fresh tissue should be sent for culture, and the remainder fixed in formalin for histopathology.

b) Histopathological Analysis:

- Process the fixed tissue and embed in paraffin.
- Cut thin sections (4-5 μm) and stain with Hematoxylin and Eosin (H&E).
- Examine under a microscope for features of myositis, including:
 - Infiltration of inflammatory cells (neutrophils, lymphocytes, macrophages).
 - Muscle fiber necrosis and degeneration.
 - Edema.
 - In later stages, abscess formation with a central area of liquefactive necrosis surrounded by a fibrous capsule.[16]

Diagnostic Imaging

a) Magnetic Resonance Imaging (MRI)

Objective: To visualize the extent of muscle inflammation, detect abscess formation, and guide aspiration or surgical drainage. MRI is the most sensitive imaging modality for pyomyositis.[17][18]

Protocol:

- Sequences:
 - T1-weighted images: Show normal muscle anatomy. In pyomyositis, affected muscles may appear isointense or slightly hyperintense.[19] A rim of increased signal intensity may be seen around an abscess.[17]
 - T2-weighted/Short-Tau Inversion Recovery (STIR) images: Highly sensitive for detecting muscle edema, which appears as high signal intensity.[17][20]
 - Contrast-enhanced T1-weighted images with fat suppression: Crucial for identifying abscesses, which typically show peripheral rim enhancement.[17][19]
- Findings:
 - Stage 1: Diffuse muscle enlargement and increased signal on T2-weighted images.[3]
 - Stage 2: A well-defined, rim-enhancing fluid collection (abscess) is visible.[3]
 - Stage 3: Multiple abscesses and signs of spread to adjacent tissues may be present.

b) Ultrasound

Objective: To provide a rapid, non-invasive assessment of superficial muscle groups and guide fluid aspiration.

Protocol:

- Use a high-frequency linear transducer for most applications.[21][22]
- Scan the affected area in two orthogonal planes.[21]
- Findings:

- Early stage: Hypoechoic, enlarged muscle with loss of normal fibrillar architecture.
- Abscess formation: A complex, hypoechoic or anechoic fluid collection with irregular borders and posterior acoustic enhancement.[23] Internal debris or septations may be present.[23]
- Color Doppler: Can be used to assess for hyperemia in the surrounding tissues and to identify adjacent vascular structures to be avoided during aspiration.[21][24] The abscess cavity itself will be avascular.[23]

Conclusion

The clinical presentation of pyomyositis exhibits clear distinctions between tropical and temperate regions. In tropical areas, it is predominantly a disease of healthy young males, while in temperate climates, it is more often associated with immunocompromised states and chronic illnesses. While *Staphylococcus aureus* remains the primary pathogen in both settings, the microbial landscape in temperate pyomyositis is more diverse. A high index of suspicion, coupled with appropriate imaging and microbiological investigations, is essential for early diagnosis and management. The experimental protocols outlined in this guide provide a framework for the accurate diagnosis of pyomyositis, which is critical for improving patient outcomes and for the continued development of effective antimicrobial therapies. Further research is needed to fully elucidate the pathogenic mechanisms underlying the geographical variations of this re-emerging infectious disease.

Need Custom Synthesis?

BenchChem offers custom synthesis for rare earth carbides and specific isotopic labeling.

Email: info@benchchem.com or [Request Quote Online](#).

References

- 1. Pyomyositis - Wikipedia [en.wikipedia.org]
- 2. Abscess Evaluation | Sonoguide [acep.org]
- 3. MRI of myositis and other urgent muscle-related disorders - PMC [pmc.ncbi.nlm.nih.gov]
- 4. orpha.net [orpha.net]

- 5. Clinical Characteristics and Management of Children and Adolescents Hospitalized With Pyomyositis - PMC [pmc.ncbi.nlm.nih.gov]
- 6. Laboratory Diagnosis of Streptococcus pyogenes (group A streptococci) - Streptococcus pyogenes - NCBI Bookshelf [ncbi.nlm.nih.gov]
- 7. microbenotes.com [microbenotes.com]
- 8. m.youtube.com [m.youtube.com]
- 9. Aspiration And Culture In Pyomyositis: Confirming Bacterial Involvement - Klarity Health Library [my.klarity.health]
- 10. Muscle biopsies in dermatomyositis and polymyositis: practical relevance of analyzing different levels of histological sections of the same muscular compartment – Brazilian Journal of Pathology and Laboratory Medicine [jbpm.org.br]
- 11. Pyomyositis | MSF Medical Guidelines [medicalguidelines.msf.org]
- 12. my.clevelandclinic.org [my.clevelandclinic.org]
- 13. Pyomyositis | Johns Hopkins ABX Guide [hopkinsguides.com]
- 14. Case report: Abscesses in children caused by invasive group A Streptococcus - PMC [pmc.ncbi.nlm.nih.gov]
- 15. Clinical Considerations for Group A Streptococcus | Group A Strep | CDC [cdc.gov]
- 16. Pyomyositis and Infectious Myositis: A Comprehensive, Single-Center Retrospective Study - PMC [pmc.ncbi.nlm.nih.gov]
- 17. droracle.ai [droracle.ai]
- 18. droracle.ai [droracle.ai]
- 19. pubs.rsna.org [pubs.rsna.org]
- 20. Magnetic resonance imaging of musculoskeletal infections - PMC [pmc.ncbi.nlm.nih.gov]
- 21. accessmedicine.mhmedical.com [accessmedicine.mhmedical.com]
- 22. High-resolution ultrasound in the evaluation of musculoskeletal infections - PMC [pmc.ncbi.nlm.nih.gov]
- 23. radiopaedia.org [radiopaedia.org]
- 24. youtube.com [youtube.com]
- To cite this document: BenchChem. [A Comparative Analysis of Tropical and Temperate Pyomyositis: A Technical Guide]. BenchChem, [2025]. [Online PDF]. Available at: [https://www.benchchem.com/product/b1172056#clinical-presentation-of-tropical-vs-temperate-pyomyositis]

Disclaimer & Data Validity:

The information provided in this document is for Research Use Only (RUO) and is strictly not intended for diagnostic or therapeutic procedures. While BenchChem strives to provide accurate protocols, we make no warranties, express or implied, regarding the fitness of this product for every specific experimental setup.

Technical Support: The protocols provided are for reference purposes. Unsure if this reagent suits your experiment? [[Contact our Ph.D. Support Team for a compatibility check](#)]

Need Industrial/Bulk Grade? [Request Custom Synthesis Quote](#)

BenchChem

Our mission is to be the trusted global source of essential and advanced chemicals, empowering scientists and researchers to drive progress in science and industry.

Contact

Address: 3281 E Guasti Rd

Ontario, CA 91761, United States

Phone: (601) 213-4426

Email: info@benchchem.com