

A Comparative Analysis of Thallium-201 SPECT and PET in Glioma Grading

Author: BenchChem Technical Support Team. **Date:** December 2025

Compound of Interest

Compound Name: Thallium-201

Cat. No.: B079191

[Get Quote](#)

The accurate grading of gliomas is paramount for determining prognosis and guiding therapeutic strategies. While histological analysis remains the gold standard, non-invasive imaging techniques play a crucial role in pre-surgical assessment, biopsy guidance, and monitoring treatment response. Among the functional imaging modalities, **Thallium-201** Single Photon Emission Computed Tomography (SPECT) and Positron Emission Tomography (PET) have been extensively evaluated for their ability to differentiate between low-grade and high-grade gliomas. This guide provides a comparative overview of their efficacy, supported by experimental data and detailed methodologies.

Quantitative Comparison of Diagnostic Performance

The diagnostic accuracy of an imaging modality in glioma grading is typically assessed by its sensitivity, specificity, and overall accuracy in distinguishing high-grade from low-grade tumors. The following table summarizes the performance metrics for **Thallium-201** SPECT and various PET tracers as reported in the literature. It is important to note that direct head-to-head comparisons in a single study are not always available, and performance can vary based on the specific tracer used in PET imaging.

Imaging Modality	Tracer	Sensitivity	Specificity	Accuracy	Key Findings & Citations
SPECT	Thallium-201 (²⁰¹ Tl)	82.7% - 94%	83.3% - 100%	82.8% - 89%	Can predict glioma grade with high accuracy; a Thallium Index greater than 1.5 is often indicative of high-grade malignancy. [1] [2] [3]
PET	¹⁸ F-FDG	63% - 78%	87% - 89%	~75%	Limited by high glucose uptake in normal brain tissue, leading to lower sensitivity compared to amino acid tracers. [4] [5] [6] [7]

PET	^{11}C -MET	92% - 94%	55% - 78%	~85%	Superior to ^{18}F -FDG PET for detecting recurrence in low-grade gliomas and can predict prognosis. [6] [7] [8] [9] [10]
PET	^{18}F -FET	88%	57% - 78%	~83%	Demonstrate significantly higher diagnostic performance for the diagnosis of brain tumors compared to FDG-PET. [5] [6] [7] [11]
PET	^{18}F -DOPA	85% - 88%	70% - 73%	~80%	Shows high sensitivity for glioma grading, with higher uptake generally seen in high-grade tumors. [6] [11] [12] [13]

Note: The reported values are ranges compiled from multiple studies and should be interpreted in the context of each individual study's design and patient population.

Experimental Protocols

The methodologies for **Thallium-201** SPECT and PET in glioma grading studies share a common framework but differ in the specifics of the radiotracer and imaging acquisition.

Thallium-201 SPECT Protocol

A typical experimental protocol for **Thallium-201** SPECT in glioma grading involves the following steps:

- **Patient Preparation:** Patients are typically advised to fast for at least 4 hours prior to the scan. No specific premedication is usually required.
- **Radiotracer Administration:** A dose of 2-4 mCi (74-148 MBq) of **Thallium-201** chloride is administered intravenously.
- **Imaging Acquisition:** Imaging is performed 15-30 minutes post-injection. SPECT data is acquired using a gamma camera equipped with a low-energy, high-resolution collimator. A 360° rotation is performed with projections acquired every 3-6 degrees.
- **Image Reconstruction and Analysis:** The acquired data is reconstructed using filtered back-projection or iterative reconstruction algorithms. For quantitative analysis, a "Thallium Index" is often calculated. This is the ratio of the mean tracer uptake in the tumor to the mean uptake in a contralateral normal brain region (e.g., the homologous contralateral hemisphere).^{[1][14][15][16]} A higher index is generally correlated with a higher tumor grade.

PET Protocol for Glioma Grading (General)

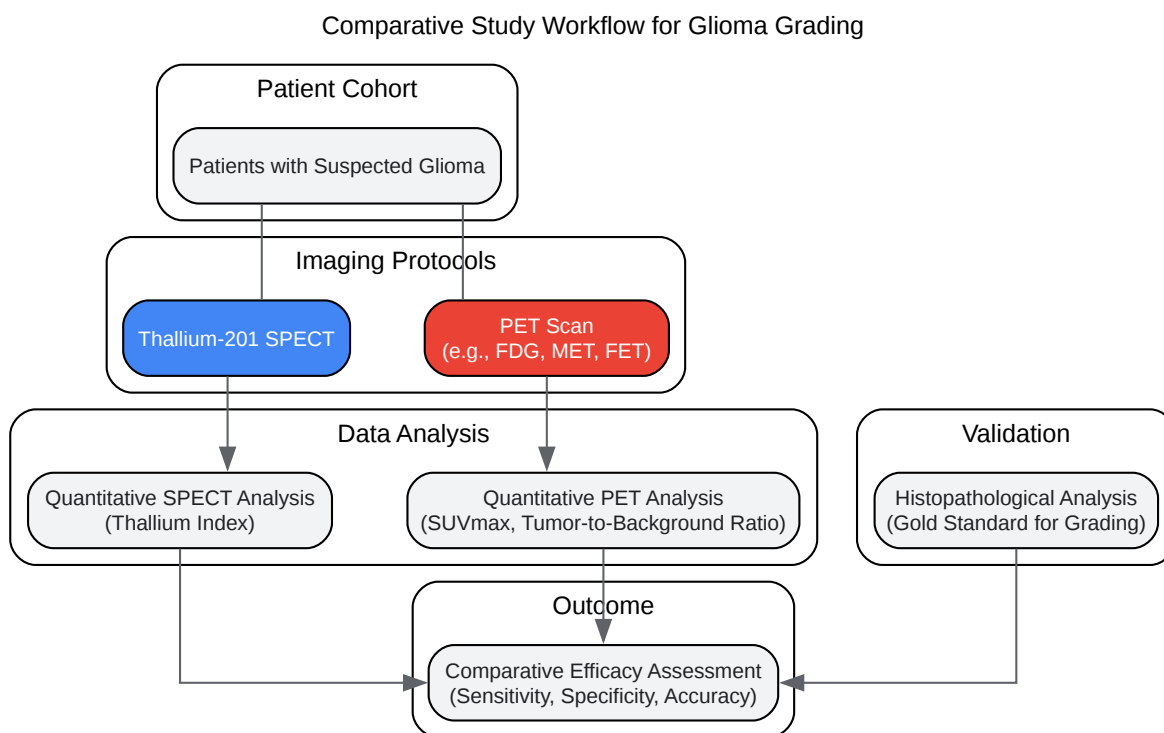
The protocol for PET imaging varies depending on the specific tracer used (e.g., ^{18}F -FDG, ^{11}C -MET, ^{18}F -FET). A generalized protocol is as follows:

- **Patient Preparation:** For ^{18}F -FDG PET, patients are required to fast for at least 6 hours to ensure low blood glucose levels. For amino acid PET tracers like ^{11}C -MET and ^{18}F -FET, fasting requirements may be less stringent.
- **Radiotracer Administration:** The radiotracer is administered intravenously. The typical dose for ^{18}F -FDG is 5-10 mCi (185-370 MBq), while doses for amino acid tracers can vary.

- **Uptake Period:** Following injection, there is a waiting period to allow for tracer distribution and uptake. This is typically 30-60 minutes for ^{18}F -FDG and can be shorter for some amino acid tracers.
- **Imaging Acquisition:** The patient is positioned in the PET scanner, and data is acquired for 15-30 minutes. For dynamic PET studies, imaging may begin immediately after tracer injection to measure tracer kinetics over time.
- **Image Reconstruction and Analysis:** Images are reconstructed, and tracer uptake is quantified. The most common metric is the Standardized Uptake Value (SUV), which normalizes the tracer concentration in a region of interest to the injected dose and patient's body weight. For glioma grading, the maximum SUV (SUVmax) within the tumor or the ratio of tumor SUV to normal brain tissue SUV is often used.[\[10\]](#)[\[12\]](#)[\[17\]](#)

Mechanisms of Tracer Uptake and Experimental Workflow

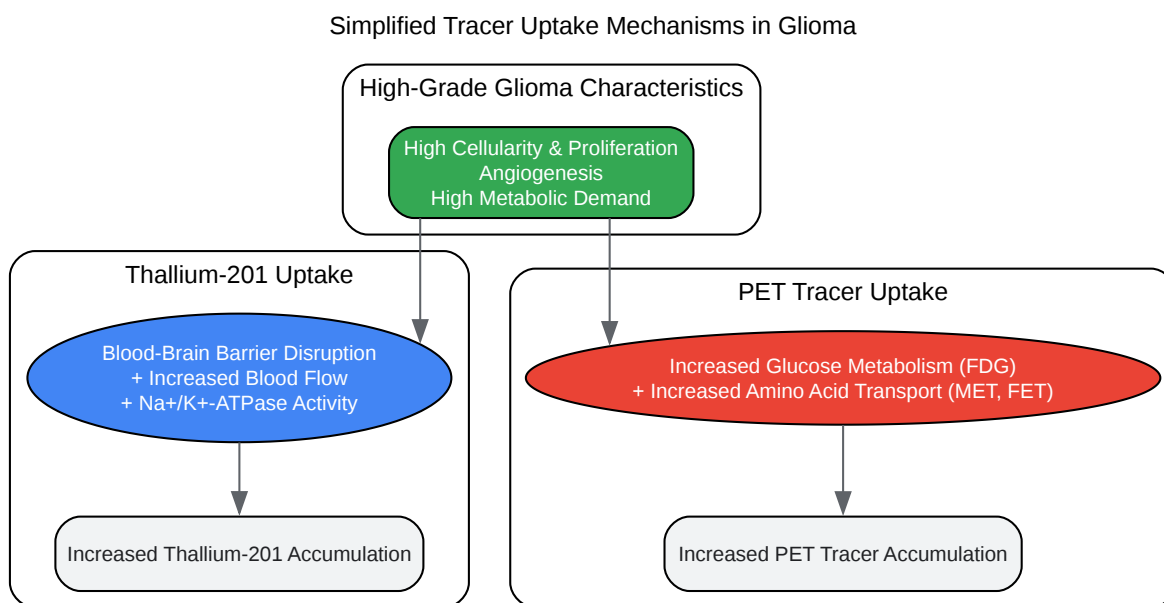
The underlying biological principles governing tracer uptake differ between **Thallium-201** and the various PET radiopharmaceuticals. These differences are key to understanding their respective efficacies in glioma grading.



[Click to download full resolution via product page](#)

Workflow of a comparative imaging study for glioma grading.

The diagram above illustrates a typical workflow for a clinical study comparing **Thallium-201** SPECT and PET for glioma grading. Patients with suspected gliomas undergo both imaging modalities. The resulting images are quantitatively analyzed, and the findings are compared against the definitive histopathological grade obtained from a biopsy or surgical resection.



[Click to download full resolution via product page](#)

Simplified mechanisms of tracer uptake in high-grade gliomas.

This diagram outlines the primary factors driving the uptake of **Thallium-201** and common PET tracers in high-grade gliomas. **Thallium-201**, a potassium analog, accumulates in tumor cells due to a combination of increased blood flow, disruption of the blood-brain barrier, and elevated Na⁺/K⁺-ATPase pump activity. In contrast, PET tracers like ¹⁸F-FDG reflect the increased glucose metabolism of tumor cells, while amino acid tracers such as ¹¹C-MET and ¹⁸F-FET are taken up via overexpressed amino acid transporters, indicating increased protein synthesis and cellular proliferation.[18][19][20][21]

Conclusion

Both **Thallium-201** SPECT and PET imaging provide valuable metabolic information for the non-invasive grading of gliomas. Historically, **Thallium-201** SPECT has demonstrated good accuracy in differentiating low-grade from high-grade lesions.[1][4][14] However, the advent of PET, particularly with amino acid tracers, has offered improved diagnostic performance, especially in terms of sensitivity.[5][7] Amino acid PET tracers generally provide better tumor-to-

background contrast compared to ^{18}F -FDG, which is hampered by the high physiological glucose uptake in the brain.[21][22]

The choice of imaging modality may depend on institutional availability and specific clinical questions. While **Thallium-201** SPECT can be a reliable tool, especially where PET is not readily accessible, amino acid PET is increasingly considered the state-of-the-art functional imaging modality for glioma management, offering superior delineation of tumor extent and more accurate grading.[18][21][23] Future research, including direct comparative studies and the development of novel PET tracers, will continue to refine the role of functional imaging in neuro-oncology.

Need Custom Synthesis?

BenchChem offers custom synthesis for rare earth carbides and specific isotopic labeling.

Email: info@benchchem.com or [Request Quote Online](#).

References

- 1. Use of thallium-201 SPECT to quantitate malignancy grade of gliomas - PubMed [pubmed.ncbi.nlm.nih.gov]
- 2. researchgate.net [researchgate.net]
- 3. researchgate.net [researchgate.net]
- 4. Thallium-201 SPECT and positron emission tomography equal predictors of glioma grade and recurrence - PubMed [pubmed.ncbi.nlm.nih.gov]
- 5. Performance of ^{18}F -FET versus ^{18}F -FDG-PET for the diagnosis and grading of brain tumors: systematic review and meta-analysis - PMC [pmc.ncbi.nlm.nih.gov]
- 6. Frontiers | Diagnostic Accuracy of PET for Differentiating True Glioma Progression From Post Treatment-Related Changes: A Systematic Review and Meta-Analysis [frontiersin.org]
- 7. Performance of ^{18}F -FDG, ^{11}C -Methionine, and ^{18}F -FET PET for Glioma Grading: A Meta-analysis - PubMed [pubmed.ncbi.nlm.nih.gov]
- 8. Clinical usefulness of ^{11}C -MET PET and ^{201}Tl SPECT for differentiation of recurrent glioma from radiation necrosis - PubMed [pubmed.ncbi.nlm.nih.gov]
- 9. A comparison study of ^{11}C -methionine and ^{18}F -fluorodeoxyglucose positron emission tomography-computed tomography scans in evaluation of patients with recurrent brain

tumors - PMC [pmc.ncbi.nlm.nih.gov]

- 10. 11C-methionine PET for grading and prognostication in gliomas: a comparison study with 18F-FDG PET and contrast enhancement on MRI - PubMed [pubmed.ncbi.nlm.nih.gov]
- 11. ajnr.org [ajnr.org]
- 12. jnm.snmjournals.org [jnm.snmjournals.org]
- 13. mdpi.com [mdpi.com]
- 14. Contribution of thallium-201-SPECT to the grading of tumorous alterations of the brain - PubMed [pubmed.ncbi.nlm.nih.gov]
- 15. Thallium-201 SPECT imaging of brain tumors: methods and results - PubMed [pubmed.ncbi.nlm.nih.gov]
- 16. Thallium-201 SPECT in brain gliomas: Quantitative assessment in differential diagnosis between tumor recurrence and radionecrosis - PubMed [pubmed.ncbi.nlm.nih.gov]
- 17. The Additional Value of 18F-FDG PET and MRI in Patients with Glioma: A Review of the Literature from 2015 to 2020 - PMC [pmc.ncbi.nlm.nih.gov]
- 18. A Systematic Review of Amino Acid PET Imaging in Adult-Type High-Grade Glioma Surgery: A Neurosurgeon's Perspective - PMC [pmc.ncbi.nlm.nih.gov]
- 19. Approaches to PET Imaging of Glioblastoma. | Read by QxMD [read.qxmd.com]
- 20. Approaches to PET Imaging of Glioblastoma - PMC [pmc.ncbi.nlm.nih.gov]
- 21. PET Imaging in Glioblastoma: Use in Clinical Practice - Glioblastoma - NCBI Bookshelf [ncbi.nlm.nih.gov]
- 22. mdpi.com [mdpi.com]
- 23. academic.oup.com [academic.oup.com]
- To cite this document: BenchChem. [A Comparative Analysis of Thallium-201 SPECT and PET in Glioma Grading]. BenchChem, [2025]. [Online PDF]. Available at: [https://www.benchchem.com/product/b079191#comparative-efficacy-of-thallium-201-spect-and-pet-in-glioma-grading]

Disclaimer & Data Validity:

The information provided in this document is for Research Use Only (RUO) and is strictly not intended for diagnostic or therapeutic procedures. While BenchChem strives to provide accurate protocols, we make no warranties, express or implied, regarding the fitness of this product for every specific experimental setup.

Technical Support: The protocols provided are for reference purposes. Unsure if this reagent suits your experiment? [[Contact our Ph.D. Support Team for a compatibility check](#)]

Need Industrial/Bulk Grade? [Request Custom Synthesis Quote](#)

BenchChem

Our mission is to be the trusted global source of essential and advanced chemicals, empowering scientists and researchers to drive progress in science and industry.

Contact

Address: 3281 E Guasti Rd

Ontario, CA 91761, United States

Phone: (601) 213-4426

Email: info@benchchem.com