

# A Comparative Analysis of M-mode and 2D Echocardiography in Guiding Pericardiocentesis

**Author:** BenchChem Technical Support Team. **Date:** December 2025

## Compound of Interest

Compound Name: M-MoDE-A (2)

Cat. No.: B15144752

[Get Quote](#)

For Researchers, Scientists, and Drug Development Professionals: A Guide to Understanding the Roles of Echocardiographic Modalities in a Critical Cardiac Procedure

Pericardiocentesis, the percutaneous drainage of fluid from the pericardial sac, is a potentially life-saving procedure for patients with cardiac tamponade or large pericardial effusions. Echocardiography is the cornerstone of this procedure, providing essential imaging for diagnosis, guidance, and post-procedural assessment. While both M-mode and two-dimensional (2D) echocardiography are integral to the management of pericardial effusions, they serve distinct and complementary roles. This guide provides a comparative analysis of their applications, supported by procedural data, to clarify their respective utilities in guiding pericardiocentesis.

## The Distinct Roles of M-mode and 2D Echocardiography

Historically, M-mode echocardiography was a primary tool for detecting pericardial effusion. However, with the advent of 2D echocardiography, the roles of these modalities have become more specialized. Today, 2D echo is the undisputed standard for guiding the pericardiocentesis needle, while M-mode is primarily relegated to the initial diagnosis and hemodynamic assessment of the effusion.

M-mode echocardiography offers a one-dimensional, "ice-pick" view of the heart, providing high temporal resolution of cardiac structures along a single line of sight. Its primary utility in the

context of pericardial effusion is diagnostic, specifically in identifying:

- Presence of Pericardial Effusion: M-mode can detect an echo-free space between the epicardium and pericardium.[1]
- Hemodynamic Significance: It is highly sensitive in detecting the signs of cardiac tamponade, such as right ventricular (RV) diastolic collapse and exaggerated respiratory variation in ventricular dimensions.[2][3]

However, M-mode's single-dimensional view makes it unsuitable for guiding the pericardiocentesis needle, as it provides no spatial information regarding the needle's position relative to surrounding cardiac and extracardiac structures.

2D echocardiography, in contrast, provides a real-time, two-dimensional cross-sectional view of the heart and surrounding structures. This spatial orientation is critical for safely and effectively guiding the pericardiocentesis needle. Its key advantages in this procedure include:

- Optimal Puncture Site Selection: 2D echo allows for a comprehensive survey of the pericardial effusion, enabling the operator to identify the location with the largest fluid accumulation that is closest to the skin and avoids vital structures.[4][5]
- Real-Time Needle Visualization: The operator can visualize the needle tip in real-time as it traverses the chest wall and enters the pericardial space, minimizing the risk of cardiac or vascular injury.
- Confirmation of Catheter Placement: After initial puncture, 2D echo can be used to confirm the correct placement of the guidewire and drainage catheter within the pericardial sac.

## Procedural Outcomes: The Efficacy of 2D Echo-Guided Pericardiocentesis

The use of 2D echocardiography to guide pericardiocentesis has dramatically improved the safety and success rate of the procedure compared to the historical "blind" approach. The following table summarizes quantitative data from studies on 2D echo-guided pericardiocentesis.

Outcome Measure	Reported Values	Citation(s)
Success Rate	97% - 99%	
Major Complication Rate	1.2% - 3.2%	
Minor Complication Rate	~14%	

Major complications can include cardiac chamber laceration, injury to thoracic vessels, and death, with some studies reporting a need for emergency surgery in a small percentage of cases. Minor complications may include pleural puncture and pneumothorax.

## Experimental Protocols: The 2D Echo-Guided Pericardiocentesis Procedure

The following is a generalized protocol for performing a 2D echo-guided pericardiocentesis. This protocol is intended for informational purposes and should not be considered a substitute for formal medical training and institutional guidelines.

### 1. Pre-Procedural Assessment:

- A comprehensive 2D echocardiogram is performed to confirm the presence and size of the pericardial effusion, assess for signs of cardiac tamponade, and identify the optimal puncture site.
- The patient's clinical status, including vital signs and coagulation parameters, is evaluated.

### 2. Patient Preparation and Positioning:

- The patient is typically placed in a semi-recumbent position.
- The chosen puncture site is prepped and draped in a sterile fashion.
- Local anesthesia is administered.

### 3. Needle Insertion and Guidance:

- Under continuous 2D echo guidance, an introducer needle is inserted through the skin and advanced towards the pericardial space.
- The operator visualizes the needle tip in real-time to ensure a safe trajectory, avoiding the myocardium, coronary arteries, and other vital structures.

#### 4. Confirmation of Pericardial Access:

- Once the needle enters the pericardial space, the return of pericardial fluid confirms its position.
- A small amount of agitated saline can be injected through the needle and visualized with 2D echo (a "bubble study") to definitively confirm intrapericardial placement.

#### 5. Guidewire and Catheter Placement:

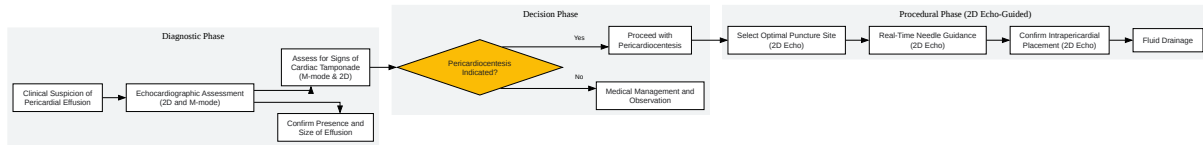
- A guidewire is advanced through the needle into the pericardial space.
- The needle is removed, and a drainage catheter is advanced over the guidewire.
- The position of the catheter is confirmed with 2D echo.

#### 6. Fluid Drainage and Post-Procedural Care:

- The pericardial fluid is aspirated.
- The catheter may be left in place for continued drainage.
- A post-procedural echocardiogram is performed to assess for residual effusion and any complications.

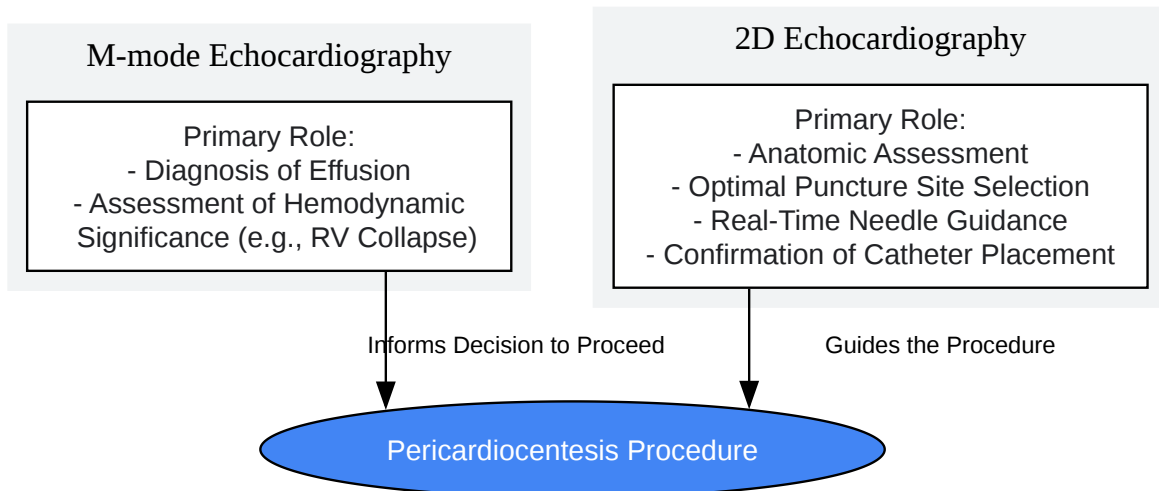
## Visualization of Procedural Workflow

The following diagrams illustrate the decision-making process and procedural workflow for managing a patient with a suspected pericardial effusion.



[Click to download full resolution via product page](#)

**Figure 1.** Workflow for the management of pericardial effusion.



[Click to download full resolution via product page](#)

**Figure 2.** Distinct roles of M-mode and 2D echo in pericardiocentesis.

## Conclusion

In modern clinical practice, M-mode and 2D echocardiography are not competing modalities for guiding pericardiocentesis but rather complementary tools used at different stages of patient management. M-mode echocardiography is invaluable for the initial diagnosis and hemodynamic assessment of pericardial effusions, providing critical information that informs the decision to proceed with drainage. However, the pericardiocentesis procedure itself is exclusively guided by 2D echocardiography, which offers the necessary spatial visualization to ensure the safety and efficacy of the intervention. The high success rates and low complication rates of contemporary pericardiocentesis are a direct result of the widespread adoption of 2D echo guidance. For researchers and professionals in drug development, understanding these distinct roles is crucial when evaluating clinical trial data or designing studies involving patients with pericardial diseases.

#### Need Custom Synthesis?

BenchChem offers custom synthesis for rare earth carbides and specific isotopic labeling.

Email: [info@benchchem.com](mailto:info@benchchem.com) or [Request Quote Online](#).

## References

- 1. academic.oup.com [academic.oup.com]
- 2. Echocardiographic Evaluation of Pericardial Effusion and Cardiac Tamponade - PMC [pmc.ncbi.nlm.nih.gov]
- 3. Transthoracic M-mode Echocardiography Demonstrating Cardiac Tamponade - PMC [pmc.ncbi.nlm.nih.gov]
- 4. Pericardiocentesis assisted by two-dimensional echocardiography - PubMed [pubmed.ncbi.nlm.nih.gov]
- 5. Pericardiocentesis in cardiac tamponade: indications and practical aspects [escardio.org]
- To cite this document: BenchChem. [A Comparative Analysis of M-mode and 2D Echocardiography in Guiding Pericardiocentesis]. BenchChem, [2025]. [Online PDF]. Available at: [<https://www.benchchem.com/product/b15144752#a-comparative-analysis-of-m-mode-and-2d-echo-in-guiding-pericardiocentesis>]

---

#### Disclaimer & Data Validity:

The information provided in this document is for Research Use Only (RUO) and is strictly not intended for diagnostic or therapeutic procedures. While BenchChem strives to provide accurate protocols, we make no warranties, express or implied, regarding the fitness of this product for every specific experimental setup.

**Technical Support:** The protocols provided are for reference purposes. Unsure if this reagent suits your experiment? [[Contact our Ph.D. Support Team for a compatibility check](#)]

**Need Industrial/Bulk Grade?** [Request Custom Synthesis Quote](#)

## BenchChem

Our mission is to be the trusted global source of essential and advanced chemicals, empowering scientists and researchers to drive progress in science and industry.

### Contact

Address: 3281 E Guasti Rd  
Ontario, CA 91761, United States  
Phone: (601) 213-4426  
Email: [info@benchchem.com](mailto:info@benchchem.com)