

A Comparative Analysis of Computed Tomography and Ultrasound Imaging in Biliary System Evaluation

Author: BenchChem Technical Support Team. **Date:** December 2025

Compound of Interest

Compound Name: *Iotroxic Acid*

Cat. No.: *B1212916*

[Get Quote](#)

In the diagnostic landscape of biliary system pathologies, particularly gallbladder diseases, both Computed Tomography (CT) and Ultrasound Imaging stand as crucial modalities. While historically, contrast agents like **iotroxic acid** were employed in X-ray based cholangiography, modern practice predominantly relies on non-contrast or intravenously-enhanced CT and ultrasound for initial and detailed assessments. This guide provides a comparative analysis of these two imaging techniques, supported by experimental data, to assist researchers, scientists, and drug development professionals in understanding their respective roles and performance.

Diagnostic Performance: A Quantitative Comparison

Ultrasound is widely regarded as the primary imaging modality for suspected gallbladder disease due to its accessibility, cost-effectiveness, and lack of ionizing radiation.^[1] However, CT is frequently utilized when ultrasound findings are equivocal or when a broader evaluation of abdominal pathology is necessary.^[1] Several studies have compared the diagnostic accuracy of these two methods, particularly in the context of acute cholecystitis and biliary obstruction.

The following tables summarize the quantitative data on the diagnostic performance of CT and ultrasound from various studies.

Table 1: Diagnostic Accuracy for Acute Cholecystitis

Study/Parameter	Sensitivity	Specificity	Positive Predictive Value (PPV)	Negative Predictive Value (NPV)
Wertz et al. (2018)[2]				
CT	85%	100%	100%	90%
Ultrasound	68%	100%	100%	78%
Fike et al. (as cited in Tan et al., 2018)[3]				
CT	92%	-	-	-
Ultrasound	79%	-	-	-
Tan et al. (2018) [3]				
CT	45%	79%	-	-
Ultrasound	47%	84%	-	-

Table 2: Diagnostic Accuracy for Biliary Obstruction

Study/Parameter	Sensitivity	Specificity	Positive Predictive Value (PPV)	Diagnostic Accuracy
Adedin et al. (2012)				
CT (for cause of obstruction)	96.5%	-	100%	96.5%
Ultrasound (for cause of obstruction)	68.4%	-	100%	68.4%
Mohapatra et al. (2024)				
CT (for benign lesions)	100%	93.1%	93.7%	96%
Ultrasound (for benign lesions)	100%	86.2%	-	-
CT (for malignant lesions)	93.1%	100%	-	-
Ultrasound (for malignant lesions)	86.2%	100%	-	-

Table 3: Diagnostic Accuracy for Choledocholithiasis (Bile Duct Stones)

Study/Parameter	Sensitivity	Specificity	Positive Predictive Value (PPV)	Diagnostic Accuracy
Mohapatra et al. (2024)				
CT	100%	97.2%	93.3%	98%
Ultrasound	100%	86%	73%	96%
Hasan et al. (2023)				
CT (for benign conditions)	87.18%	81.25%	-	84.51%
Ultrasound (for benign conditions)	84.62%	90.63%	-	-

Experimental Protocols

The methodologies employed in the cited studies provide a framework for understanding how these comparative data were generated.

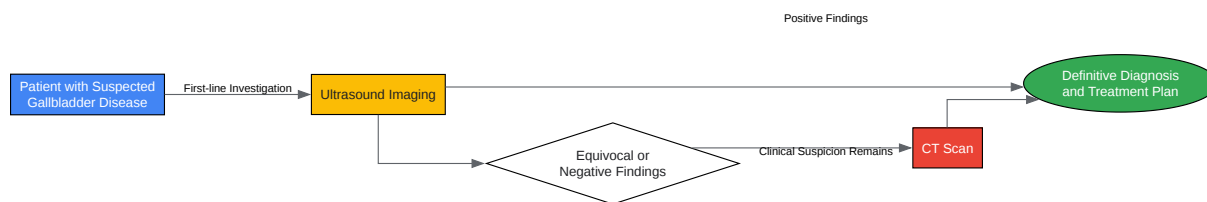
- **Study Design:** The majority of the studies were retrospective analyses of patient data who underwent both ultrasound and CT scans for suspected biliary pathology. The final diagnosis was often confirmed by surgical findings and histopathology, which served as the gold standard.
- **Patient Population:** Patients typically presented with symptoms such as right upper quadrant pain, jaundice, or other signs suggestive of acute cholecystitis or biliary obstruction.
- **Imaging Techniques:**
 - **Ultrasound:** Abdominal ultrasound was generally the initial imaging modality. Key findings for acute cholecystitis included gallbladder wall thickening, pericholecystic fluid, and a

sonographic Murphy's sign. For biliary obstruction, dilation of the bile ducts was a primary indicator.

- Computed Tomography (CT): CT scans were often performed with intravenous contrast. Findings suggestive of acute cholecystitis included gallbladder wall thickening, pericholecystic inflammation, and gallbladder distention. For biliary obstruction, CT is effective in identifying the level and cause of the obstruction.
- Data Analysis: The sensitivity, specificity, positive predictive value (PPV), and negative predictive value (NPV) of each imaging modality were calculated by comparing the imaging findings with the final diagnosis. Statistical tests were used to determine the significance of the differences in diagnostic performance.

Diagnostic Workflow

The following diagram illustrates a typical diagnostic workflow for a patient with suspected gallbladder disease, highlighting the roles of ultrasound and CT.



[Click to download full resolution via product page](#)

Diagnostic workflow for gallbladder disease.

Discussion and Conclusion

The compiled data indicates that while ultrasound is an excellent initial diagnostic tool, particularly for detecting gallstones, CT often demonstrates higher sensitivity for diagnosing

acute cholecystitis and determining the cause of biliary obstruction. CT is particularly valuable in cases where ultrasound results are inconclusive or when complications are suspected.

It is important to note that the diagnostic accuracy of both modalities can be influenced by factors such as the patient's body habitus and the operator's experience, especially with ultrasound. The choice between ultrasound and CT should be guided by the clinical presentation, the specific information required, and institutional protocols. In many clinical scenarios, these two imaging modalities are complementary rather than mutually exclusive. While specific cross-validation studies involving **iotroxic acid**-enhanced CT are not prevalent in recent literature, the comparative data for modern CT and ultrasound techniques provide a robust foundation for decision-making in biliary imaging.

Need Custom Synthesis?

BenchChem offers custom synthesis for rare earth carbides and specific isotopic labeling.

Email: info@benchchem.com or [Request Quote Online](#).

References

- 1. droracle.ai [droracle.ai]
- 2. auntminnie.com [auntminnie.com]
- 3. Acute Cholecystitis: Computed Tomography (CT) versus Ultrasound (US) [scirp.org]
- To cite this document: BenchChem. [A Comparative Analysis of Computed Tomography and Ultrasound Imaging in Biliary System Evaluation]. BenchChem, [2025]. [Online PDF]. Available at: [<https://www.benchchem.com/product/b1212916#cross-validation-of-iotroxic-acid-ct-with-ultrasound-imaging>]

Disclaimer & Data Validity:

The information provided in this document is for Research Use Only (RUO) and is strictly not intended for diagnostic or therapeutic procedures. While BenchChem strives to provide accurate protocols, we make no warranties, express or implied, regarding the fitness of this product for every specific experimental setup.

Technical Support: The protocols provided are for reference purposes. Unsure if this reagent suits your experiment? [[Contact our Ph.D. Support Team for a compatibility check](#)]

Need Industrial/Bulk Grade? [Request Custom Synthesis Quote](#)

BenchChem

Our mission is to be the trusted global source of essential and advanced chemicals, empowering scientists and researchers to drive progress in science and industry.

Contact

Address: 3281 E Guasti Rd
Ontario, CA 91761, United States
Phone: (601) 213-4426
Email: info@benchchem.com