

A Comparative Analysis of ^{99m}Tc -Sestamibi and ^{18}F -FDG PET in Oncological Imaging

Author: BenchChem Technical Support Team. **Date:** December 2025

Compound of Interest

Compound Name: ^{99m}Tc -Sestamibi

Cat. No.: B1243785

[Get Quote](#)

For Researchers, Scientists, and Drug Development Professionals: An Objective Comparison of Two Key Radiotracers in Oncology

In the landscape of oncological imaging, both Technetium-99m Sestamibi (^{99m}Tc -Sestamibi) Single Photon Emission Computed Tomography (SPECT) and Fluorine-18 fluorodeoxyglucose (^{18}F -FDG) Positron Emission Tomography (PET) have emerged as critical tools for tumor detection, staging, and treatment response assessment. While ^{18}F -FDG PET is widely recognized for its ability to map glucose metabolism, ^{99m}Tc -Sestamibi offers a unique perspective on cellular mitochondrial function and perfusion. This guide provides a comprehensive, data-driven comparison of these two imaging modalities, offering insights into their respective mechanisms, clinical applications, and diagnostic performance across various cancer types.

At a Glance: Key Differences and Performance Metrics

The fundamental distinction between ^{99m}Tc -Sestamibi and ^{18}F -FDG lies in their mechanisms of uptake and the metabolic processes they visualize. ^{18}F -FDG, a glucose analog, is transported into cells via glucose transporters (GLUTs) and phosphorylated by hexokinase, effectively trapping it within metabolically active cells.^{[1][2][3]} This process is often upregulated in malignant tumors due to the Warburg effect. In contrast, ^{99m}Tc -Sestamibi, a lipophilic cation, accumulates in tissues with high mitochondrial content and negative plasma membrane

potentials, reflecting cellular viability and perfusion.[4][5][6] This differential uptake mechanism leads to distinct imaging patterns and clinical utilities.

Quantitative Performance Comparison

The following tables summarize the diagnostic performance of ^{99m}Tc-Sestamibi SPECT and ¹⁸F-FDG PET in various oncological applications based on published experimental data.

Table 1: Breast Cancer

Modality	Sensitivity	Specificity	Accuracy	Reference
^{99m} Tc-Sestamibi BSGI	86.1%	78.4%	84.7%	[2]
¹⁸ F-FDG PET/CT	78.3%	96.1%	81.5%	[2]
¹⁸ F-FDG PET/CT (Staging)	90.90%	90%	-	[7]

Table 2: Thyroid Cancer

Modality	Application	Sensitivity	Specificity	Reference
^{99m} Tc-Sestamibi	Differentiating Malignant Nodules	Same as ¹⁸ F-FDG	Lower than ¹⁸ F-FDG	[8]
¹⁸ F-FDG PET	Differentiating Malignant Nodules	Same as ^{99m} Tc-Sestamibi	Higher than ^{99m} Tc-Sestamibi	[8]
¹⁸ F-FDG PET	Metastatic Differentiated Thyroid Cancer	up to 85%	up to 95%	[9]

Table 3: Multiple Myeloma

Modality	Finding	Detection Rate	Reference
^{99m} Tc-Sestamibi SPECT/CT	Diffuse Bone Marrow Involvement	78%	[10] [11] [12]
¹⁸ F-FDG PET/CT	Diffuse Bone Marrow Involvement	58%	[10] [11] [12]
^{99m} Tc-Sestamibi SPECT/CT	Focal Lesions	54%	[10] [11] [12]
¹⁸ F-FDG PET/CT	Focal Lesions	81%	[10] [11] [12]
^{99m} Tc-Sestamibi	Bone Marrow Involvement	80%	[13]
¹⁸ F-FDG PET	Bone Marrow Involvement	100%	[13]
^{99m} Tc-Sestamibi	Soft Tissue Lesions	68.4%	[13]
¹⁸ F-FDG PET	Soft Tissue Lesions	89.5%	[13]
^{99m} Tc-Sestamibi	Skeletal Lesions	80%	[13]
¹⁸ F-FDG PET	Skeletal Lesions	93.3%	[13]

Table 4: Lung Cancer

Modality	Application	Sensitivity	Specificity	Reference
¹⁸ F-FDG PET	Diagnosing Lung Cancer (Endemic Infectious Disease Regions)	89%	61%	[14]
¹⁸ F-FDG PET	Diagnosing Lung Cancer (Non-Endemic Regions)	89%	77%	[14]
¹⁸ F-FDG PET/CT	Differentiating Benign and Malignant SPNs	89%	78%	[15]
¹⁸ F-FDG PET/CT	NSCLC Lymph Node Metastasis	78%	87%	[16]
¹⁸ F-FDG PET/CT	Bone Metastases in NSCLC	94.3%	98.8%	[17]

Signaling Pathways and Uptake Mechanisms

The uptake of these radiotracers is governed by distinct cellular signaling pathways, providing a window into the underlying biology of the tumor.

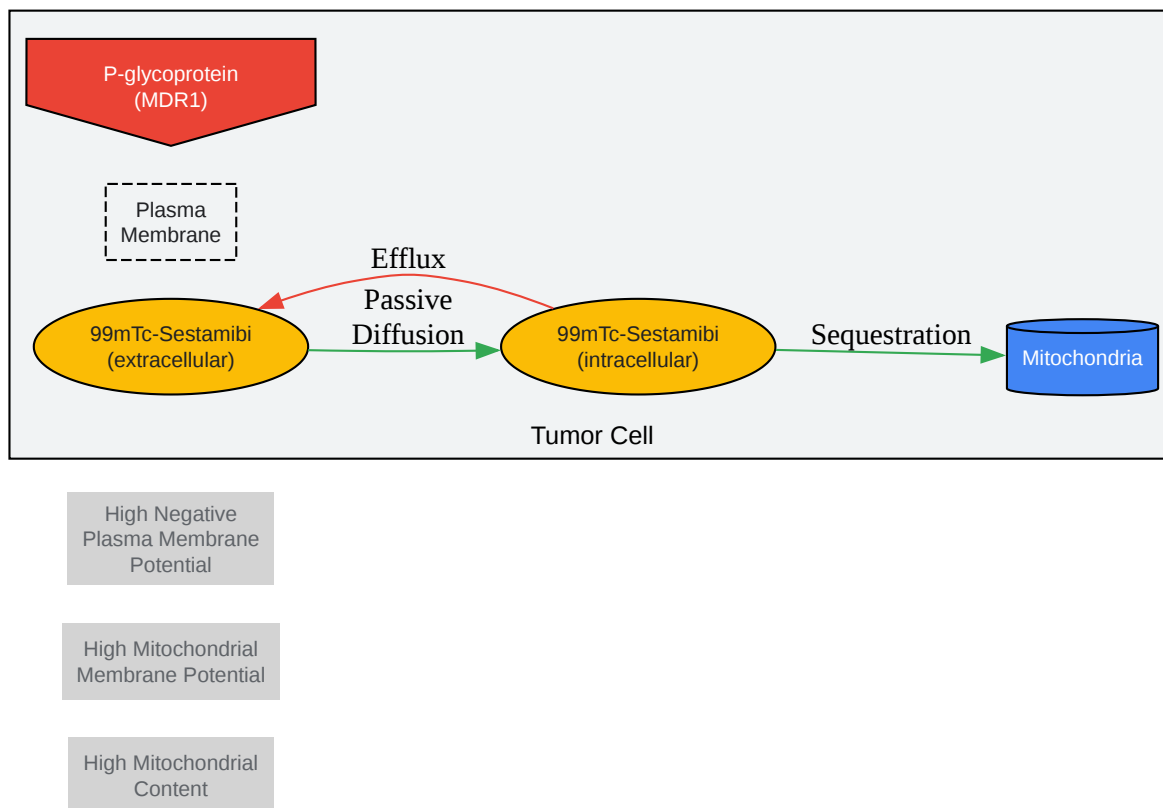


Figure 1: ^{99m}Tc-Sestamibi Uptake Pathway

[Click to download full resolution via product page](#)

Caption: Simplified diagram of **^{99m}Tc-Sestamibi** uptake and retention in a tumor cell.

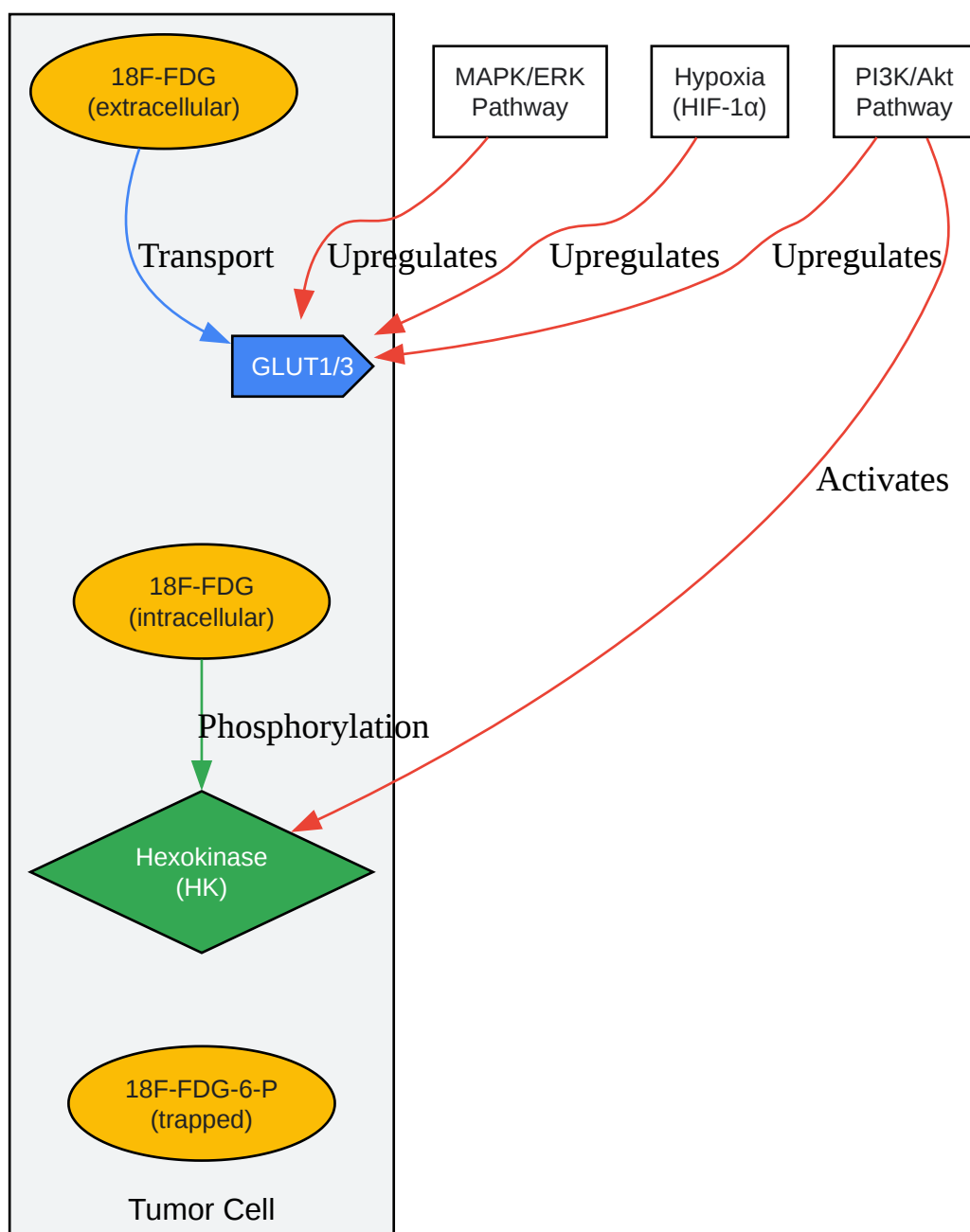


Figure 2: ¹⁸F-FDG Uptake and Signaling Pathways

[Click to download full resolution via product page](#)

Caption: Overview of ¹⁸F-FDG uptake and its regulation by key oncogenic signaling pathways.

Experimental Protocols

Standardized experimental protocols are crucial for ensuring the reproducibility and comparability of imaging data. Below are generalized methodologies for ^{99m}Tc -Sestamibi SPECT and ^{18}F -FDG PET studies in an oncological setting.

^{99m}Tc -Sestamibi SPECT/CT Protocol

A representative experimental workflow for a ^{99m}Tc -Sestamibi SPECT/CT study is outlined below.

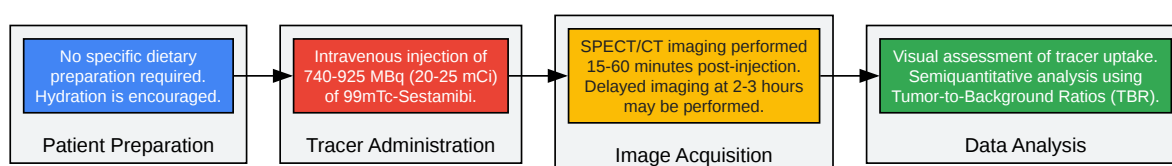


Figure 3: ^{99m}Tc -Sestamibi SPECT/CT Experimental Workflow

[Click to download full resolution via product page](#)

Caption: A typical experimental workflow for a **^{99m}Tc -Sestamibi** SPECT/CT scan in oncology.

Detailed Methodology:

- **Patient Preparation:** Generally, no specific dietary restrictions are required for ^{99m}Tc -Sestamibi scans. Patients are encouraged to be well-hydrated.
- **Radiotracer Administration:** A dose of 740-925 MBq (20-25 mCi) of ^{99m}Tc -Sestamibi is administered intravenously.
- **Image Acquisition:** Imaging is typically initiated 15 to 60 minutes after injection. For certain applications, such as parathyroid imaging, dual-phase imaging with an early scan at 15-20 minutes and a delayed scan at 2-3 hours is performed. SPECT/CT combines the functional data from SPECT with the anatomical detail of CT.
- **Image Analysis:** Images are evaluated visually for focal areas of increased tracer uptake. Semiquantitative analysis can be performed by calculating the tumor-to-background ratio (TBR) or tumor-to-normal tissue ratio.

^{18}F -FDG PET/CT Protocol

The experimental workflow for an ^{18}F -FDG PET/CT study requires more stringent patient preparation to ensure accurate metabolic assessment.

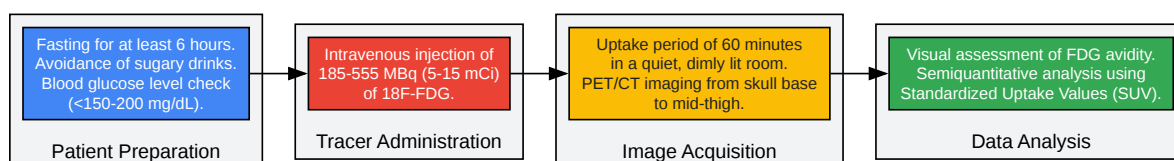


Figure 4: ^{18}F -FDG PET/CT Experimental Workflow

[Click to download full resolution via product page](#)

Caption: Standardized experimental workflow for an ^{18}F -FDG PET/CT scan in an oncological setting.

Detailed Methodology:

- **Patient Preparation:** Patients are required to fast for a minimum of 6 hours to reduce physiological glucose levels and insulin secretion.[1][3][18] Blood glucose levels should be checked prior to tracer injection and should ideally be below 150-200 mg/dL.[1][18] Strenuous physical activity should be avoided for 24 hours before the scan to minimize muscle uptake of ^{18}F -FDG.[3]
- **Radiotracer Administration:** An intravenous injection of 185-555 MBq (5-15 mCi) of ^{18}F -FDG is administered.
- **Uptake Phase:** Following injection, the patient rests in a quiet, comfortable room for approximately 60 minutes to allow for tracer distribution and uptake.[18]
- **Image Acquisition:** A whole-body PET/CT scan, typically from the base of the skull to the mid-thigh, is acquired.
- **Image Analysis:** Images are assessed visually for areas of abnormally high ^{18}F -FDG uptake. Semiquantitative analysis is routinely performed using the Standardized Uptake Value

(SUV), which normalizes the tracer concentration in a region of interest to the injected dose and patient body weight.

Conclusion: A Complementary Role in Oncological Imaging

^{99m}Tc -Sestamibi SPECT and ^{18}F -FDG PET offer distinct and often complementary information in the evaluation of cancer. While ^{18}F -FDG PET excels in visualizing the heightened glucose metabolism characteristic of many aggressive tumors, ^{99m}Tc -Sestamibi provides valuable insights into tumor perfusion and mitochondrial function. The choice between these modalities, or their combined use, depends on the specific clinical question, tumor type, and the biological characteristics of the malignancy being investigated. For drug development professionals, understanding the nuances of these imaging techniques can aid in the non-invasive assessment of therapeutic efficacy and the elucidation of drug mechanisms of action. As our understanding of tumor biology deepens, the strategic application of these powerful imaging tools will continue to refine cancer diagnosis, treatment, and monitoring.

Need Custom Synthesis?

BenchChem offers custom synthesis for rare earth carbides and specific isotopic labeling.

Email: info@benchchem.com or [Request Quote Online](#).

References

- 1. Summary of the UPICT Protocol for ^{18}F -FDG PET/CT Imaging in Oncology Clinical Trials - PMC [pmc.ncbi.nlm.nih.gov]
- 2. jnm.snmjournals.org [jnm.snmjournals.org]
- 3. jnm.snmjournals.org [jnm.snmjournals.org]
- 4. Applications of ^{99m}Tc -sestamibi in oncology - PubMed [pubmed.ncbi.nlm.nih.gov]
- 5. Differential Findings of Tc- 99m Sestamibi Dual-Phase Parathyroid Scintigraphy Between Benign and Malignant Parathyroid Lesions in Patients with Primary Hyperparathyroidism - PMC [pmc.ncbi.nlm.nih.gov]
- 6. radiopaedia.org [radiopaedia.org]

- 7. A Prospective Study Comparing the Role of 18 FDG PET-CT with Contrast-Enhanced Computed Tomography and Tc99m Bone Scan for Staging Locally Advanced Breast Cancer - PMC [pmc.ncbi.nlm.nih.gov]
- 8. Comparison of F-18 FDG-PET/CT and Tc-99m MIBI in the preoperative evaluation of cold thyroid nodules in the same patient group - PubMed [pubmed.ncbi.nlm.nih.gov]
- 9. Role of 18F-FDG-PET and PET/CT imaging in thyroid cancer - PubMed [pubmed.ncbi.nlm.nih.gov]
- 10. 99mTc-sestamibi SPECT/CT and 18F-FDG-PET/CT have similar performance but different imaging patterns in newly diagnosed multiple myeloma - PubMed [pubmed.ncbi.nlm.nih.gov]
- 11. researchgate.net [researchgate.net]
- 12. 99mTc-sestamibi SPECT/CT and 18F-FDG-PET/CT have similar performance but different imaging patterns in newly diagnosed multiple myeloma - PMC [pmc.ncbi.nlm.nih.gov]
- 13. Comparison of Tc-99m sestamibi and F-18 FDG-PET in the assessment of multiple myeloma - PubMed [pubmed.ncbi.nlm.nih.gov]
- 14. Accuracy of FDG-PET to diagnose lung cancer in areas with infectious lung disease: A meta-analysis - PMC [pmc.ncbi.nlm.nih.gov]
- 15. Comparing the diagnostic value of 18F-FDG-PET/CT versus CT for differentiating benign and malignant solitary pulmonary nodules: a meta-analysis - Jia - Journal of Thoracic Disease [jtd.amegroups.org]
- 16. Head-to-head comparison of 18F-FDG PET/CT and 18F-FDG PET/MRI for lymph node metastasis staging in non-small cell lung cancer: a meta-analysis - PMC [pmc.ncbi.nlm.nih.gov]
- 17. Efficacy comparison between (18)F-FDG PET/CT and bone scintigraphy in detecting bony metastases of non-small-cell lung cancer - PubMed [pubmed.ncbi.nlm.nih.gov]
- 18. jnm.snmjournals.org [jnm.snmjournals.org]
- To cite this document: BenchChem. [A Comparative Analysis of 99mTc-Sestamibi and 18F-FDG PET in Oncological Imaging]. BenchChem, [2025]. [Online PDF]. Available at: [https://www.benchchem.com/product/b1243785#comparative-study-of-99mtc-sestamibi-and-18f-fdg-pet-in-oncology]

Disclaimer & Data Validity:

The information provided in this document is for Research Use Only (RUO) and is strictly not intended for diagnostic or therapeutic procedures. While BenchChem strives to provide accurate protocols, we make no warranties, express or implied, regarding the fitness of this product for every specific experimental setup.

Technical Support: The protocols provided are for reference purposes. Unsure if this reagent suits your experiment? [[Contact our Ph.D. Support Team for a compatibility check](#)]

Need Industrial/Bulk Grade? [Request Custom Synthesis Quote](#)

BenchChem

Our mission is to be the trusted global source of essential and advanced chemicals, empowering scientists and researchers to drive progress in science and industry.

Contact

Address: 3281 E Guasti Rd

Ontario, CA 91761, United States

Phone: (601) 213-4426

Email: info@benchchem.com