

# A Comparative Analysis of [18F]-FDOPA and [18F]-FDG PET in Glioma Imaging

**Author:** BenchChem Technical Support Team. **Date:** December 2025

## Compound of Interest

Compound Name: [18F]-Labeled L-dopa precursor

Cat. No.: B12430852

[Get Quote](#)

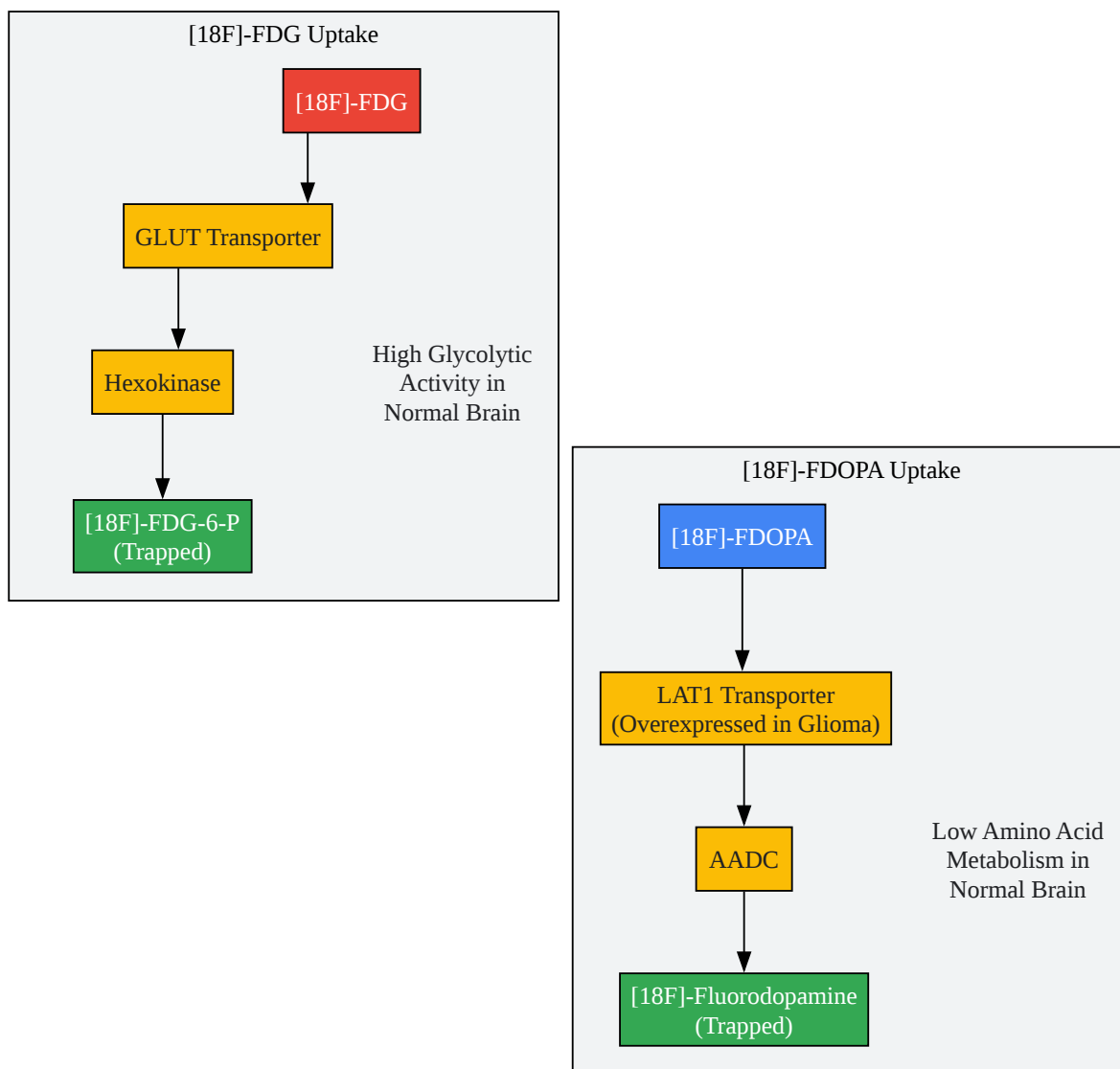
For Researchers, Scientists, and Drug Development Professionals

The accurate diagnosis, grading, and monitoring of gliomas, the most common primary malignant brain tumors, are critical for effective patient management.<sup>[1][2]</sup> Positron Emission Tomography (PET) offers valuable metabolic insights that complement anatomical imaging provided by MRI. This guide provides a comparative analysis of two prominent PET radiotracers, [18F]-FDOPA (3,4-dihydroxy-6-[18F]-fluoro-L-phenylalanine) and [18F]-FDG (18F-fluorodeoxyglucose), in the context of glioma imaging.

## Principle of Uptake: A Tale of Two Metabolic Pathways

The fundamental difference between [18F]-FDOPA and [18F]-FDG lies in the metabolic pathways they trace. [18F]-FDG, a glucose analog, is taken up by cells with high glycolytic activity, a hallmark of many cancers. However, its utility in brain tumor imaging is hampered by the high physiological glucose uptake in the normal brain parenchyma, which can obscure the tumor signal.<sup>[3][4]</sup>

In contrast, [18F]-FDOPA is an amino acid analog transported into cells primarily by the L-type amino acid transporter 1 (LAT1), which is overexpressed in glioma cells.<sup>[5]</sup> This results in a higher tumor-to-background ratio, providing clearer delineation of tumor tissue against the relatively low amino acid metabolism of healthy brain tissue.<sup>[6][7]</sup>



[Click to download full resolution via product page](#)

Caption: Uptake mechanisms of [18F]-FDG and [18F]-FDOPA in brain cells.

## Performance in Glioma Diagnosis and Grading

Clinical data consistently demonstrates the superior performance of [18F]-FDOPA PET in the diagnosis and grading of gliomas compared to [18F]-FDG PET.

### Diagnostic Accuracy

A meta-analysis of 13 studies involving 370 patients showed that [18F]-FDOPA PET has a high sensitivity for diagnosing gliomas.[1][3] In direct comparisons, [18F]-FDOPA PET was significantly more sensitive in identifying tumors overall than [18F]-FDG PET.[6] This is particularly evident in low-grade gliomas, which may not exhibit the high glucose metabolism readily detected by [18F]-FDG.[6]

Parameter	[18F]-FDOPA PET	[18F]-FDG PET	Reference
Sensitivity (Glioma Diagnosis)	90% (95% CI: 86-93%)	61% (95% CI: 41-81%)	[1][6]
Specificity (Glioma Diagnosis)	75% (95% CI: 65-83%)	43%	[1][6]
Overall Accuracy (Glioma Diagnosis)	83% (95% CI: 70-97%)	57% (95% CI: 39-74%)	[6]

Table 1: Comparative Diagnostic Accuracy of [18F]-FDOPA and [18F]-FDG PET for Glioma Detection.

### Tumor Grading

[18F]-FDOPA PET also demonstrates good performance in differentiating high-grade gliomas (HGGs) from low-grade gliomas (LGGs).[1] A meta-analysis reported a pooled sensitivity of 88% and a specificity of 73% for this application.[1][3] While [18F]-FDG uptake can correlate with tumor grade, its utility is often limited by the aforementioned high background signal.[4] Studies have shown a significant correlation between the tumor-to-normal tissue (T/N) SUVmax ratio of [18F]-FDOPA and the WHO grade of the glioma.[7]

Parameter	[18F]-FDOPA PET	Reference
Sensitivity (High-Grade vs. Low-Grade)	88% (95% CI: 81-93%)	[1][3]
Specificity (High-Grade vs. Low-Grade)	73% (95% CI: 64-81%)	[1][3]

Table 2: Diagnostic Performance of [18F]-FDOPA PET for Glioma Grading.

## Differentiating Tumor Recurrence from Treatment-Related Changes

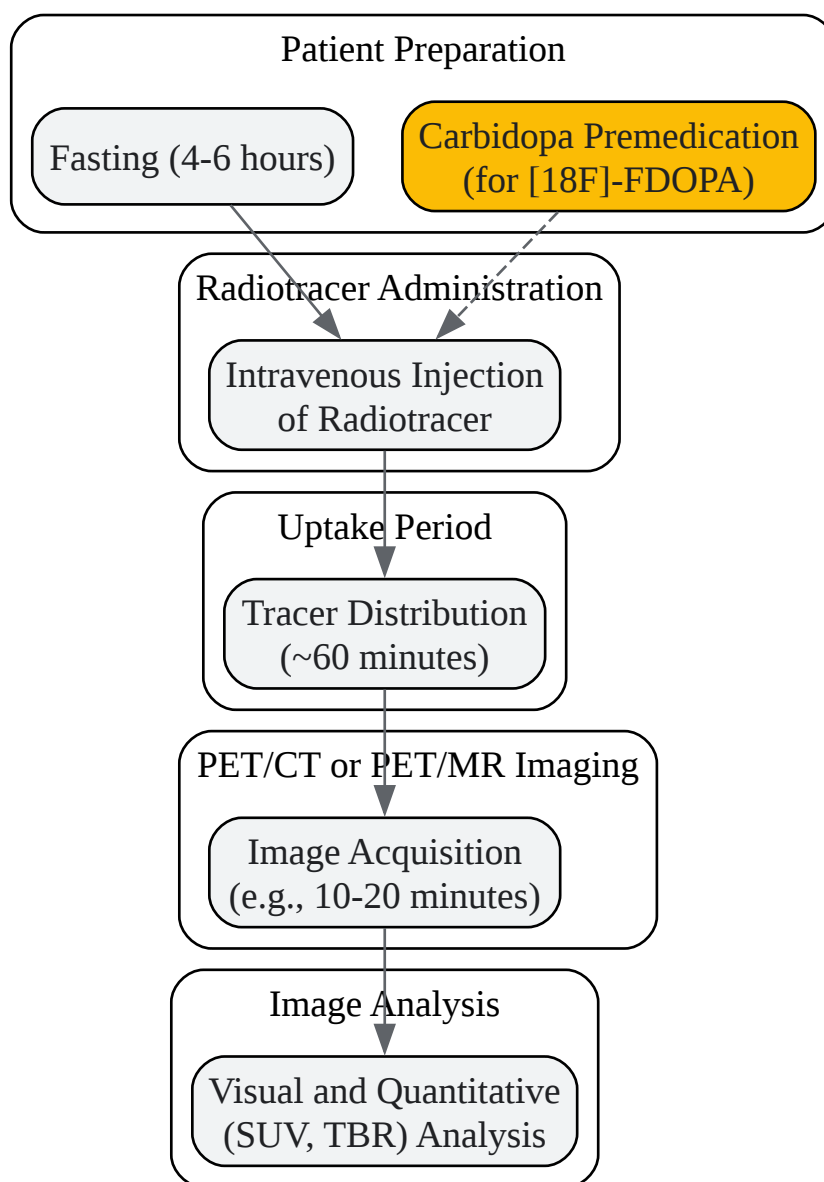
A significant challenge in post-treatment glioma management is distinguishing true tumor recurrence from treatment-related effects such as radiation necrosis. [18F]-FDOPA PET has shown considerable promise in this area, outperforming [18F]-FDG PET.[6] The high contrast of [18F]-FDOPA allows for clearer visualization of recurrent tumor tissue.[6] In one study, [18F]-FDOPA PET demonstrated a sensitivity of 96% and a specificity of 43% in identifying tumors, which was superior to [18F]-FDG PET's sensitivity of 61% and specificity of 43%.[6] For differentiating tumor recurrence from radiation necrosis, [18F]-FDOPA PET has reported sensitivity ranging from 81% to 96% and specificity from 77% to 100%.[8]

## Prognostic Value

The intensity of [18F]-FDOPA uptake has been shown to have prognostic implications. Higher uptake, quantified by metrics like the maximum standardized uptake value (SUVmax) and tumor-to-normal brain tissue ratio (TBR), is associated with shorter progression-free survival (PFS) and overall survival (OS).[8] For patients with previously treated low-grade gliomas, [18F]-FDOPA uptake equal to or greater than the striatum was predictive of a shorter time to progression.[9]

## Experimental Protocols

Standardized protocols are crucial for ensuring the reliability and comparability of PET imaging results. Below is a generalized workflow and key parameters for [18F]-FDOPA and [18F]-FDG PET imaging in glioma patients.



[Click to download full resolution via product page](#)

Caption: Generalized workflow for PET imaging in glioma patients.

## Patient Preparation

- [18F]-FDG: Patients are typically required to fast for at least 4-6 hours to ensure low plasma glucose and insulin levels, which can compete with [18F]-FDG uptake.
- [18F]-FDOPA: A fasting period of 4-6 hours is also recommended to minimize competition from dietary amino acids.[8] Premedication with carbidopa is often administered to inhibit

peripheral decarboxylation of [18F]-FDOPA to [18F]-fluorodopamine, thereby increasing its bioavailability in the brain.

## Radiotracer Injection and Uptake

- [18F]-FDG: The typical injected dose is 185–370 MBq (5–10 mCi), administered intravenously. An uptake period of approximately 60 minutes is allowed before imaging.
- [18F]-FDOPA: A similar dose of 185–370 MBq (5–10 mCi) is injected intravenously. The recommended uptake period is also around 60 minutes to achieve optimal contrast between the tumor and normal brain tissue.[8]

## Image Acquisition

- Both static and dynamic imaging protocols can be employed. Static imaging, typically acquired over 10-20 minutes, is common in clinical practice. Dynamic imaging, which involves acquiring data over a longer period (e.g., 60 minutes), can provide additional kinetic information that may aid in tumor grading.[5]

## Conclusion

[18F]-FDOPA PET has emerged as a superior imaging modality compared to [18F]-FDG PET for the diagnosis, grading, and management of gliomas. Its high tumor-to-background ratio allows for more accurate tumor delineation, especially in low-grade gliomas, and it is more effective in distinguishing tumor recurrence from treatment-related changes.[3][6] While [18F]-FDG remains a valuable tool in general oncology, its utility in neuro-oncology is limited by the high metabolic activity of the normal brain.[3] The quantitative parameters derived from [18F]-FDOPA PET also provide valuable prognostic information, aiding in personalized treatment strategies for glioma patients. Future research should continue to standardize imaging protocols and explore the full potential of dynamic [18F]-FDOPA PET in characterizing the complex biology of gliomas.

### Need Custom Synthesis?

BenchChem offers custom synthesis for rare earth carbides and specific isotopic labeling.

Email: [info@benchchem.com](mailto:info@benchchem.com) or [Request Quote Online](#).

## References

- 1. d-nb.info [d-nb.info]
- 2. Diagnostic and grading accuracy of 18F-FDOPA PET and PET/CT in patients with gliomas: a systematic review and meta-analysis | springermedizin.de [springermedizin.de]
- 3. Diagnostic and grading accuracy of 18F-FDOPA PET and PET/CT in patients with gliomas: a systematic review and meta-analysis - PMC [pmc.ncbi.nlm.nih.gov]
- 4. [18F]FDG PET-Based Radiomics and Machine Learning for the Assessment of Gliomas and Glioblastomas: A Systematic Review [mdpi.com]
- 5. Frontiers | Additive Value of Dynamic FDOPA PET/CT for Glioma Grading [frontiersin.org]
- 6. 18F-FDOPA PET Imaging of Brain Tumors: Comparison Study with 18F-FDG PET and Evaluation of Diagnostic Accuracy | Journal of Nuclear Medicine [jnm.snmjournals.org]
- 7. 18F-FDOPA PET and MRI characteristics correlate with degree of malignancy and predict survival in treatment-naïve gliomas: a cross-sectional study - PMC [pmc.ncbi.nlm.nih.gov]
- 8. mdpi.com [mdpi.com]
- 9. Prognostic value of 18F-FDOPA PET in patients with treated low-grade gliomas | Journal of Nuclear Medicine [jnm.snmjournals.org]
- To cite this document: BenchChem. [A Comparative Analysis of [18F]-FDOPA and [18F]-FDG PET in Glioma Imaging]. BenchChem, [2025]. [Online PDF]. Available at: [https://www.benchchem.com/product/b12430852#comparative-analysis-of-18f-fdopa-and-18f-fdg-pet-in-gliomas]

---

### Disclaimer & Data Validity:

The information provided in this document is for Research Use Only (RUO) and is strictly not intended for diagnostic or therapeutic procedures. While BenchChem strives to provide accurate protocols, we make no warranties, express or implied, regarding the fitness of this product for every specific experimental setup.

**Technical Support:** The protocols provided are for reference purposes. Unsure if this reagent suits your experiment? [[Contact our Ph.D. Support Team for a compatibility check](#)]

**Need Industrial/Bulk Grade?** [Request Custom Synthesis Quote](#)

# BenchChem

Our mission is to be the trusted global source of essential and advanced chemicals, empowering scientists and researchers to drive progress in science and industry.

## Contact

Address: 3281 E Guasti Rd

Ontario, CA 91761, United States

Phone: (601) 213-4426

Email: [info@benchchem.com](mailto:info@benchchem.com)